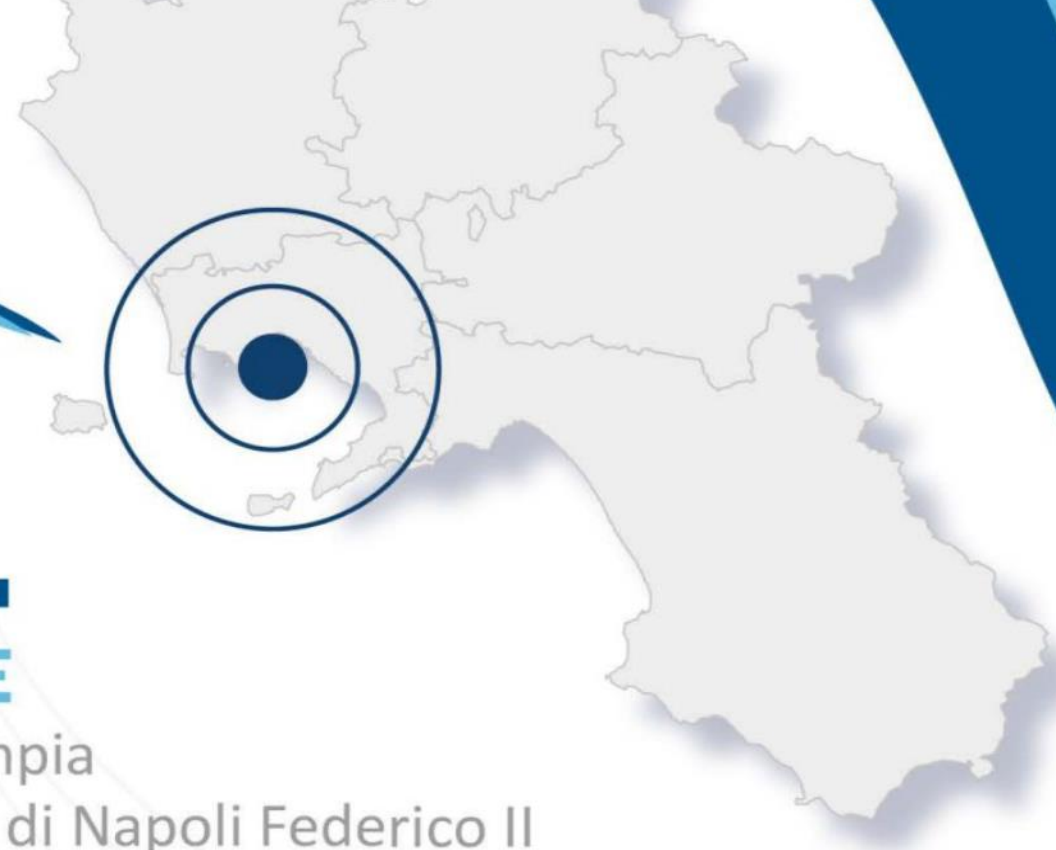

Napoli

SURGERY



NAPOLI 27 – 28 SETTEMBRE

Aula Magna Scuola di Medicina di Scampia

Centro Congressi Università degli Studi di Napoli Federico II

*Attività della U.O.S.D. di Chirurgia Maxillo-Facciale
Del P.O. del MARE*

CON IL PATROCINIO DI:



U.O.S.D. CHIRURGIA MAXILLO FACCIALE O.D.M.

RESPONSABILE : *DOTT. ENZO FACCIUTO*



DIRIGENTI MEDICI:

- ***Dr. CECERE ATIRGE***
- ***Dr. DELL'AQUILA ANTONIO***
- ***Dr. GIUFFRE' GIANLUCA***
- ***Dr. NUNZIATA ROSSELLA***
- ***Dr. RUGGIERO ANNAMARIA***

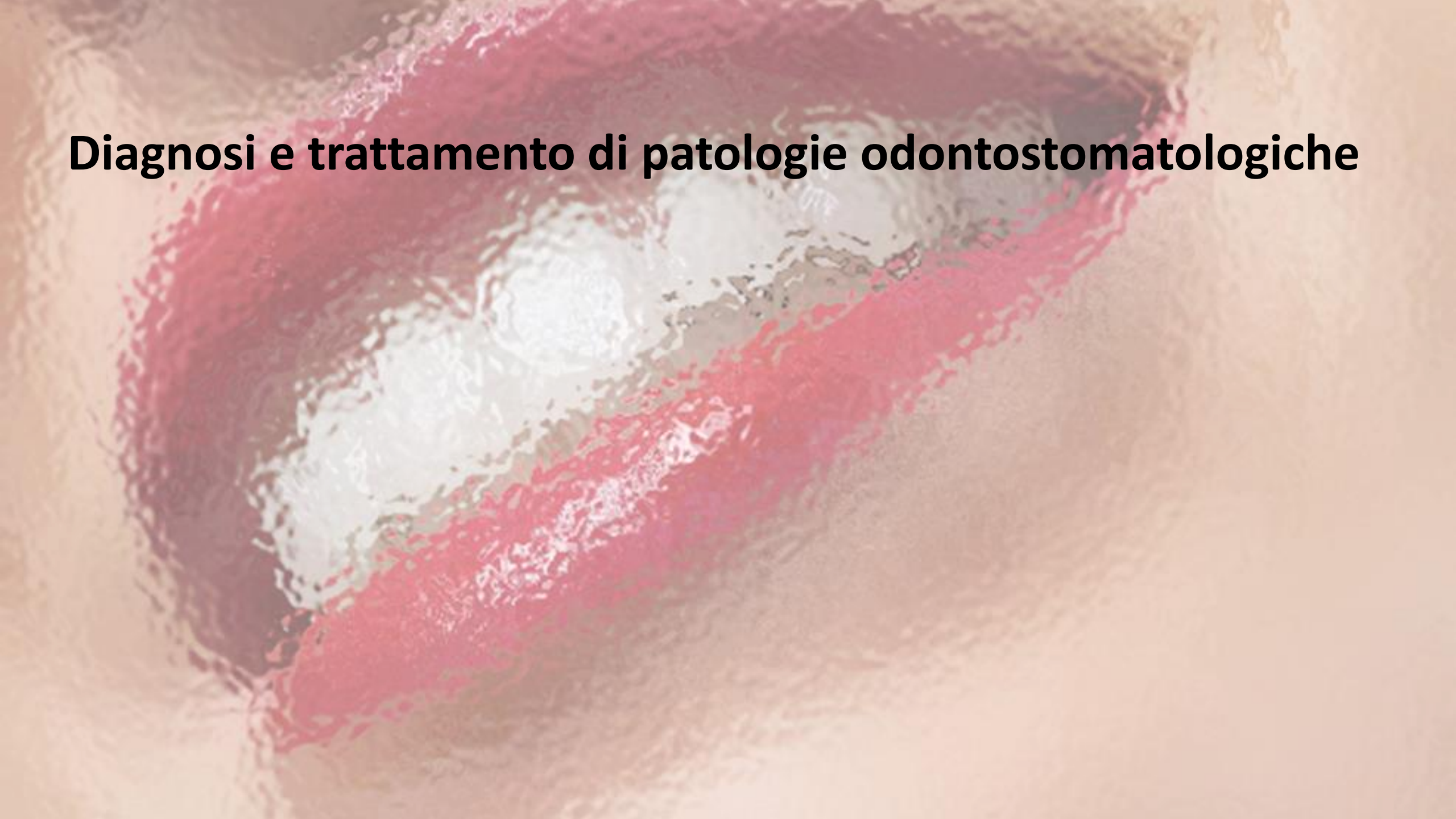

UOSD composta da
4 letti per ricovero ordinario

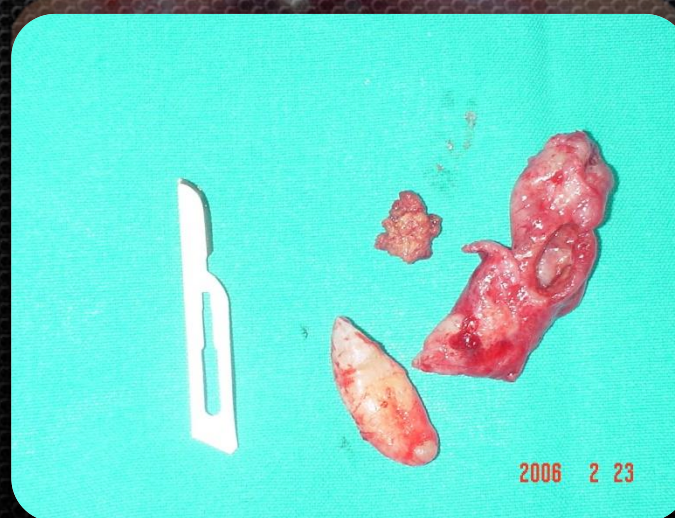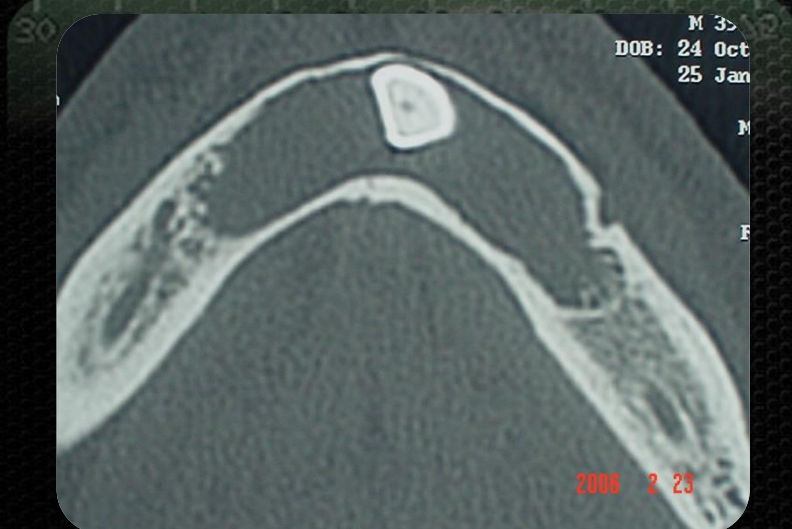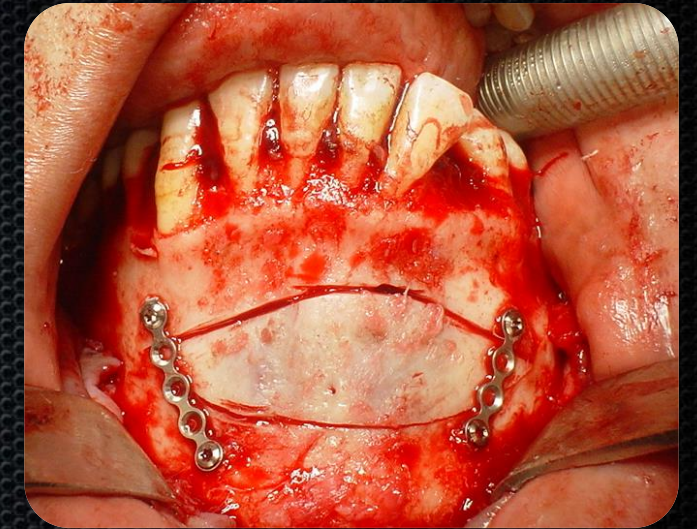
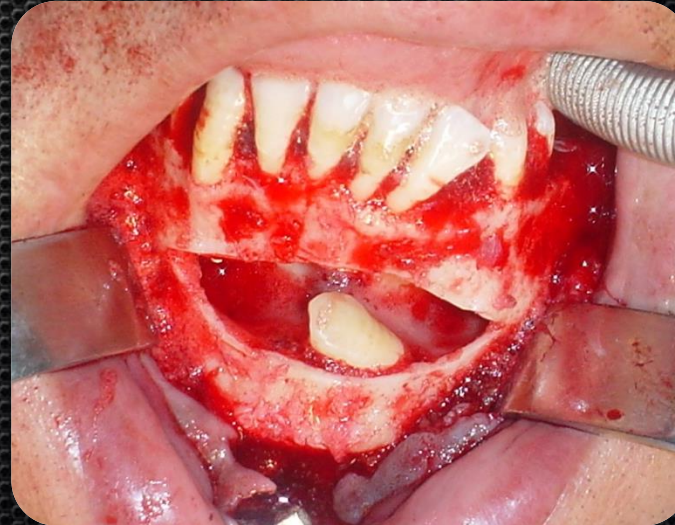
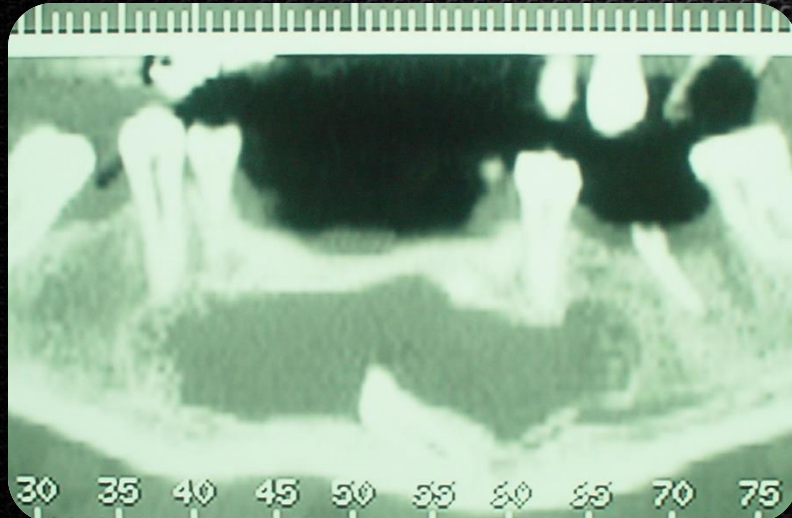
Attività operatoria 2020-2023

| | |
|--|------------|
| Diagnosi e trattamento di patologie odontostomatologiche | 64 |
| Ascessi e flemmoni del distretto maxillo-facciale | 31 |
| Patologie Benigne del distretto testa collo | 68 |
| Diagnosi e trattamento di patologie traumatiche maxillo-facciali | 240 |
| Diagnosi e trattamento di patologie benigne delle ghiandole salivari maggiori | 41 |
| Diagnosi e trattamento delle patologie dismorfiche maxillo-mandibolari | 12 |
| Diagnosi e trattamento di patologie tumorali maligne del distretto maxillo-facciale | 68 |
| TOTALE | 524 |

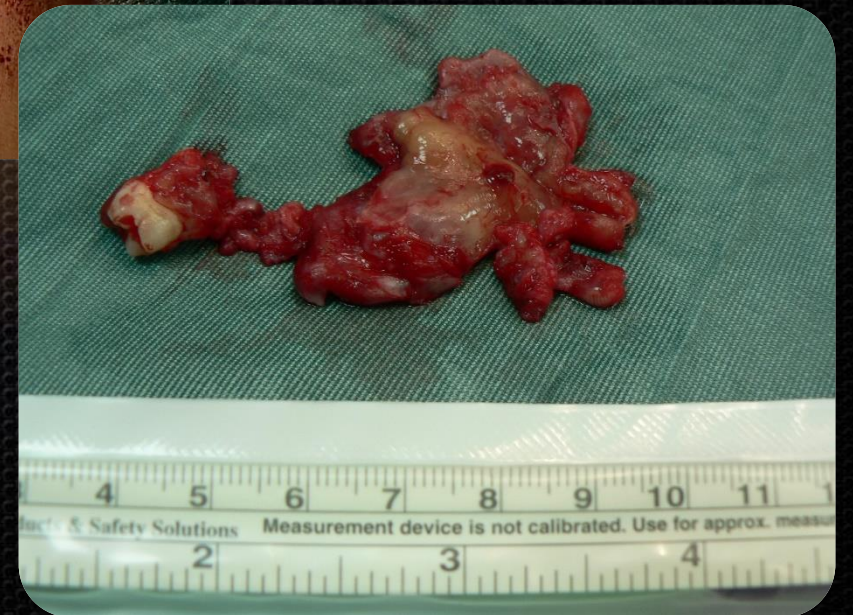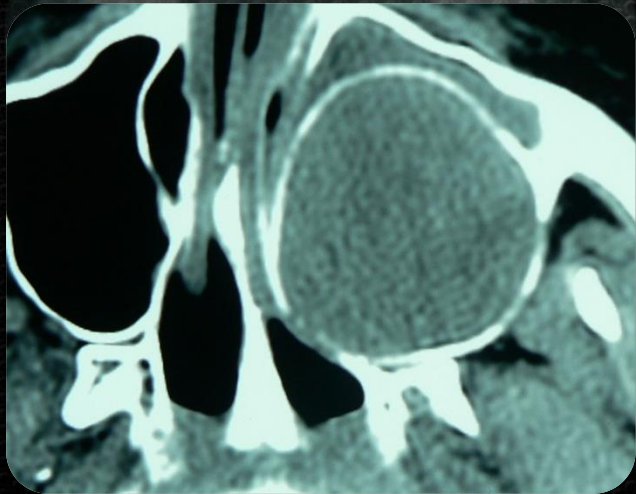
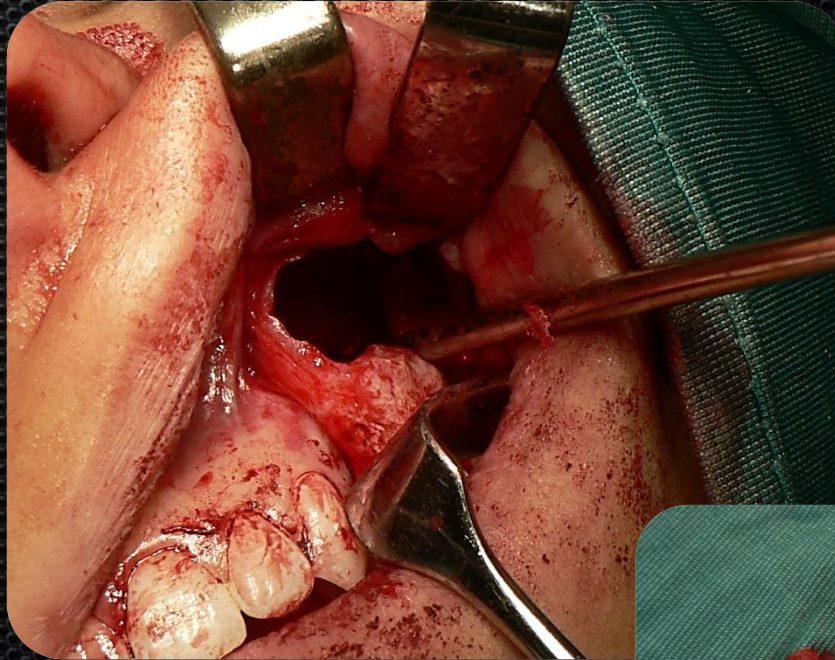
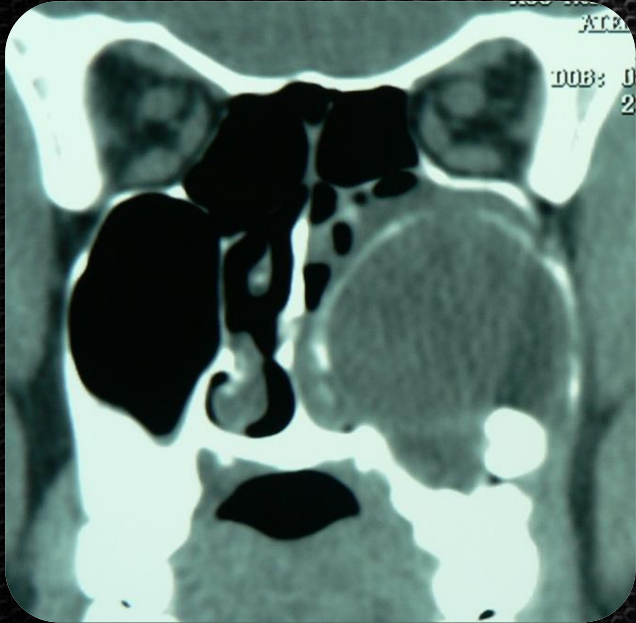Diagnosi e trattamento di patologie odontostomatologiche



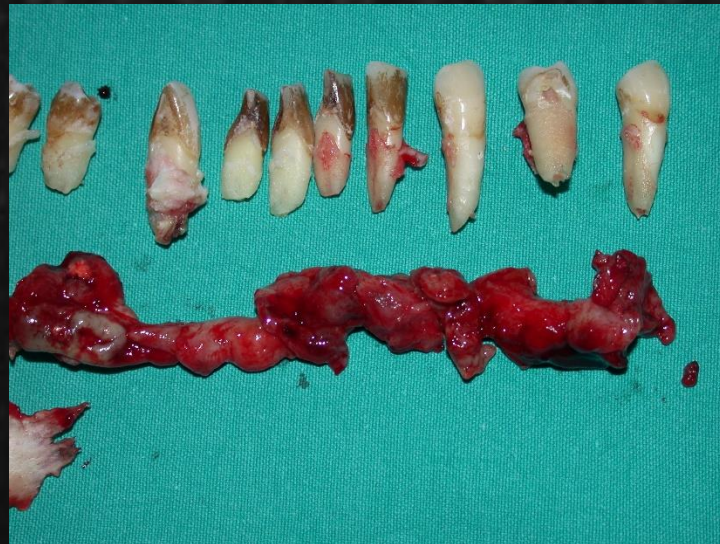
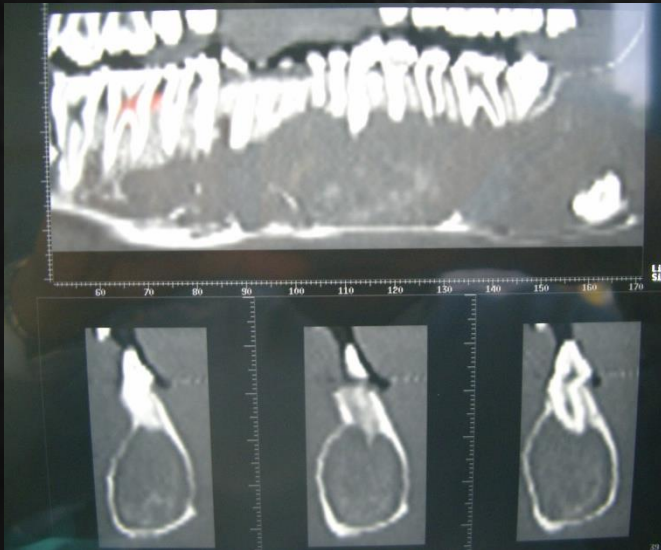
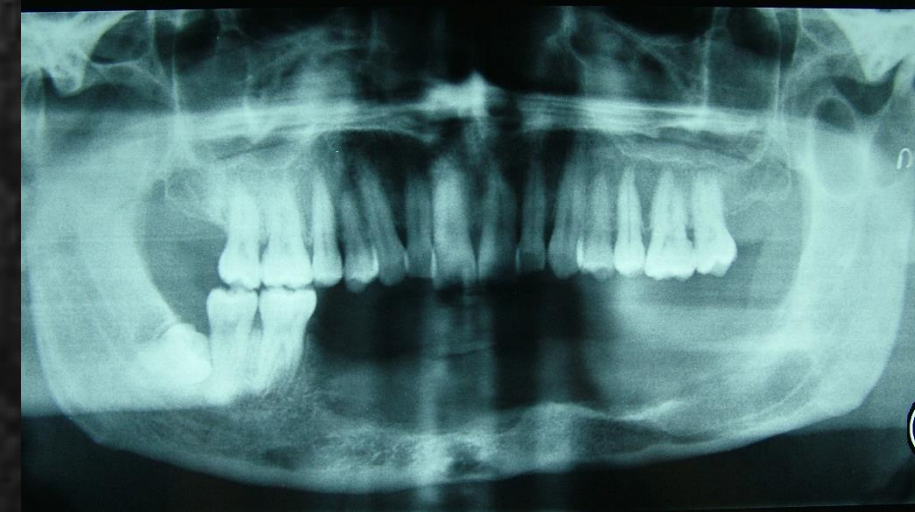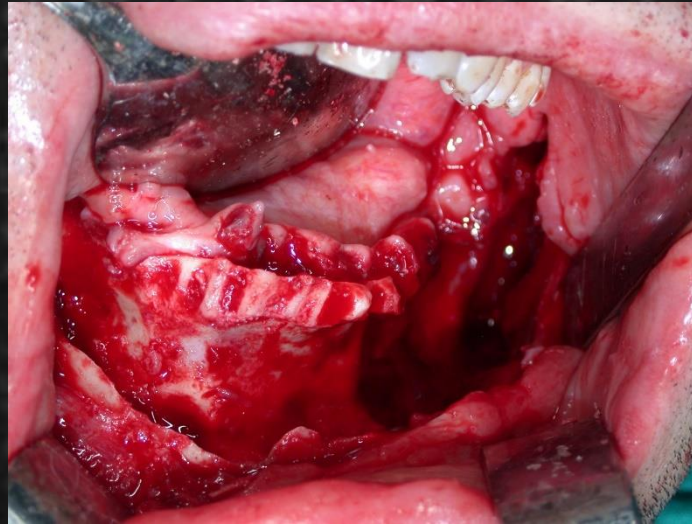
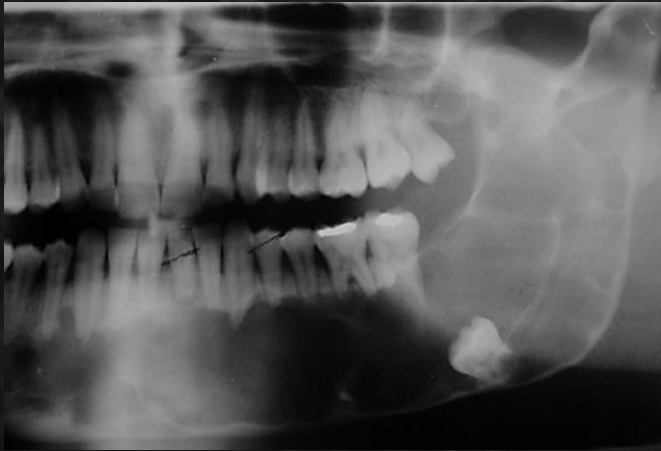CISTI MANDIBOLARE ODONTOGENA



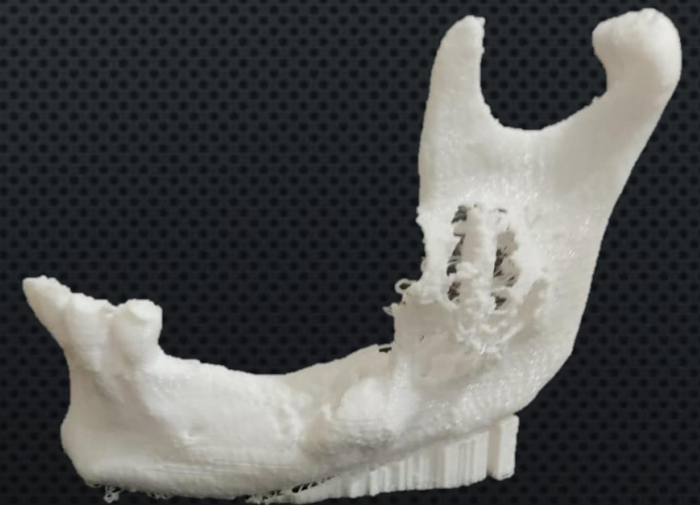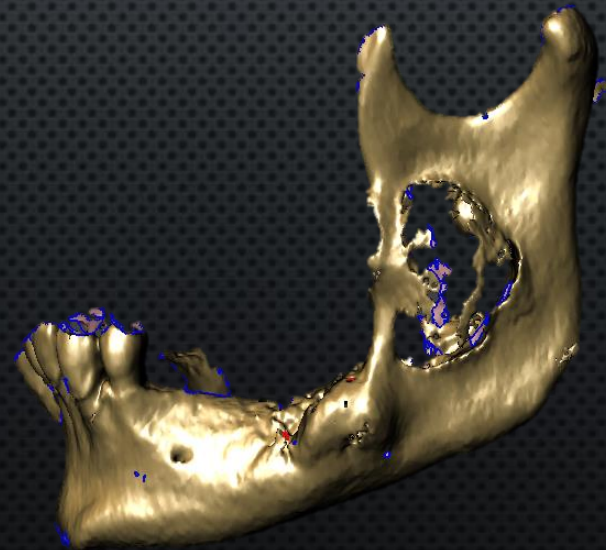
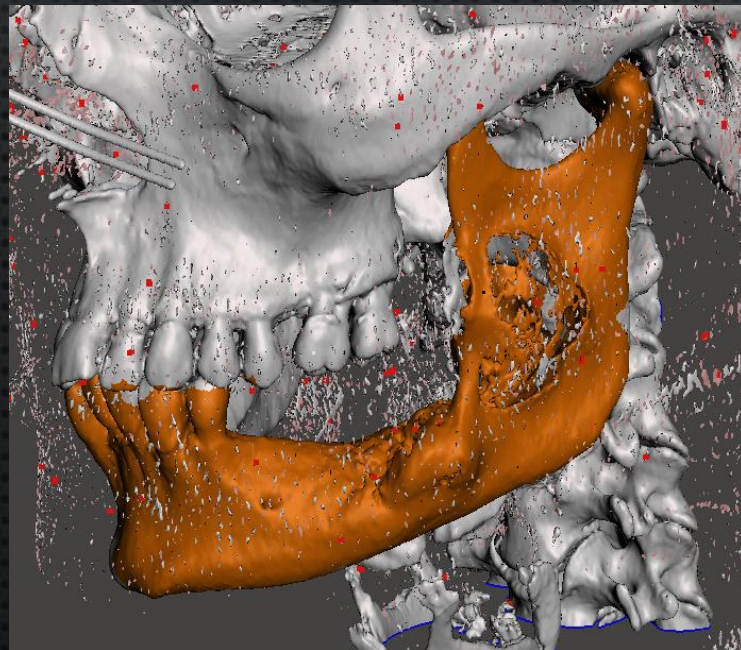
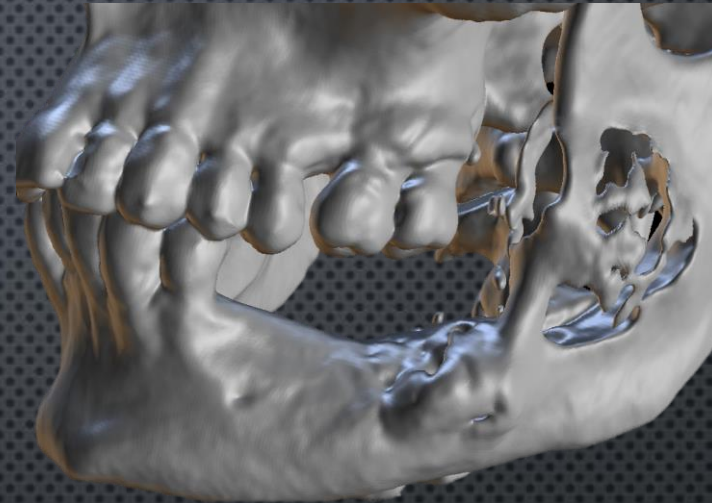
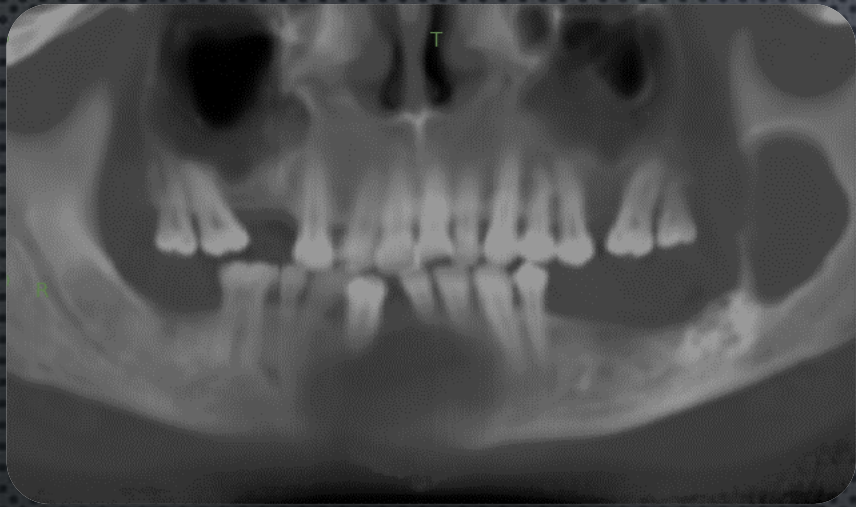
CISTI MASCELLARE ODONTOGENA

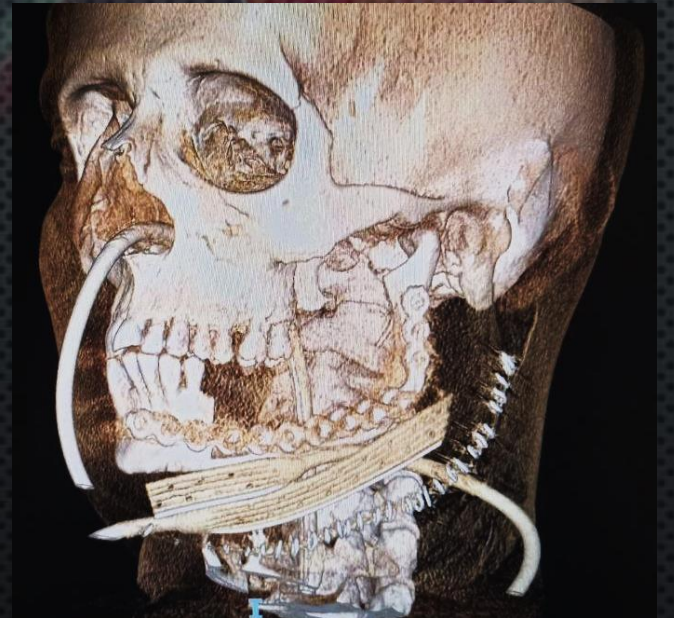
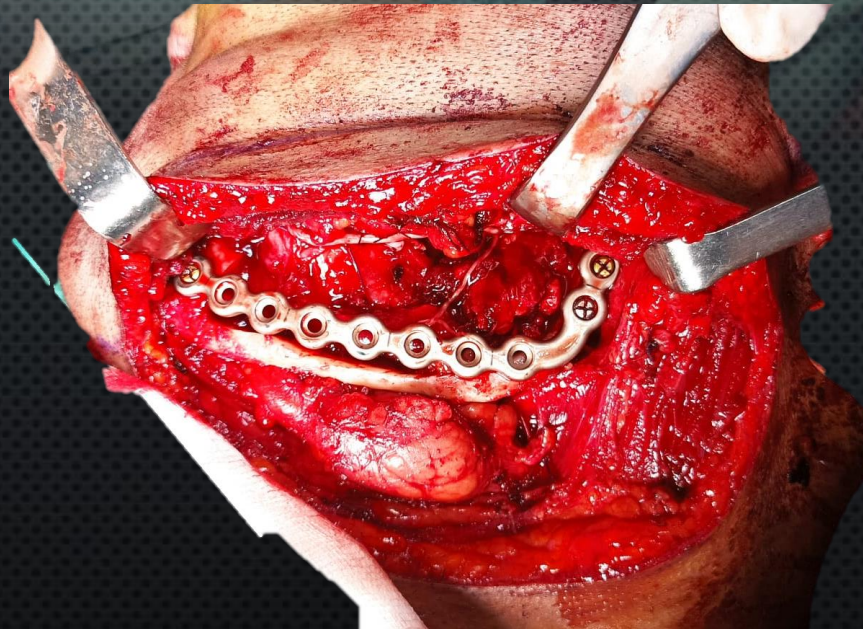
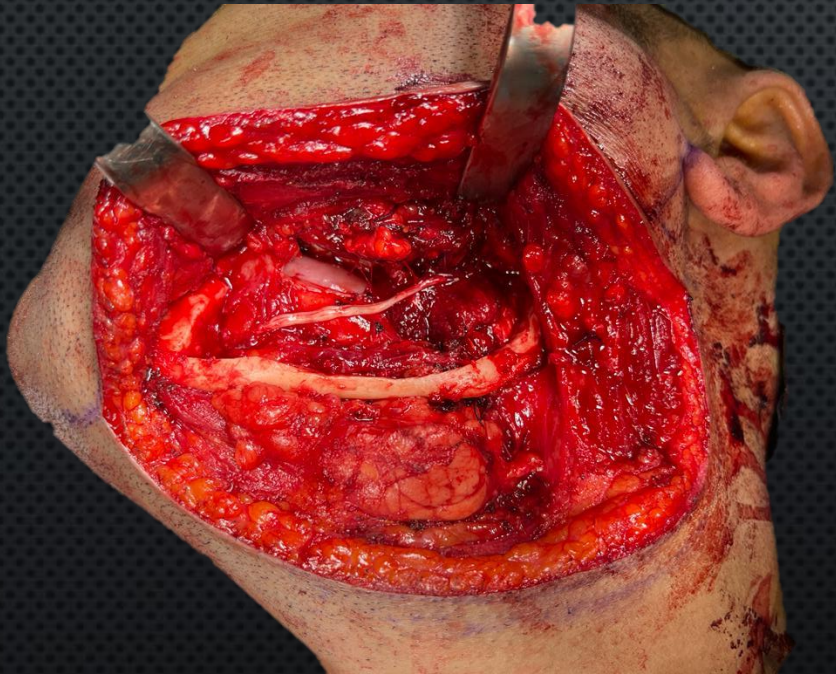
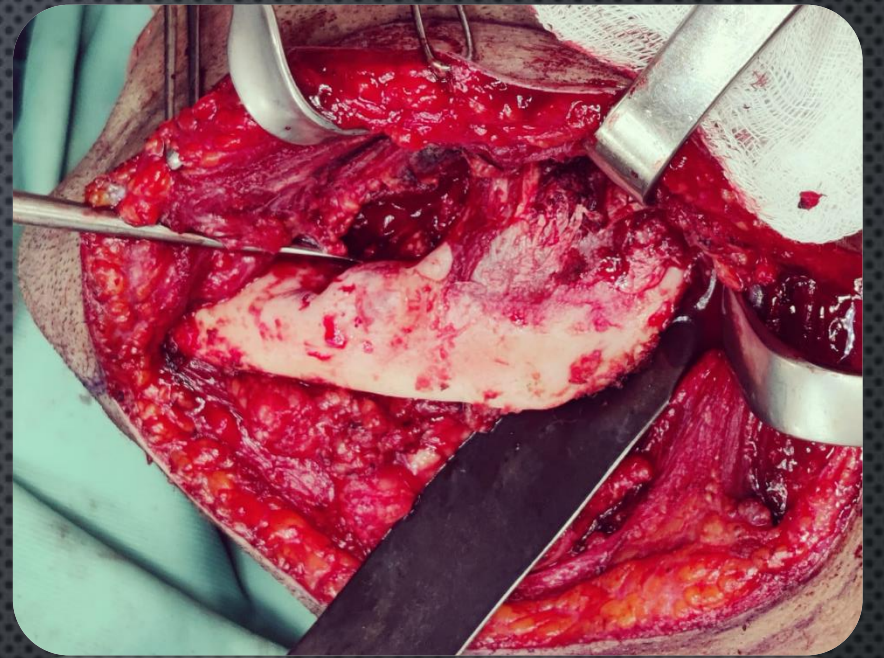
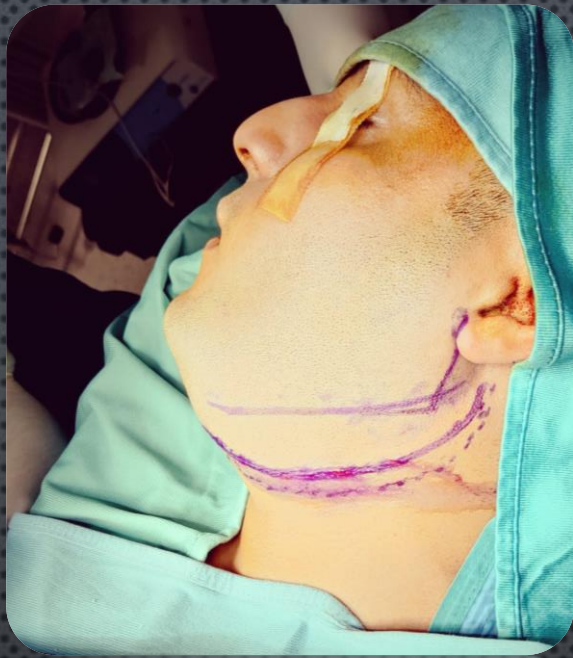
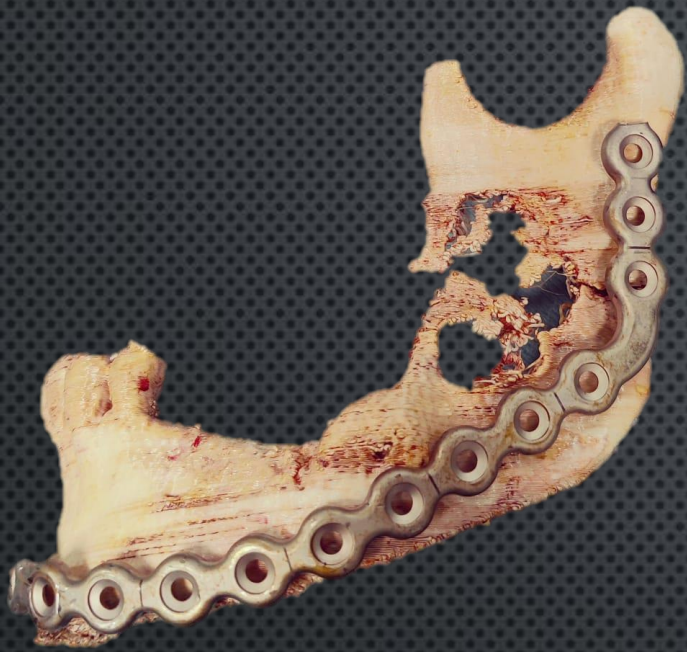
CHERATOCISTI ODONTOGENA



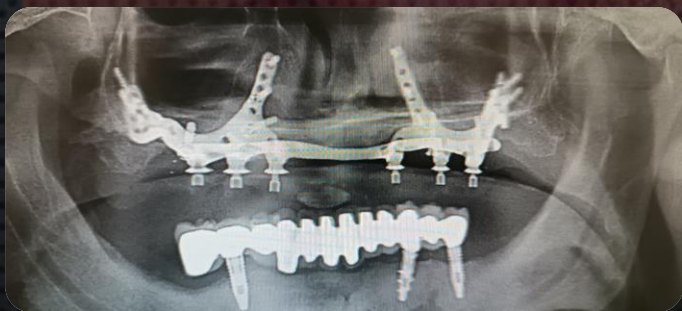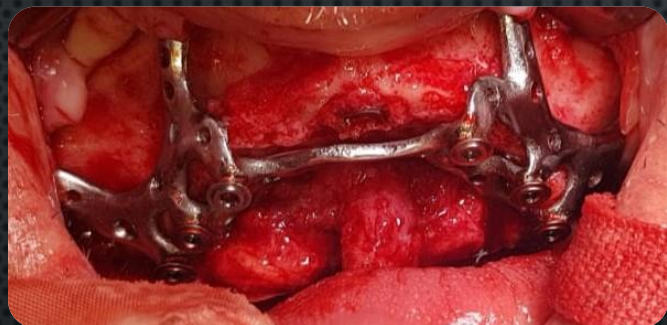
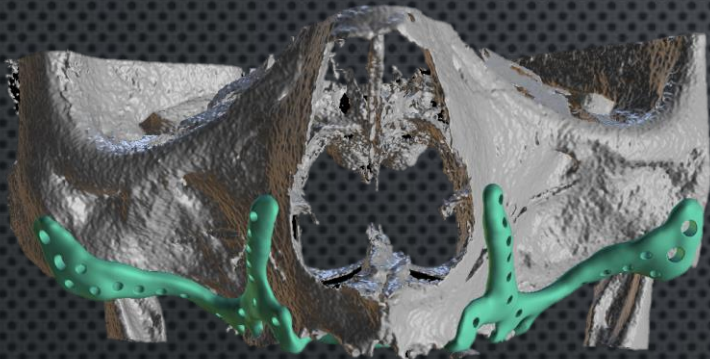
AMELOBLASTOMA MANDIBOLARE



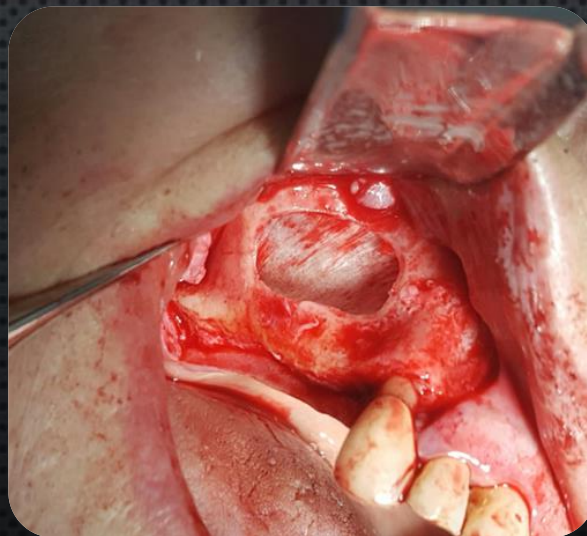
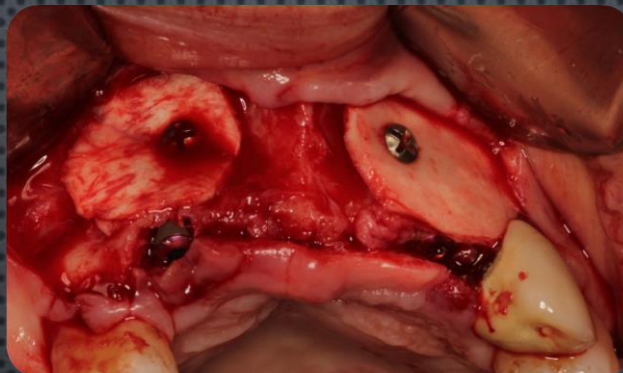


TRATTAMENTO GRAVI ATROFIE DEI MASCELLARI

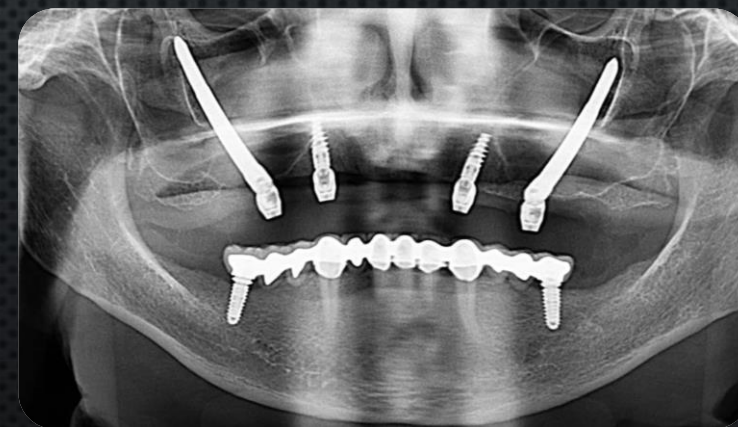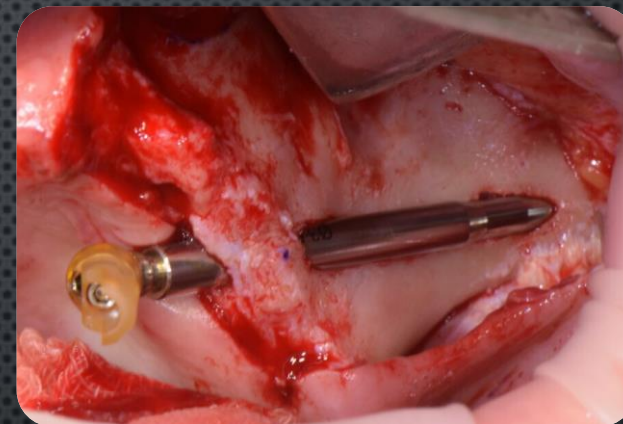
Griglia sottoperiosteale



Rigenerativa ossea



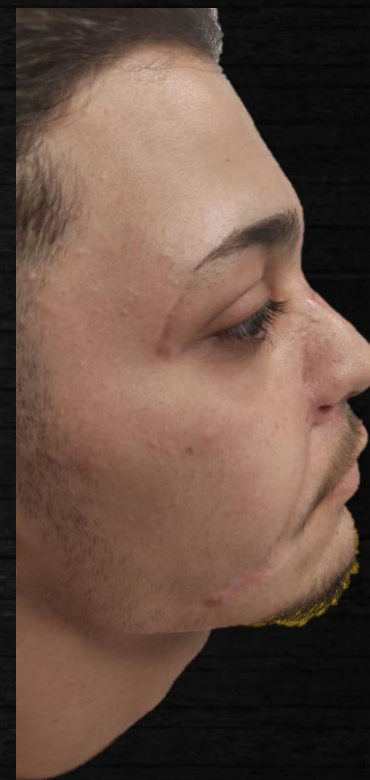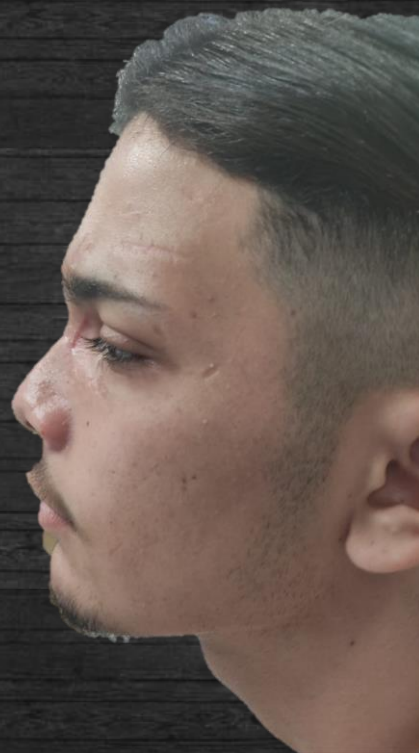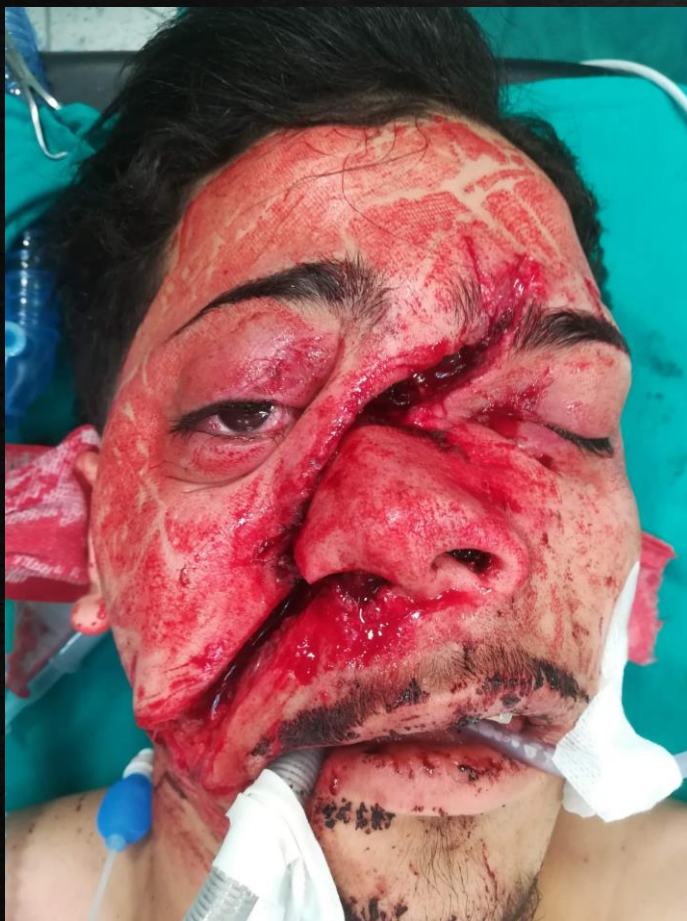Impianti Zigomatici



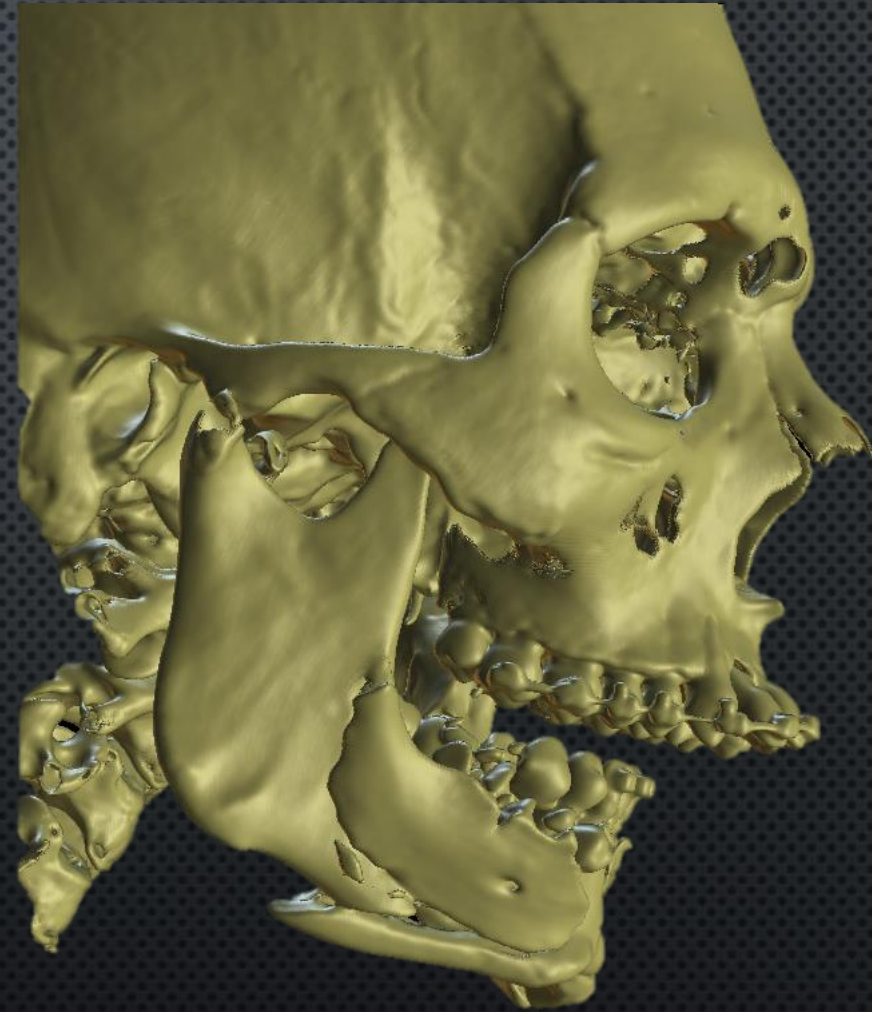
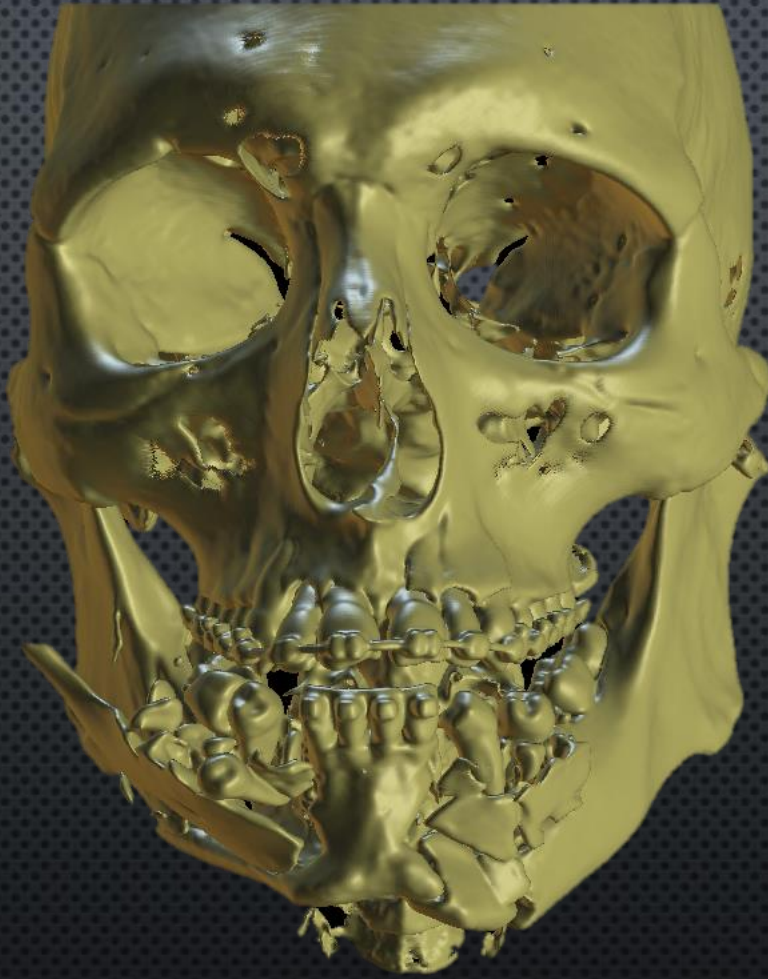
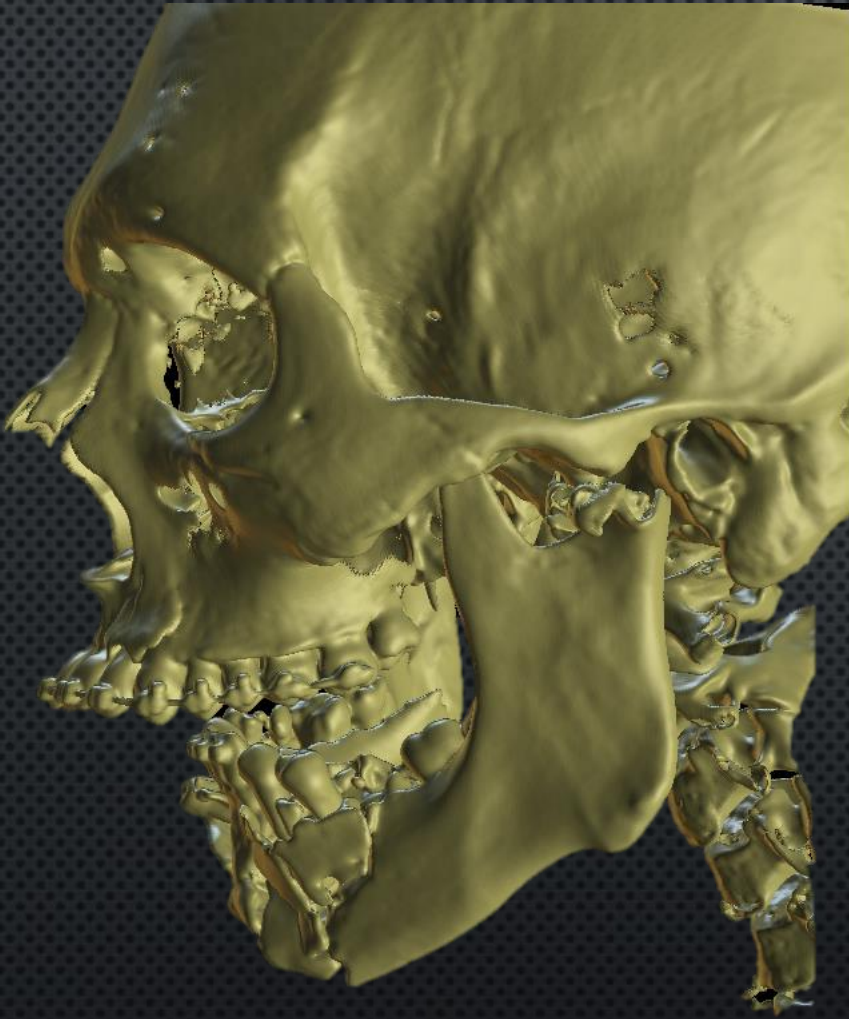
Diagnosi e trattamento di patologie traumatiche

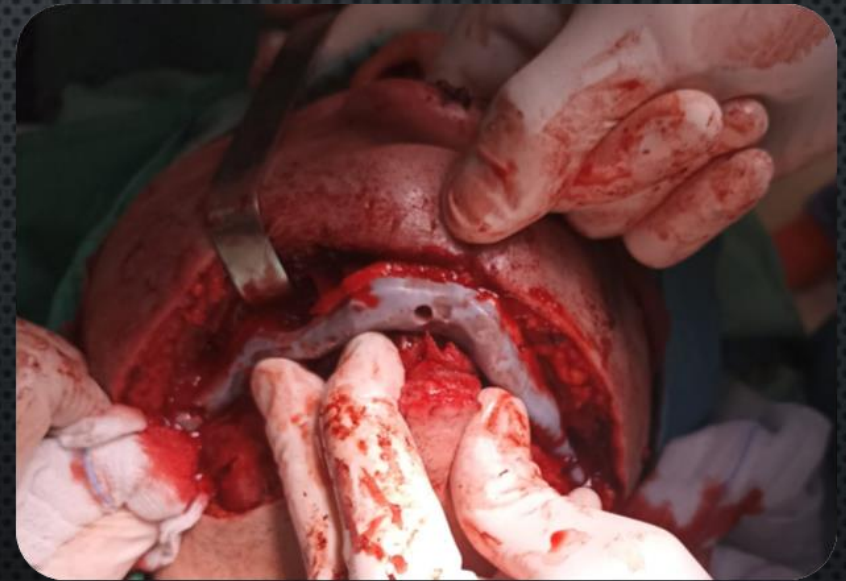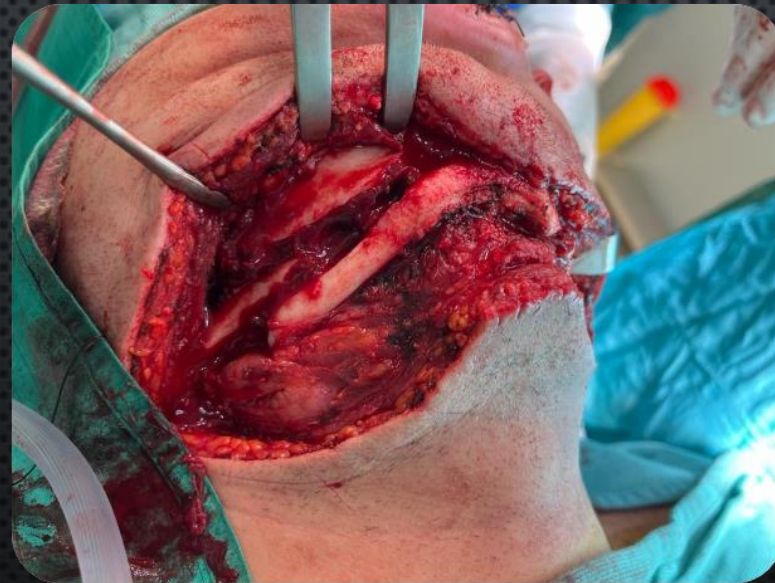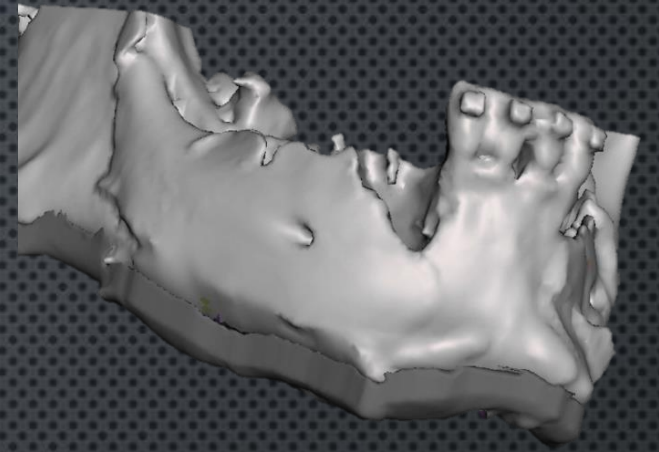
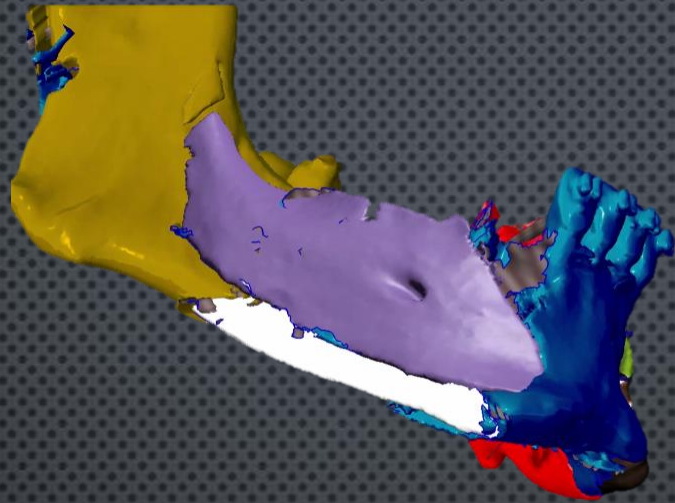
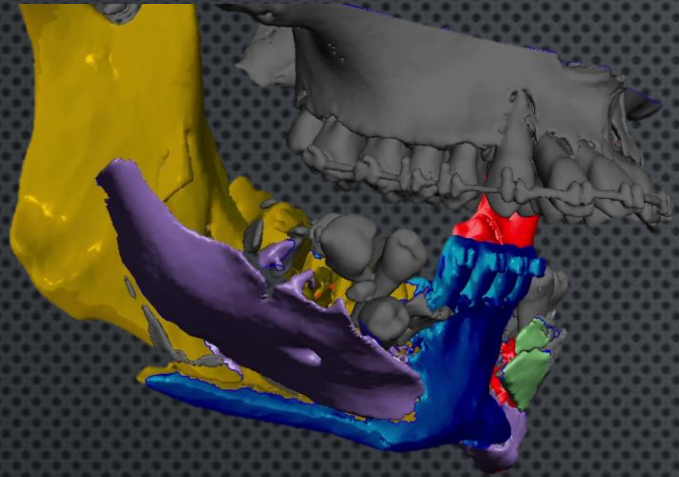


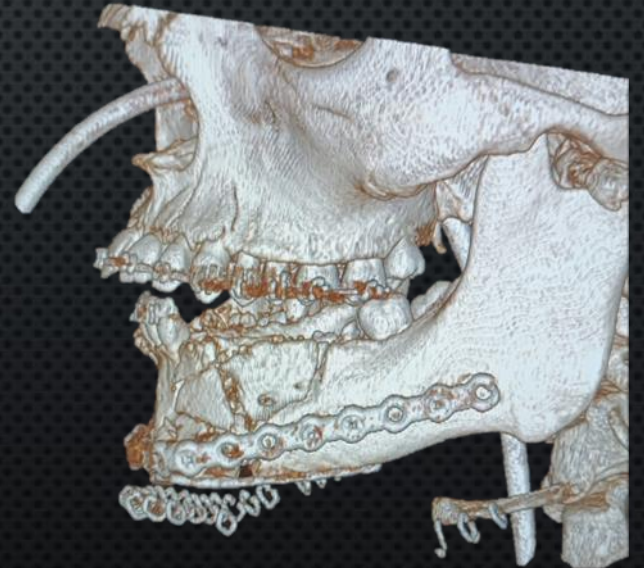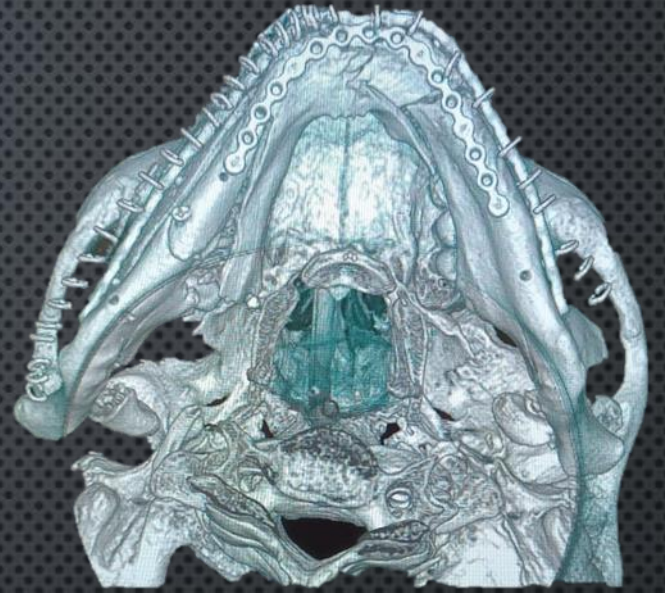
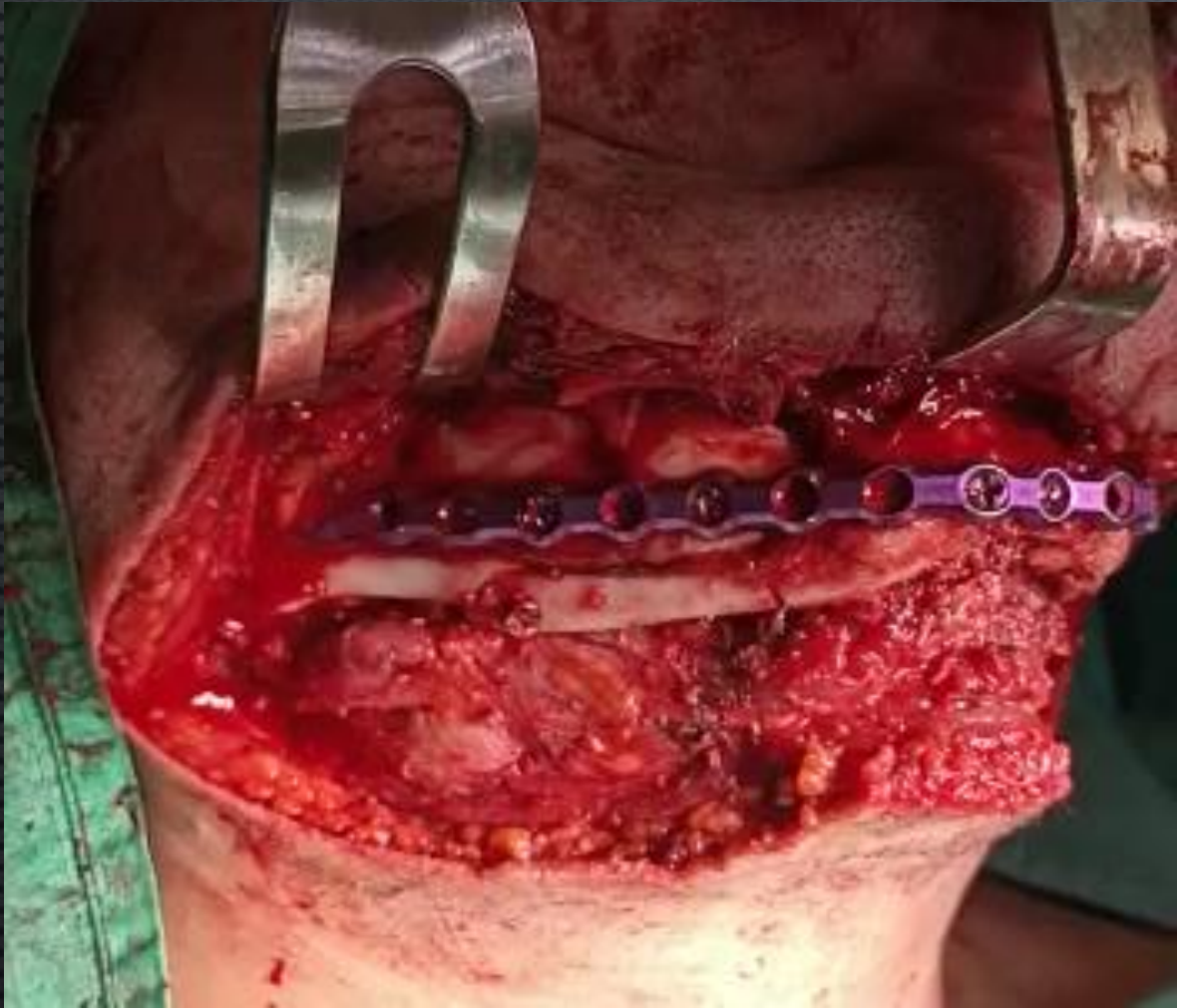TRAUMI DEI TESSUTI MOLLI



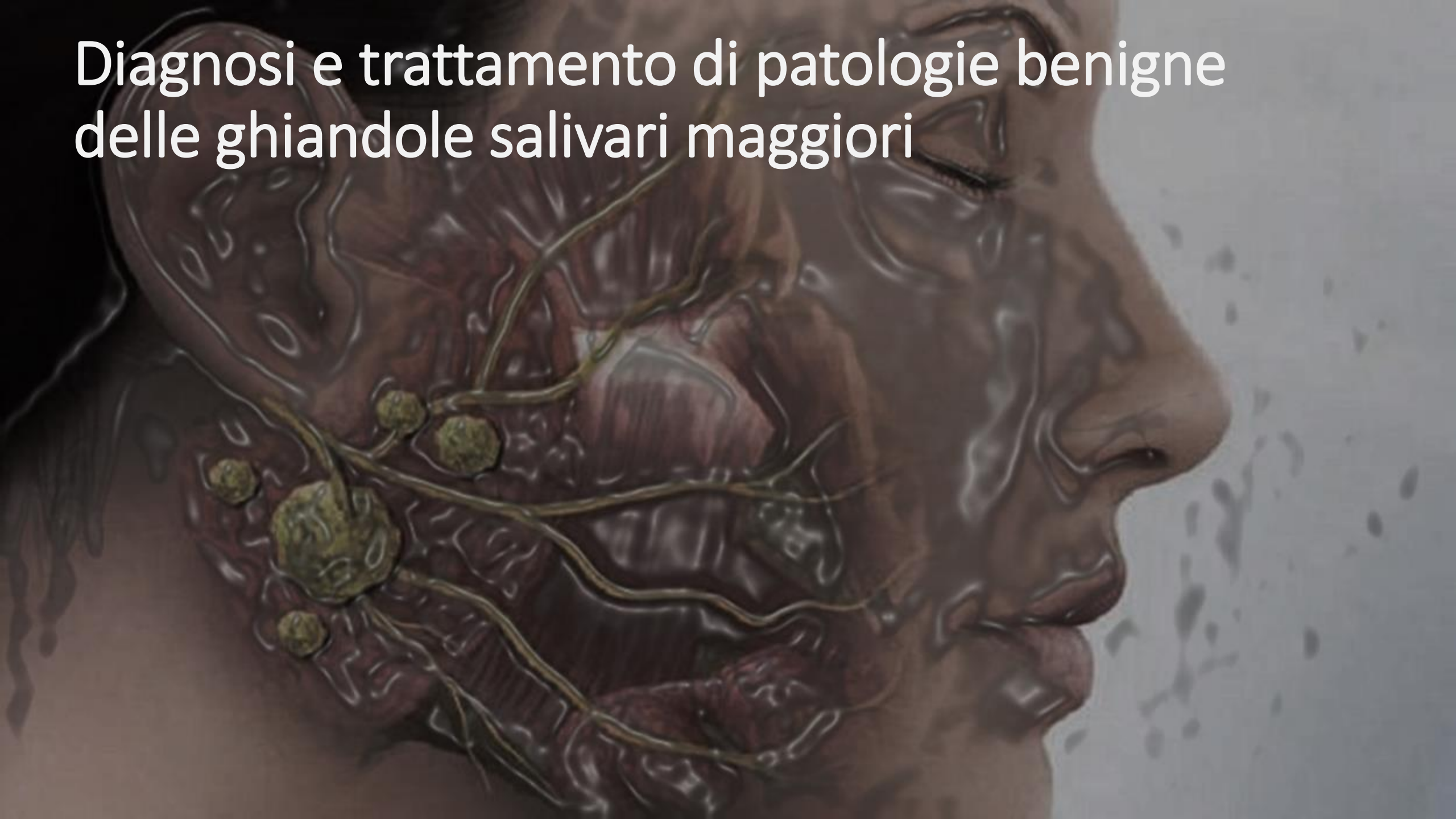
TRAUMI DEI TESSUTI DURI



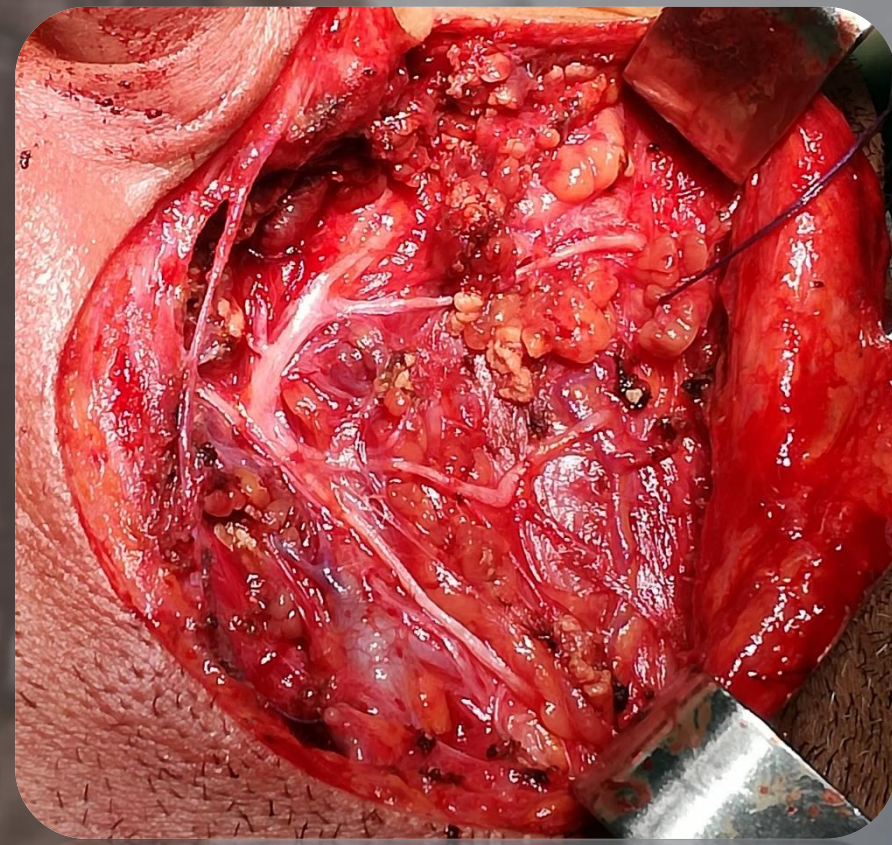
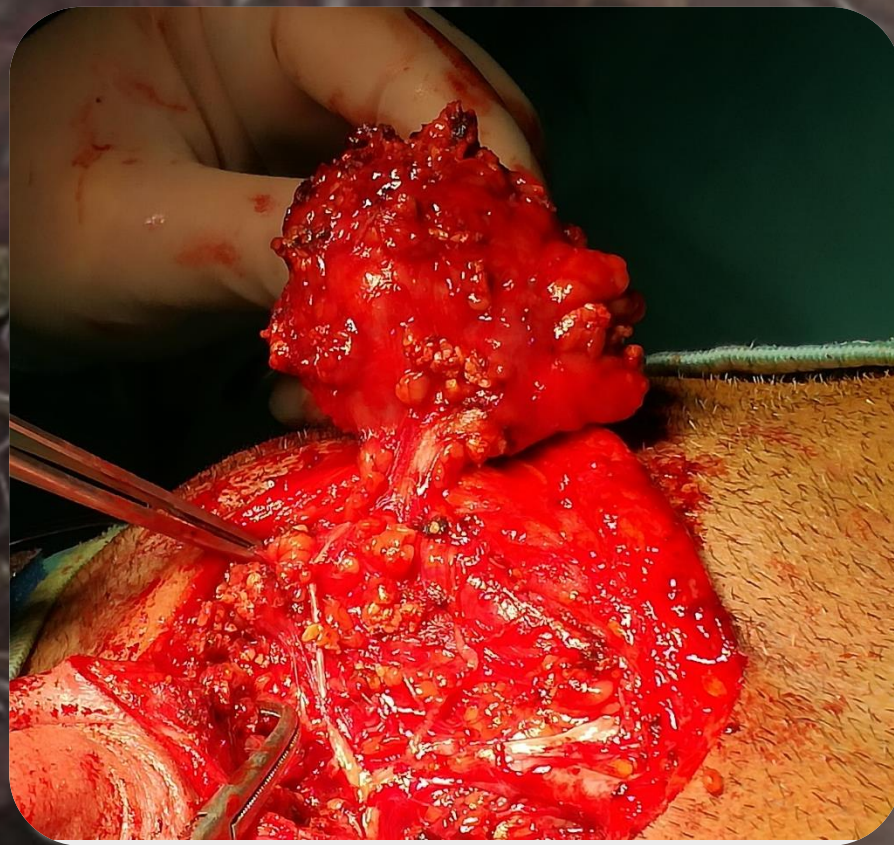
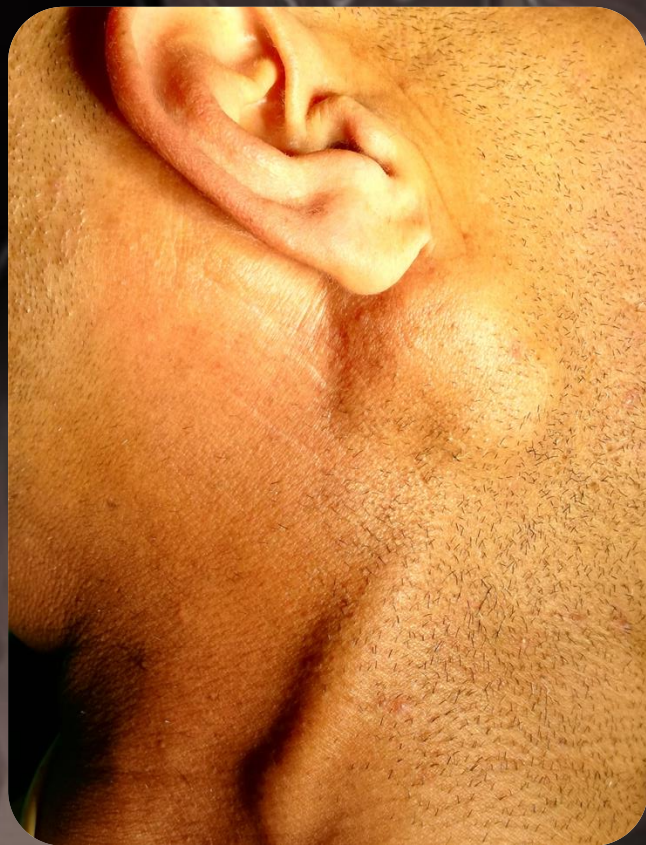

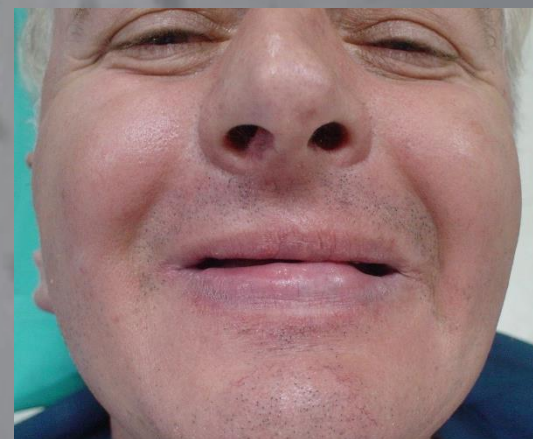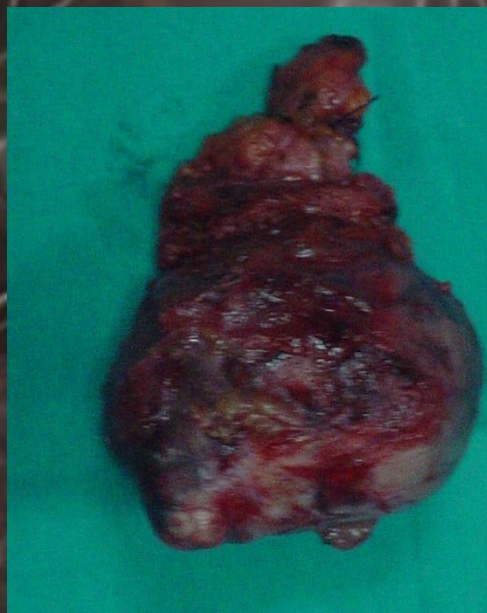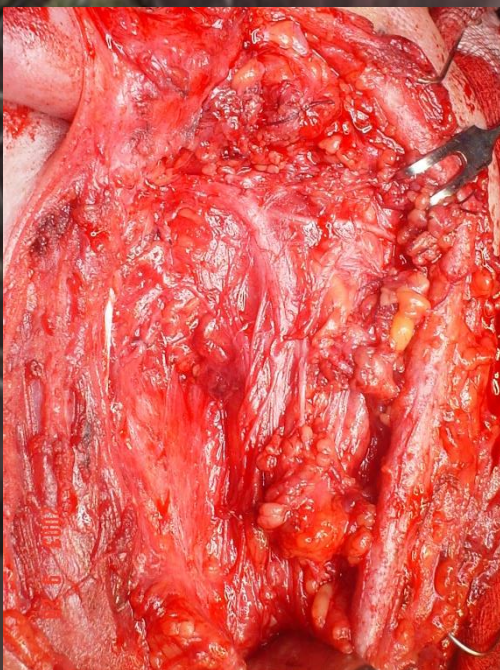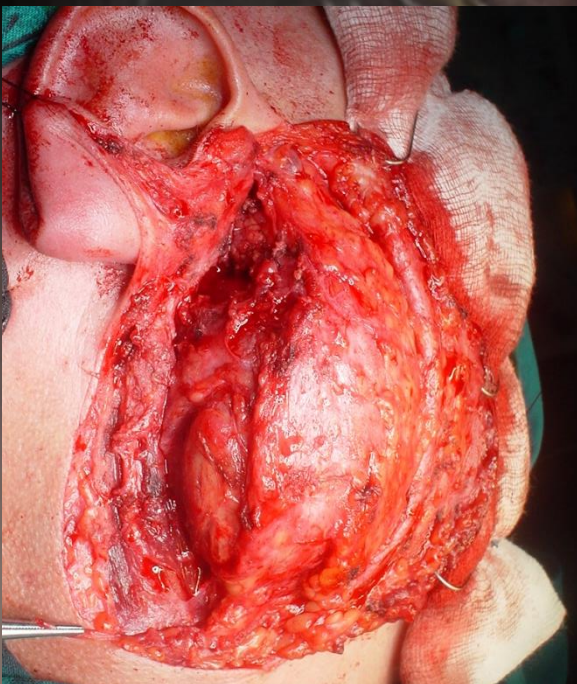


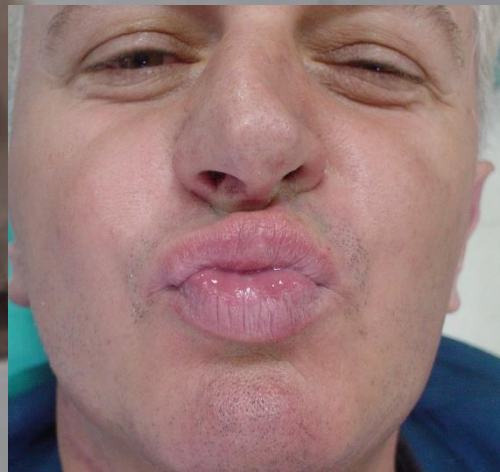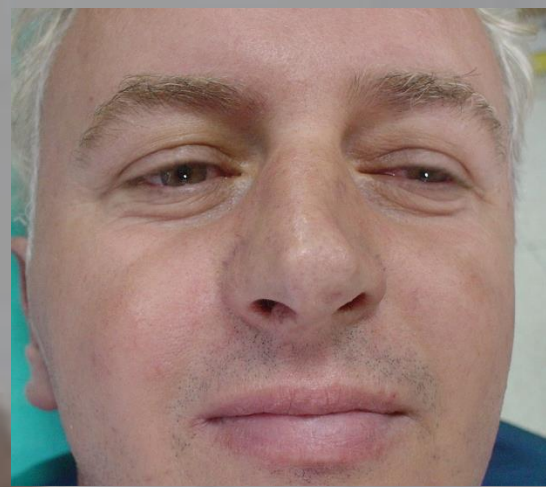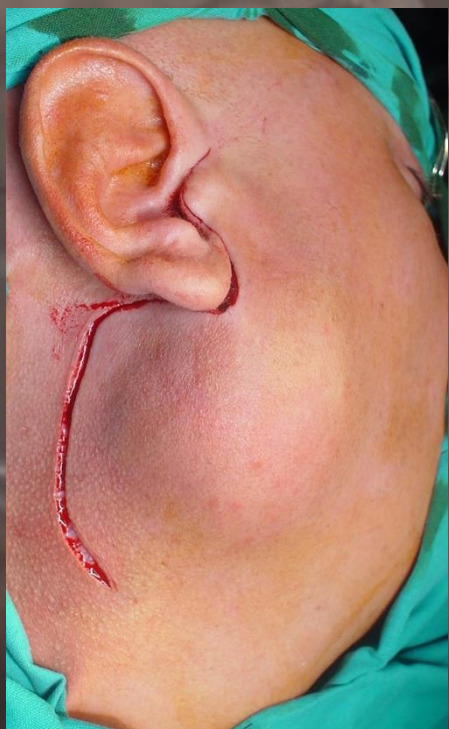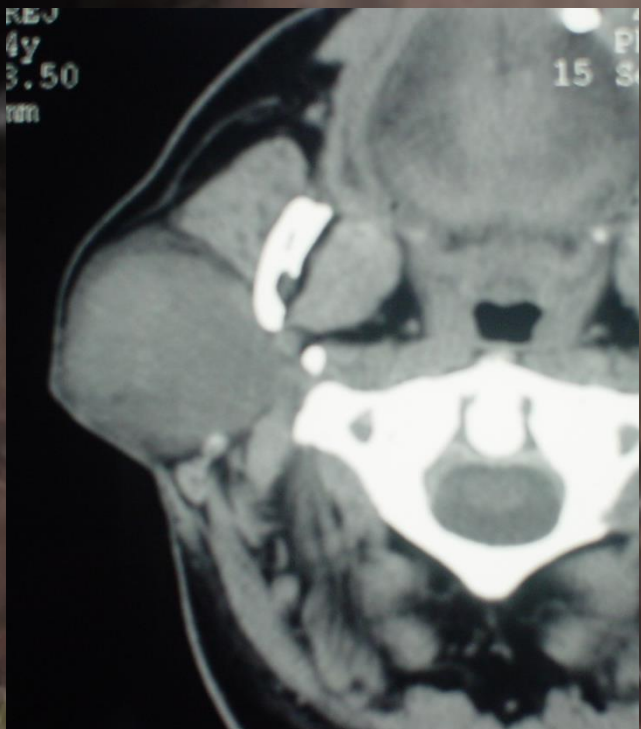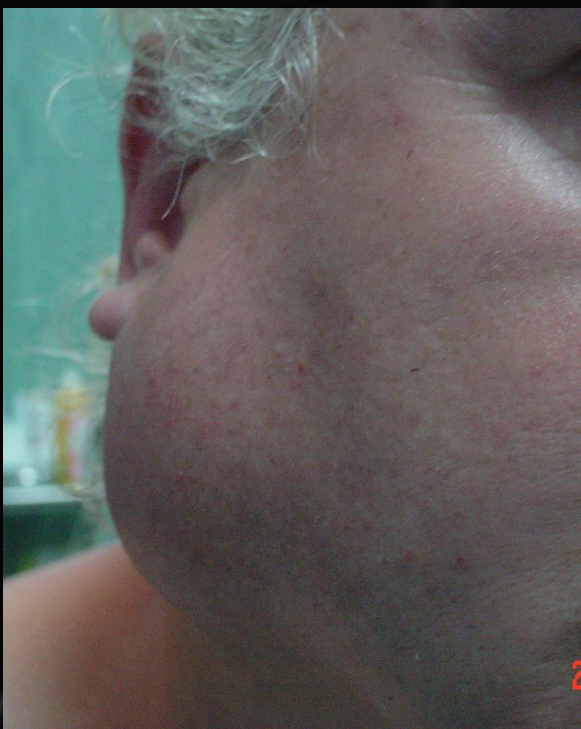Diagnosi e trattamento di patologie benigne delle ghiandole salivari maggiori

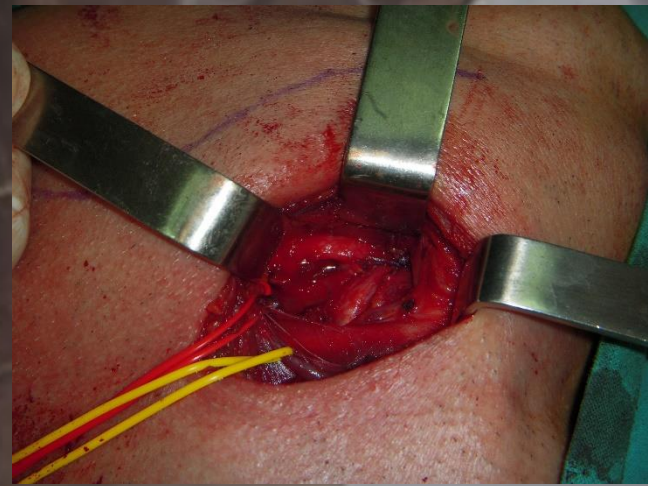
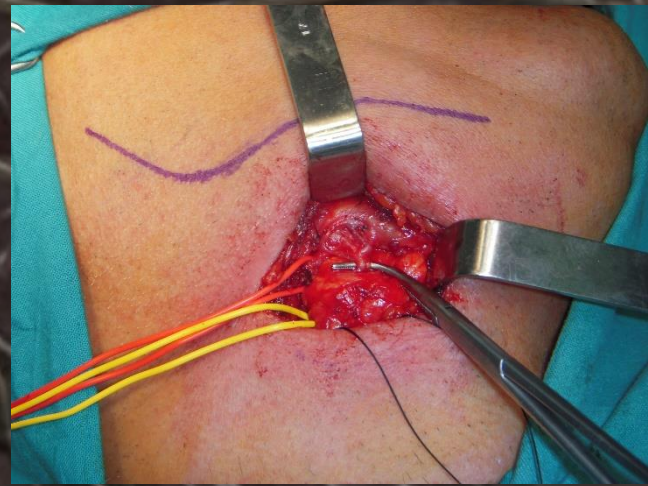
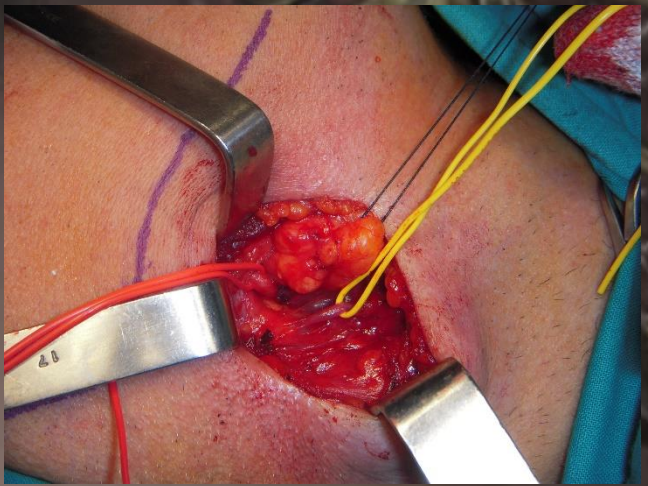
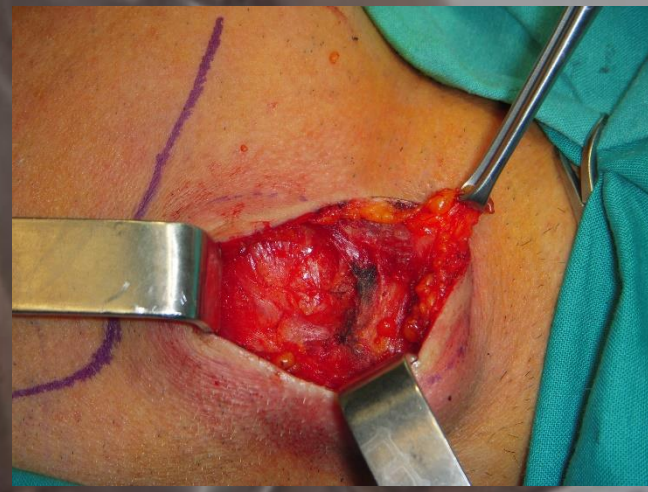
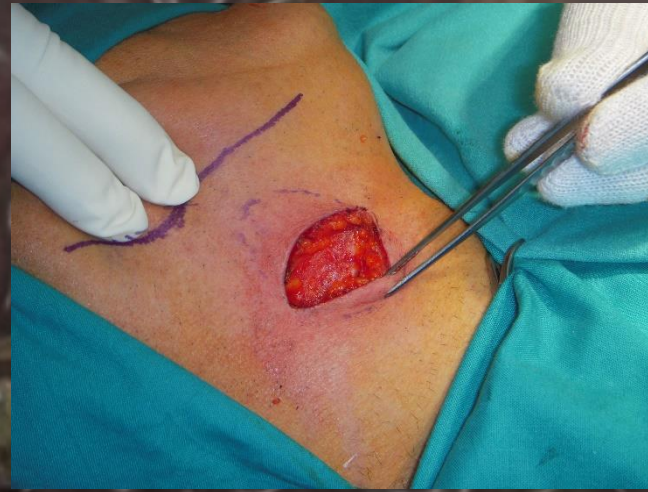
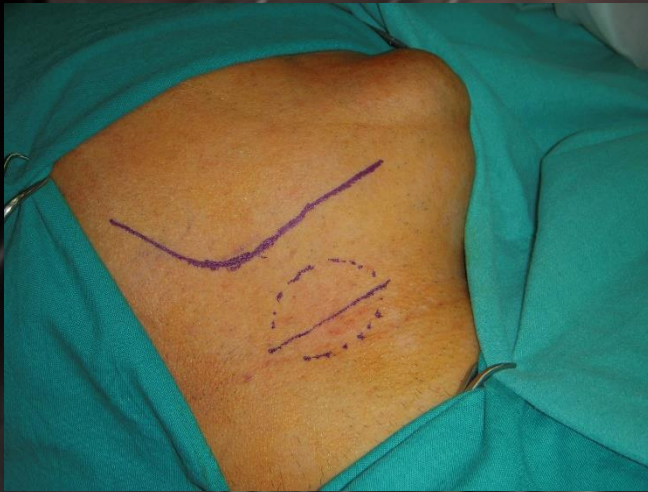
ADENOMI PAROTIDEI

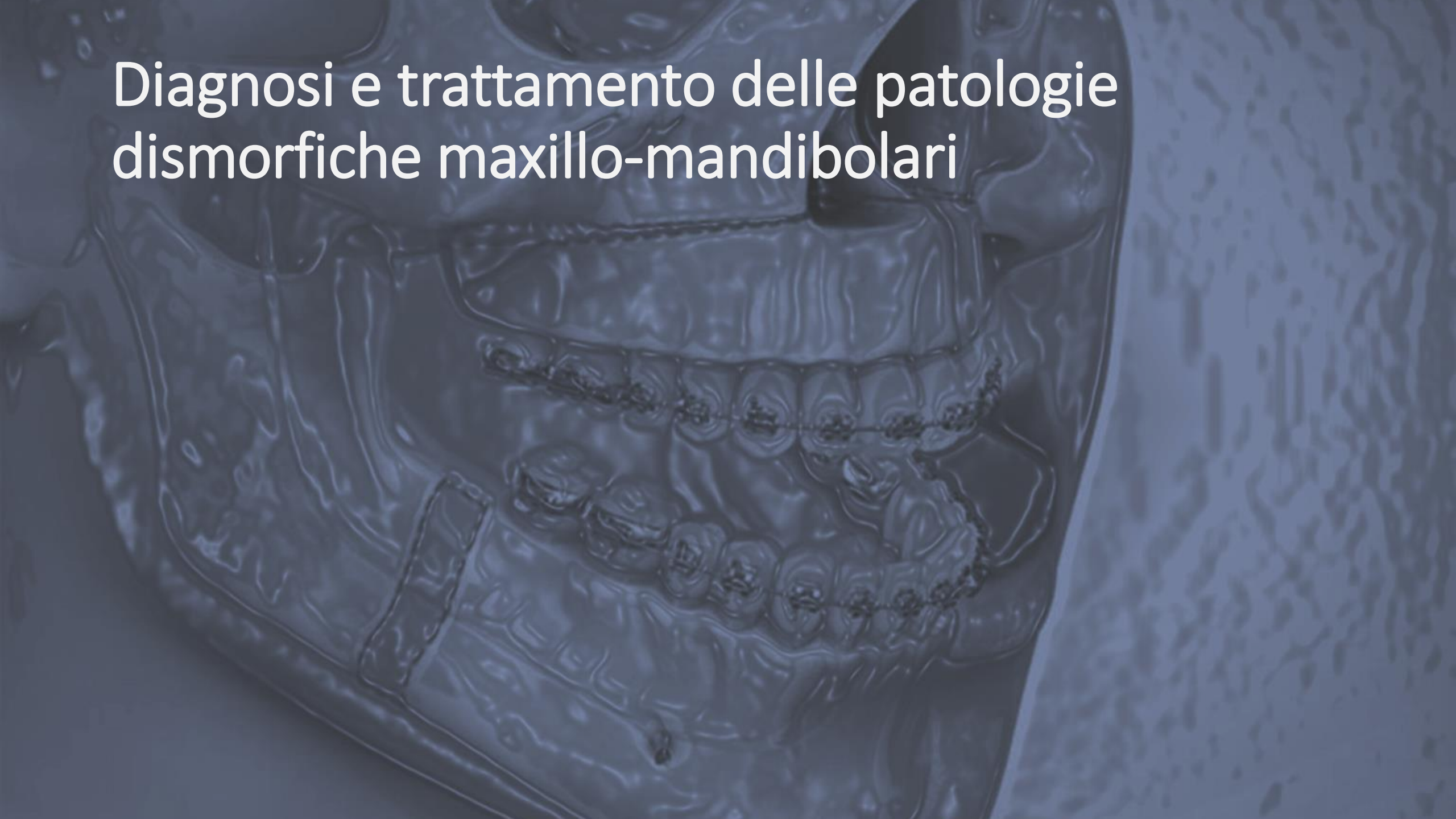



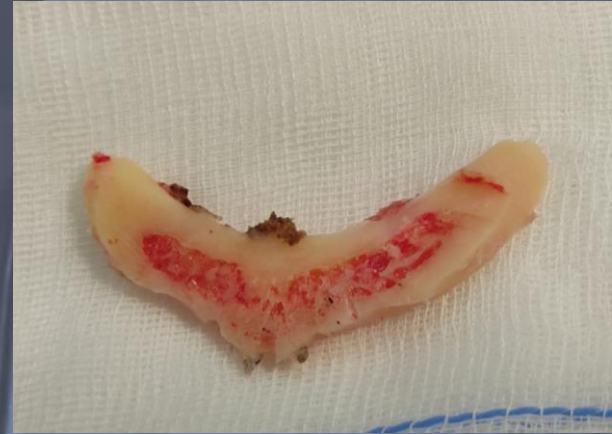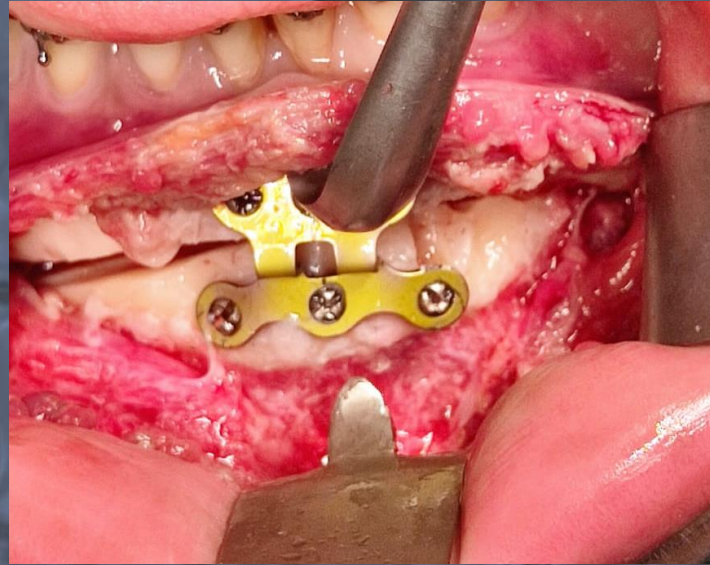
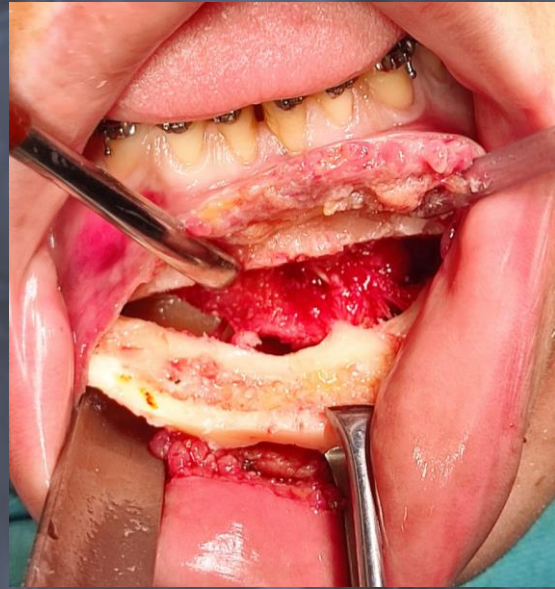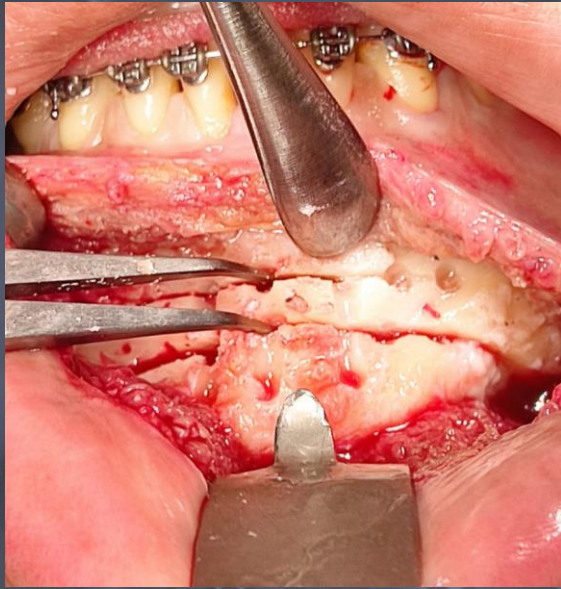PATOLOGIE GHIANDOLA SOTTOMANDIBOLARE



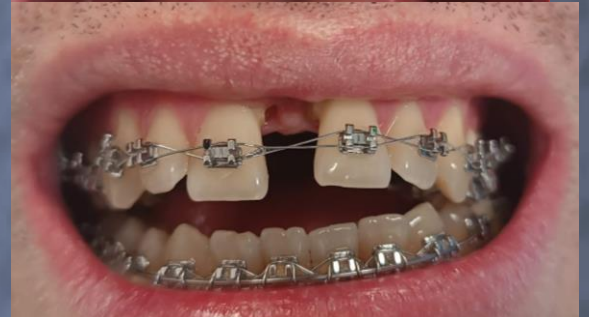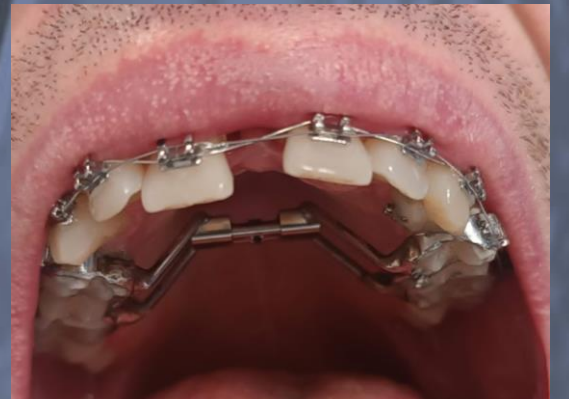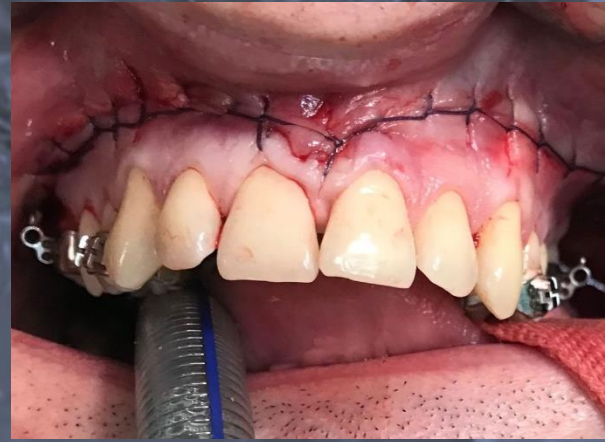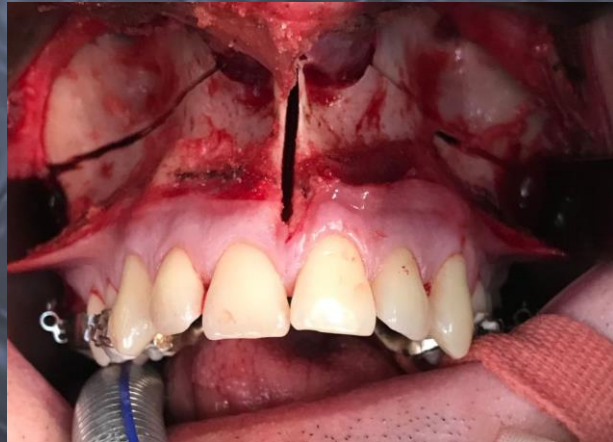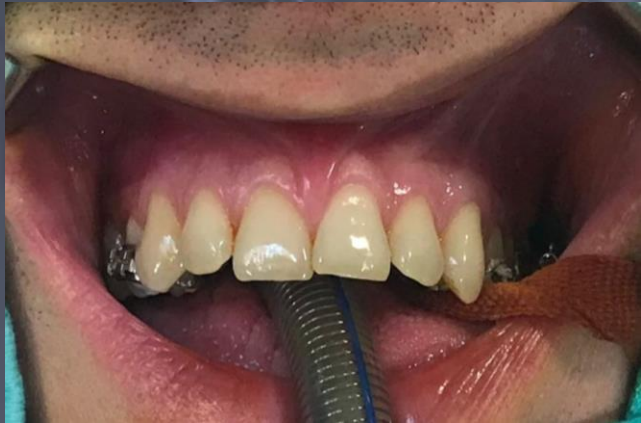Diagnosi e trattamento delle patologie dismorfiche maxillo-mandibolari



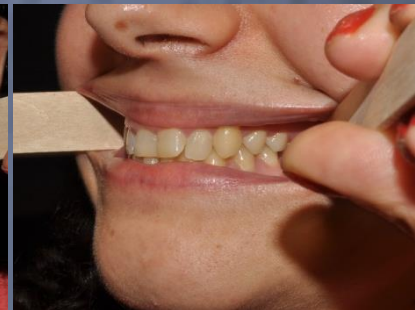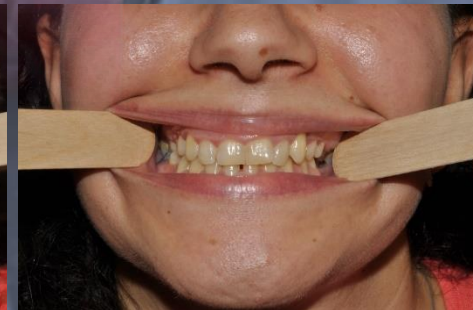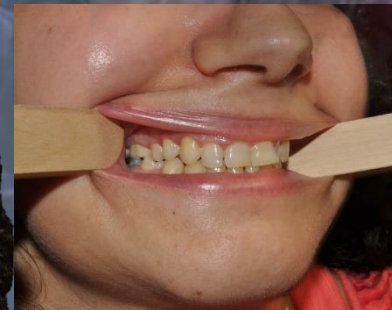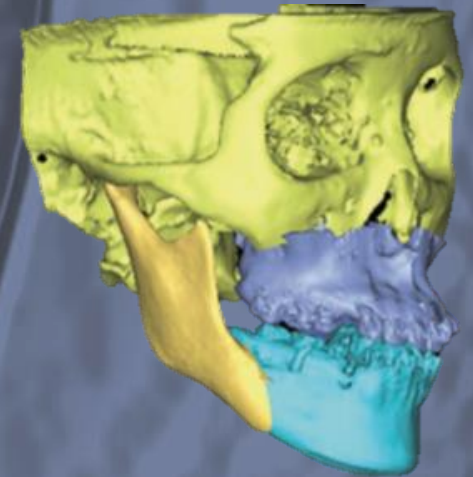
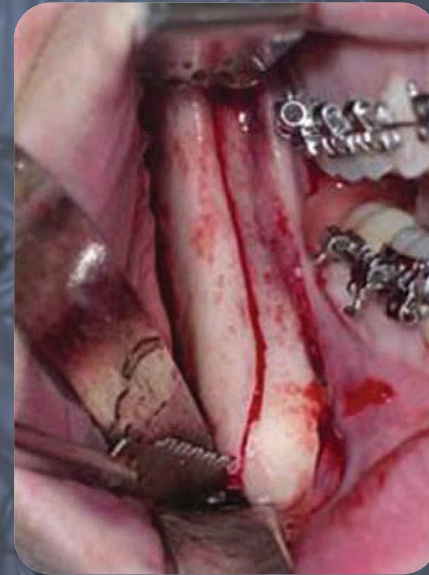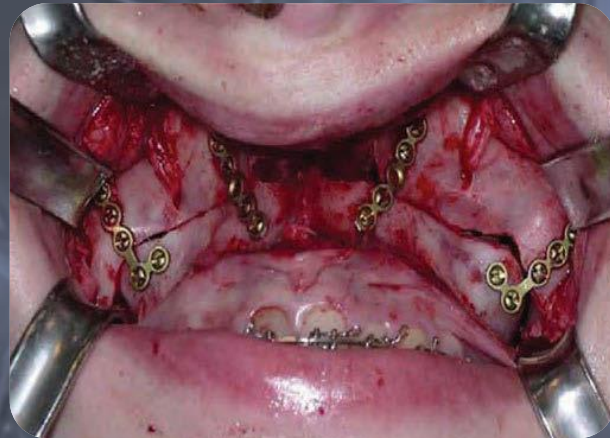
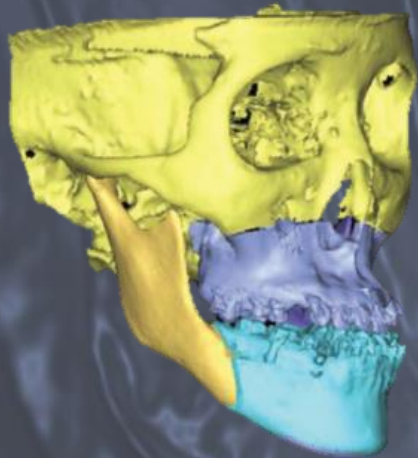
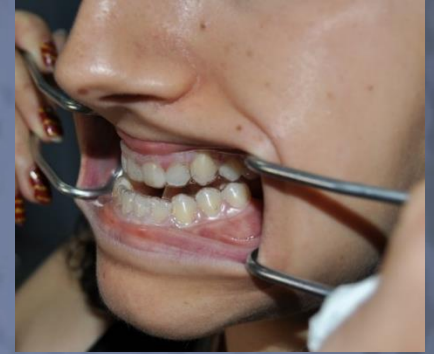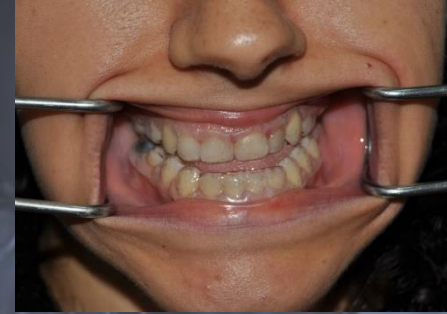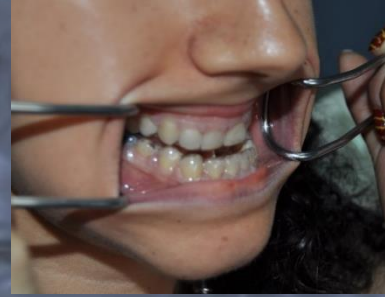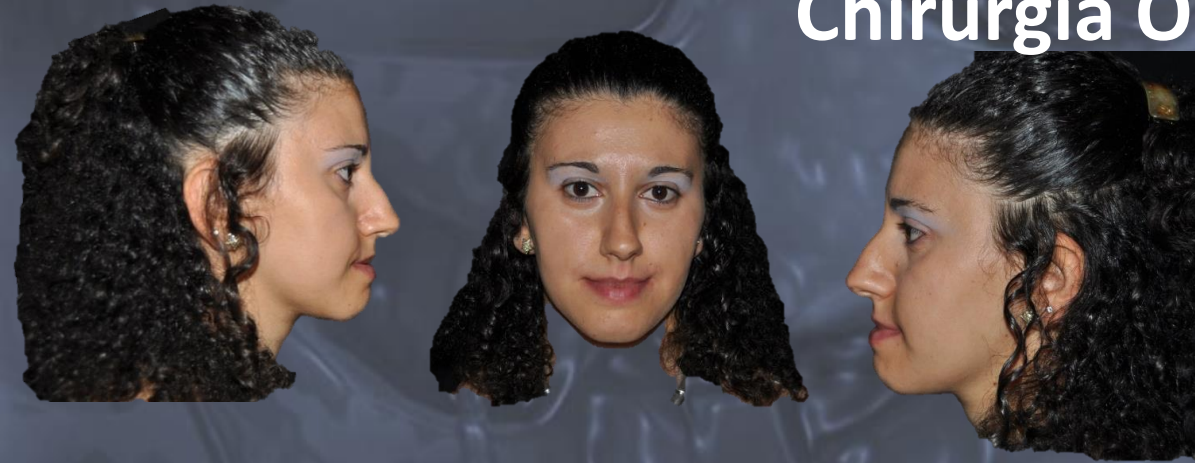Mentoplastica

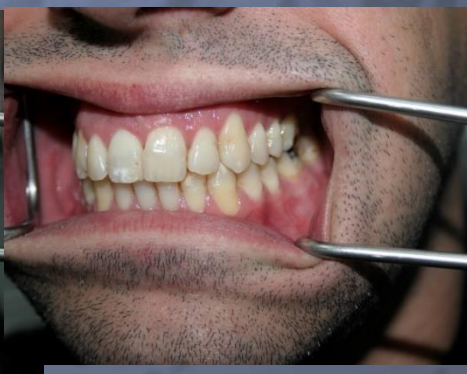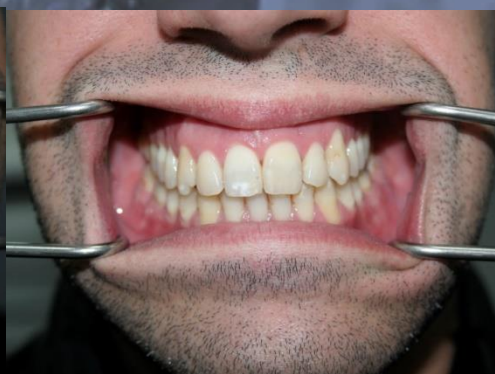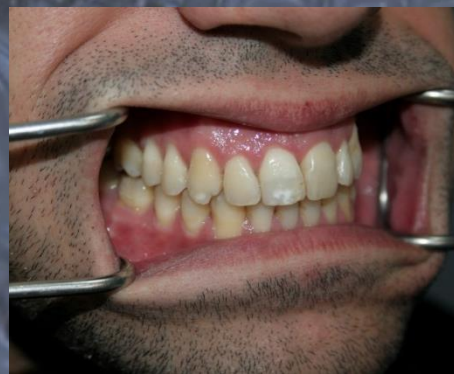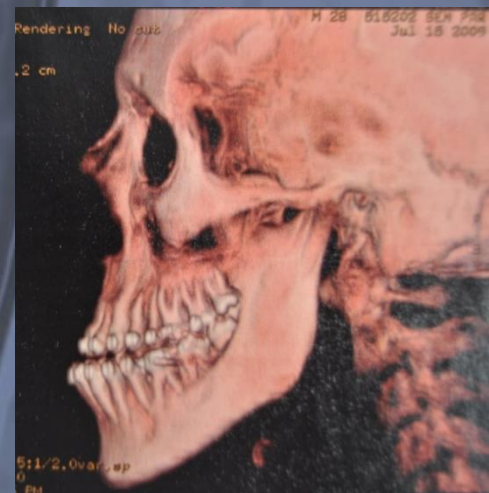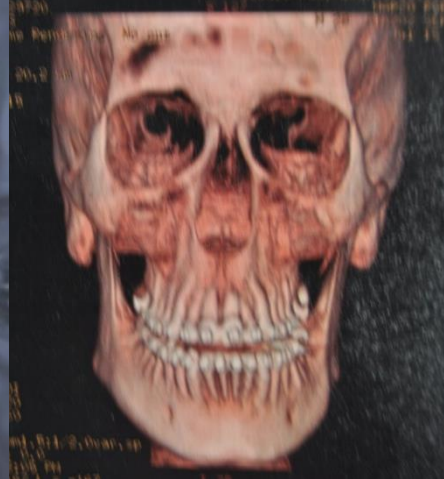
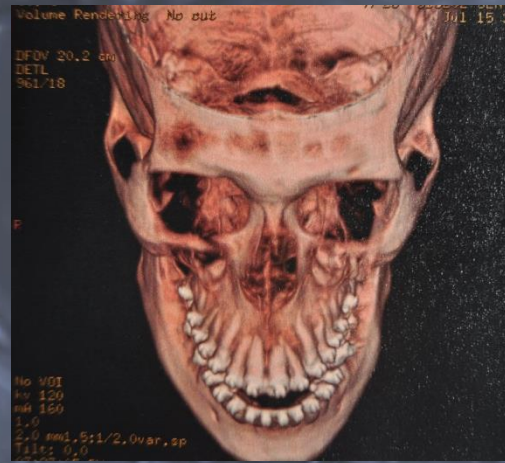
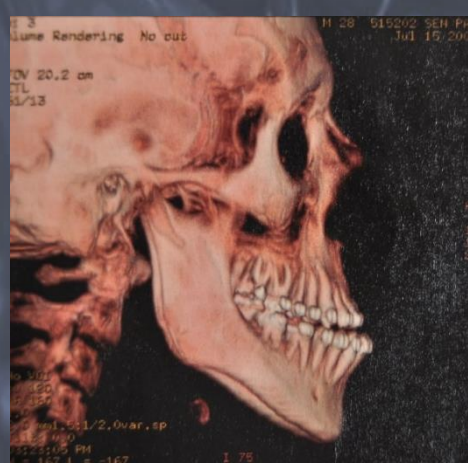


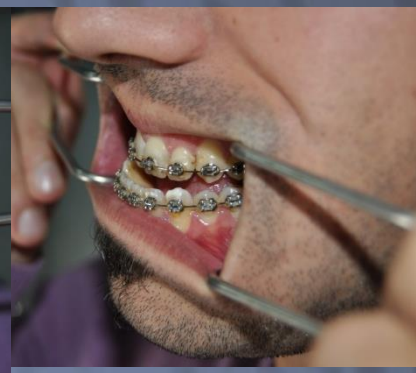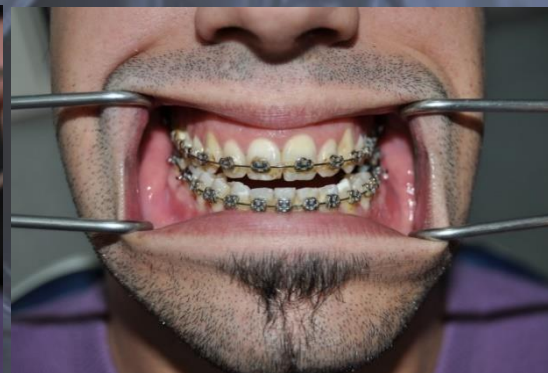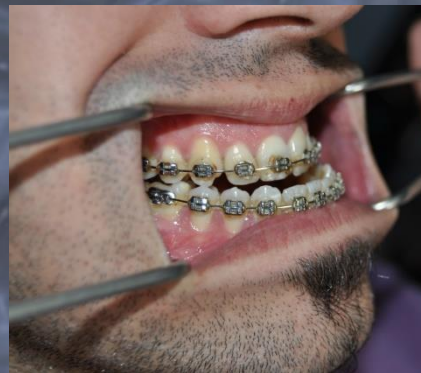S.A.R.P.E Surgically Assisted Rapid Palatal Expansion



Chirurgia Ortognatica

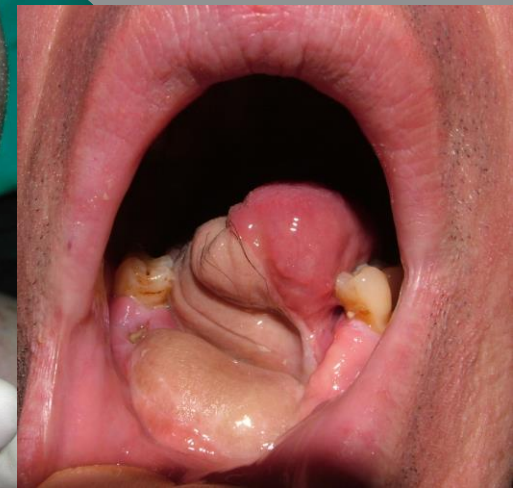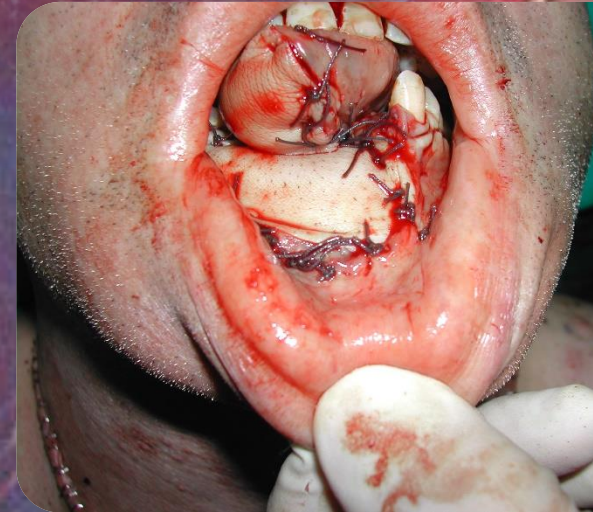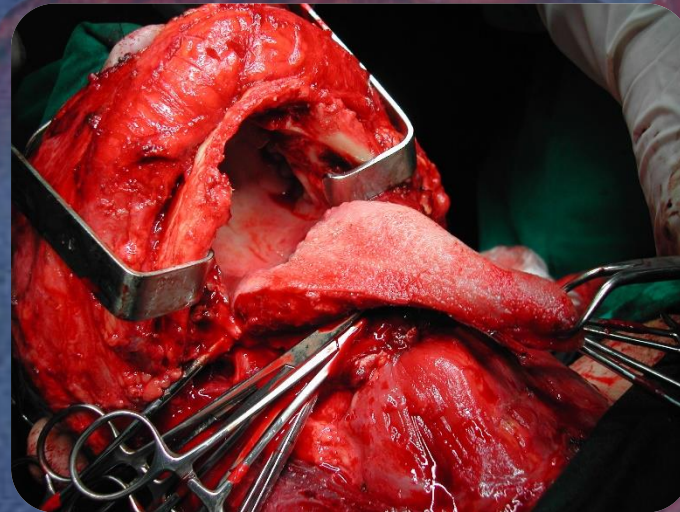
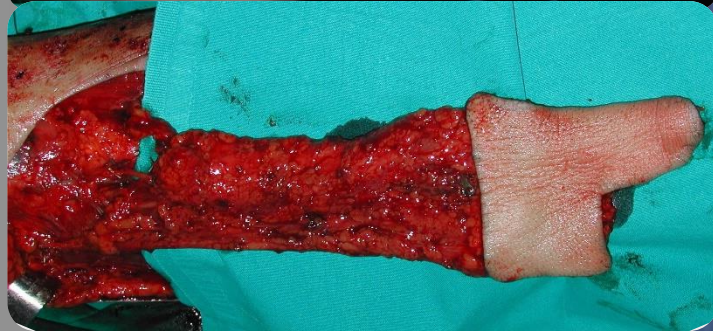
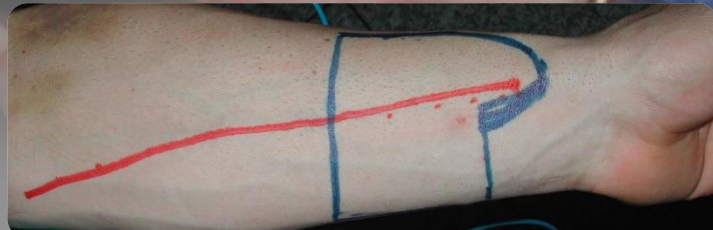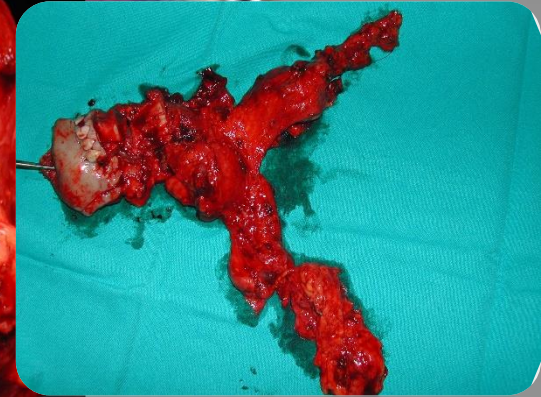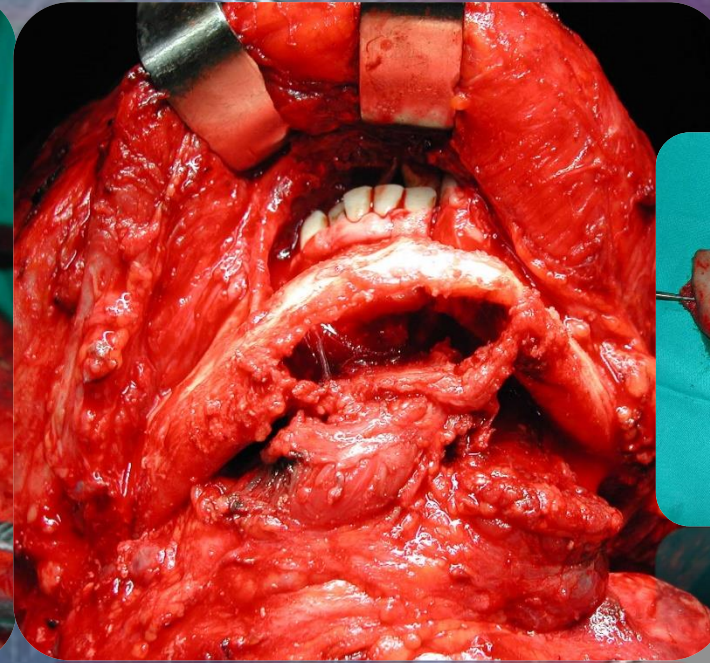
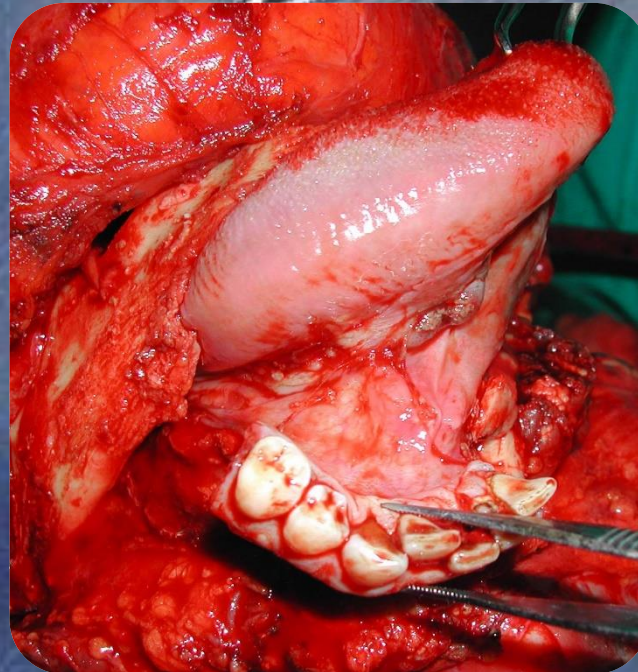




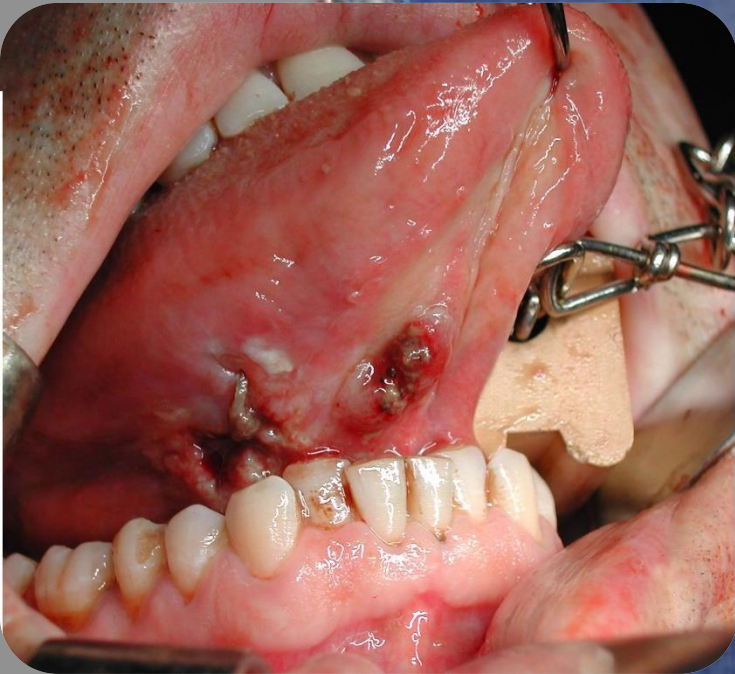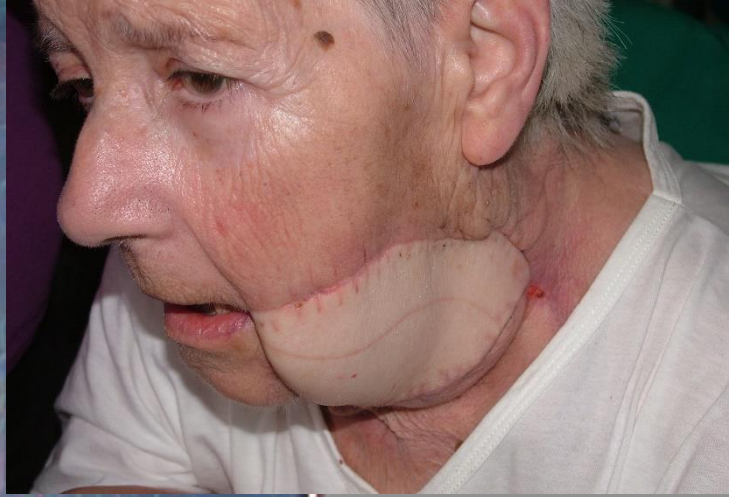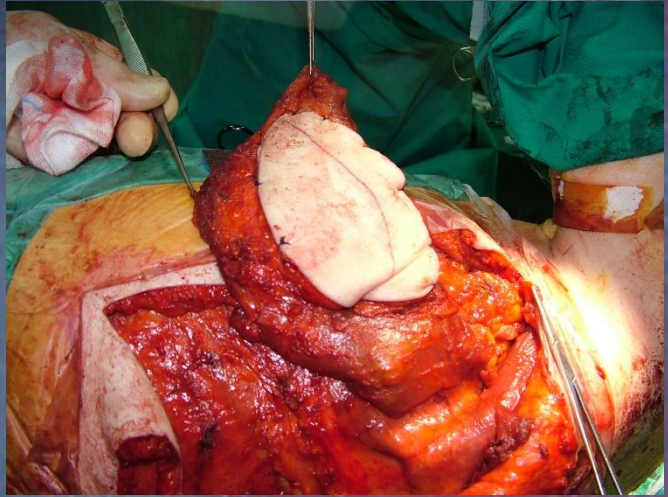
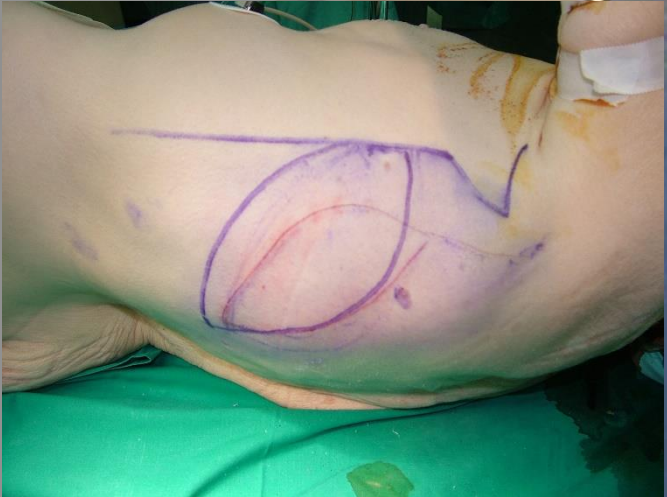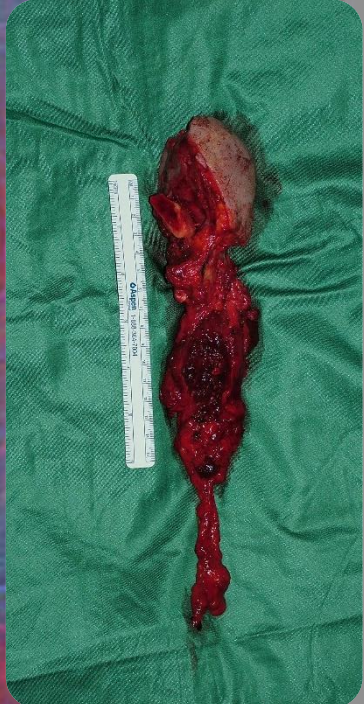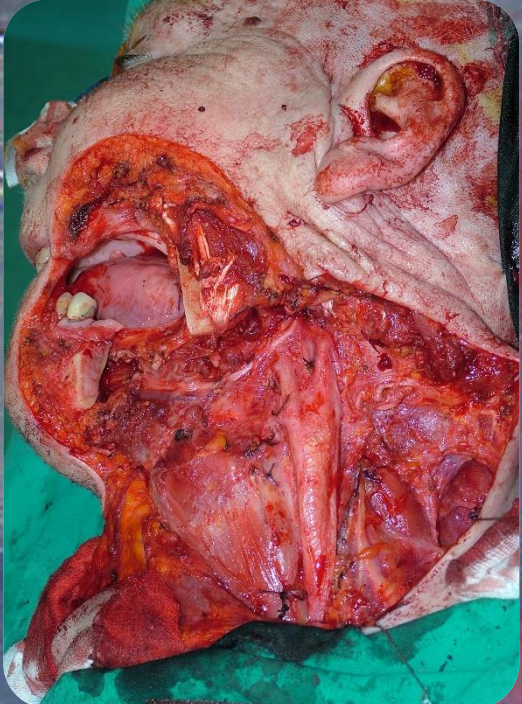
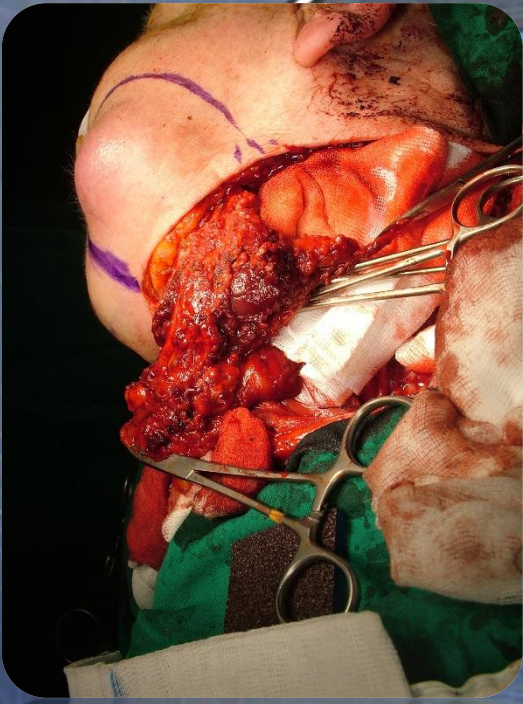
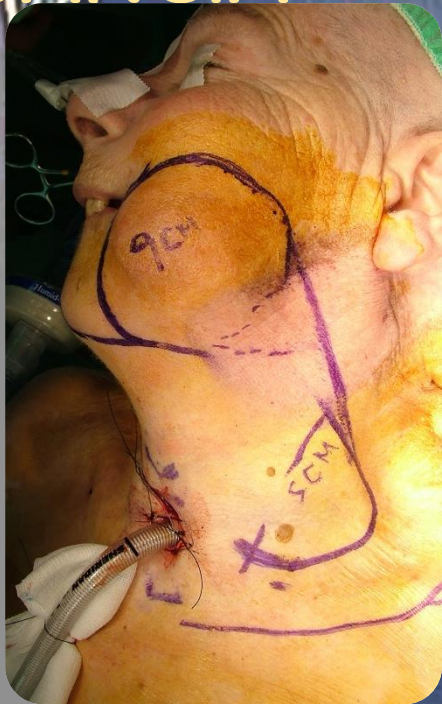An anatomical diagram of the human face and neck, rendered in a blue and white color scheme. The diagram shows the outline of the face, including the ears, eyes, nose, and mouth. Two distinct areas are highlighted in red: one on the right side of the face (viewer's right) near the eye, and another on the neck (viewer's right) near the larynx. The text is overlaid on the lower part of the face and neck.

Diagnosi e trattamento di patologie tumorali
maligne del distretto maxillo facciale

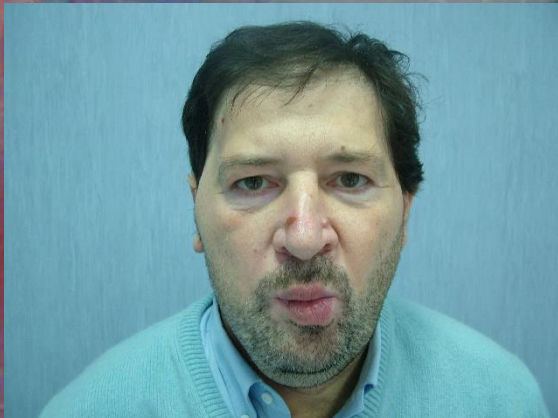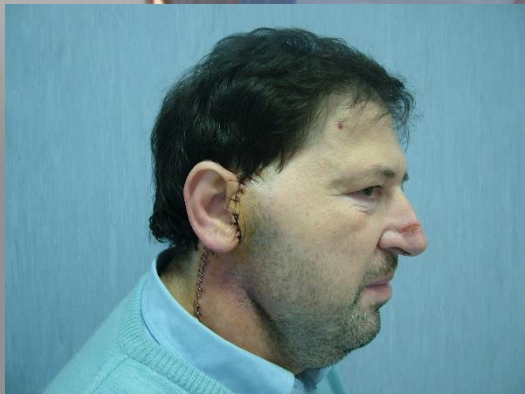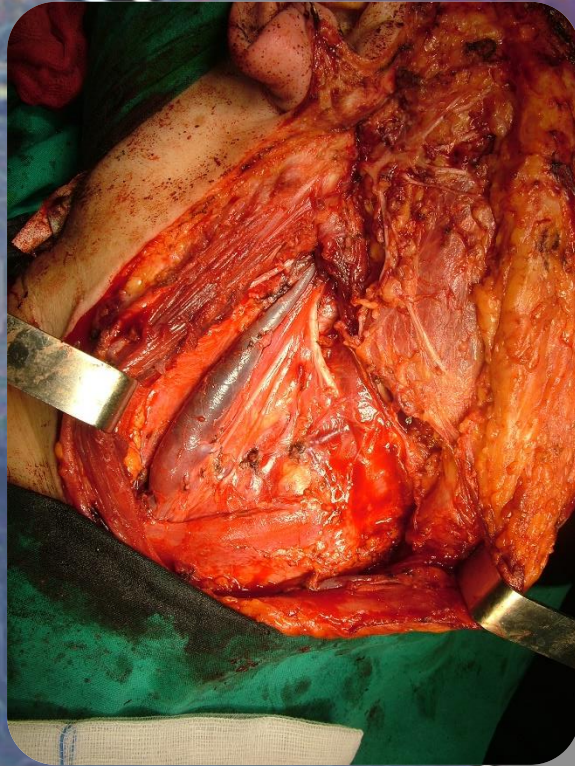
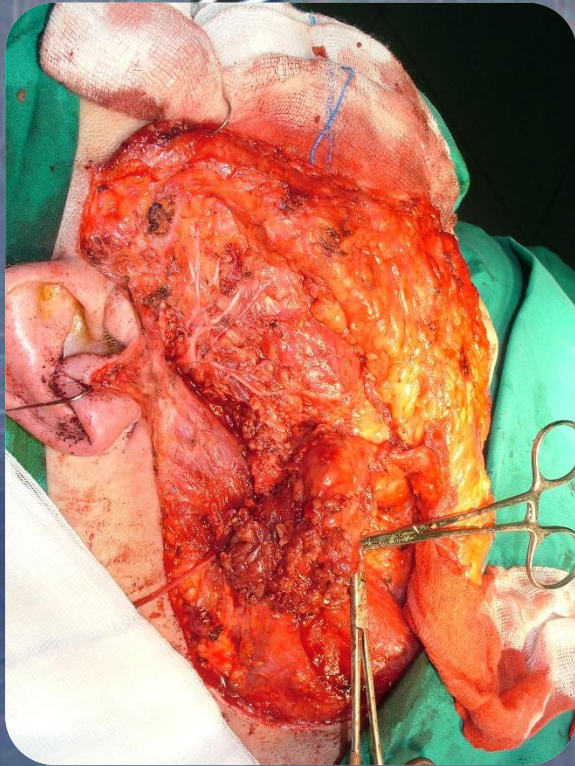
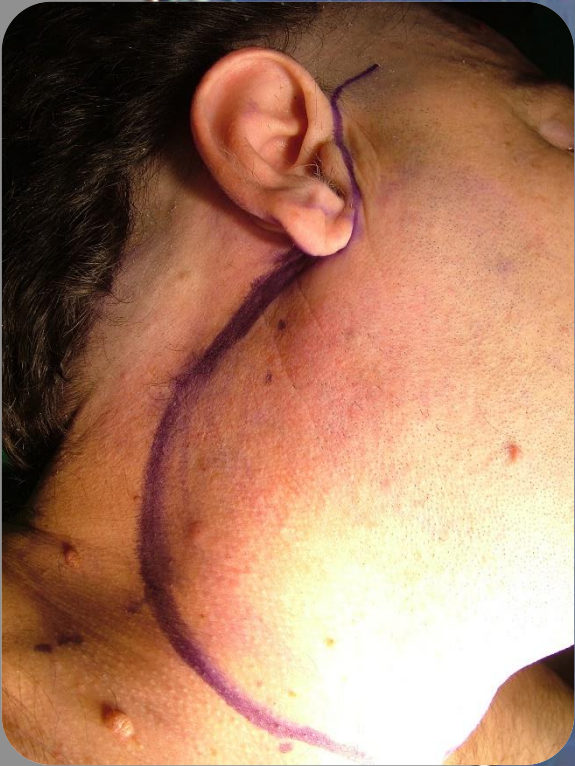Ca pavimento orale



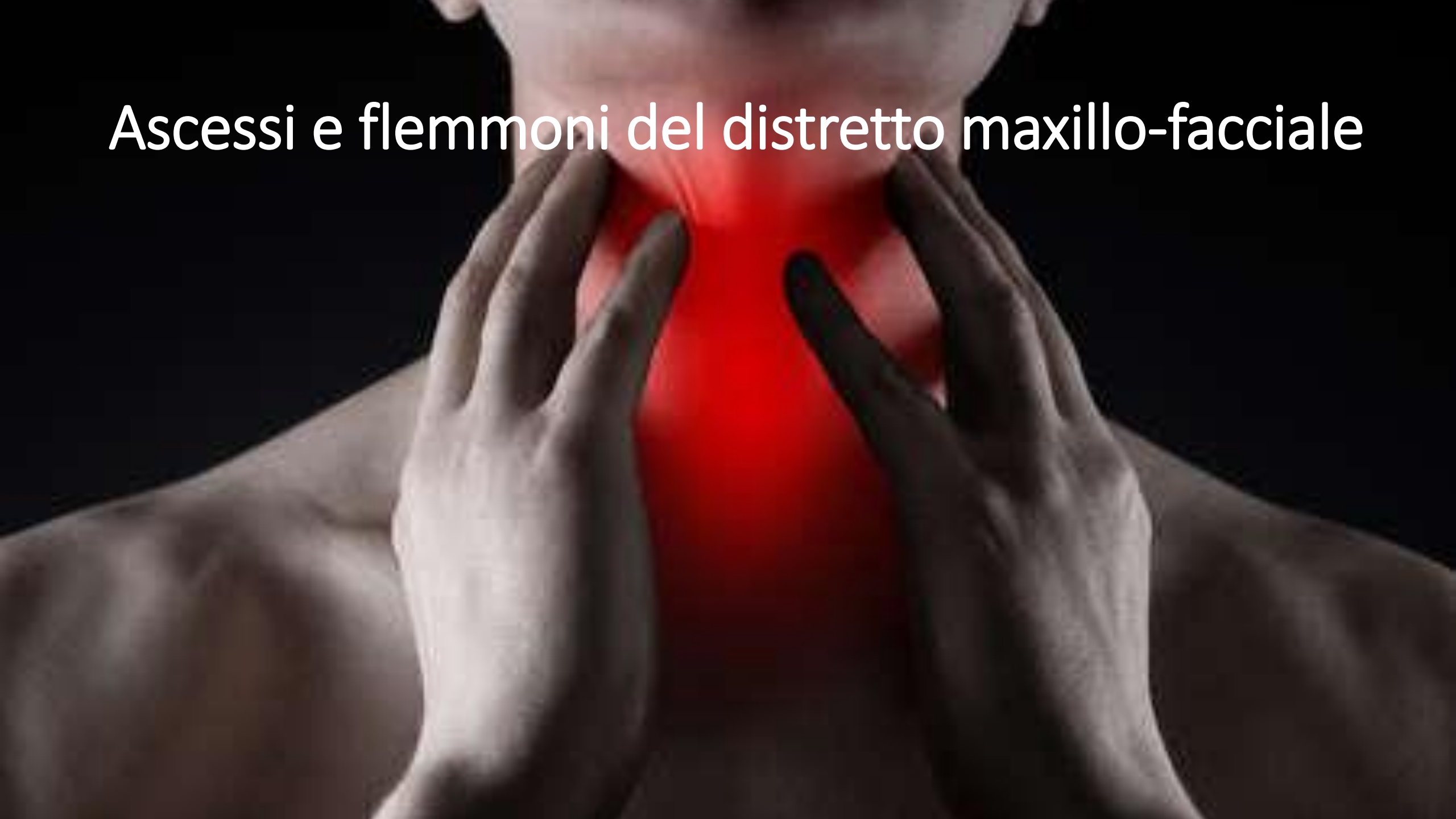CA GUANCIA



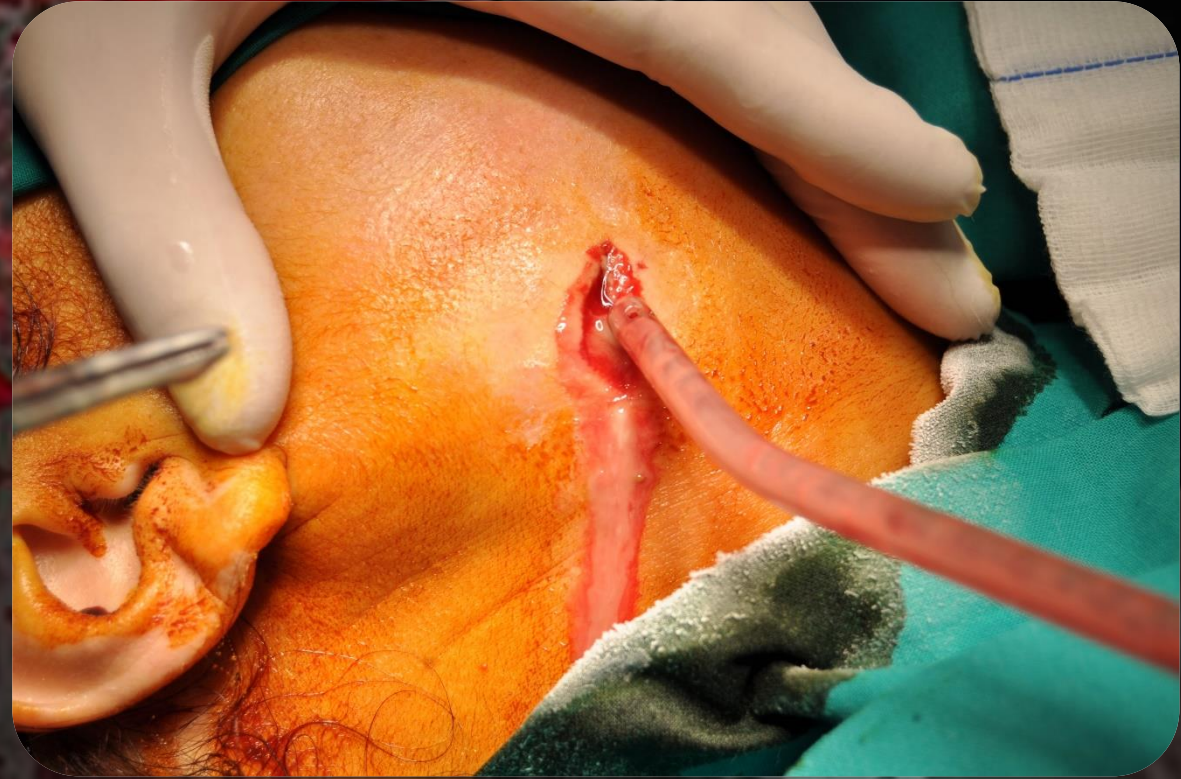
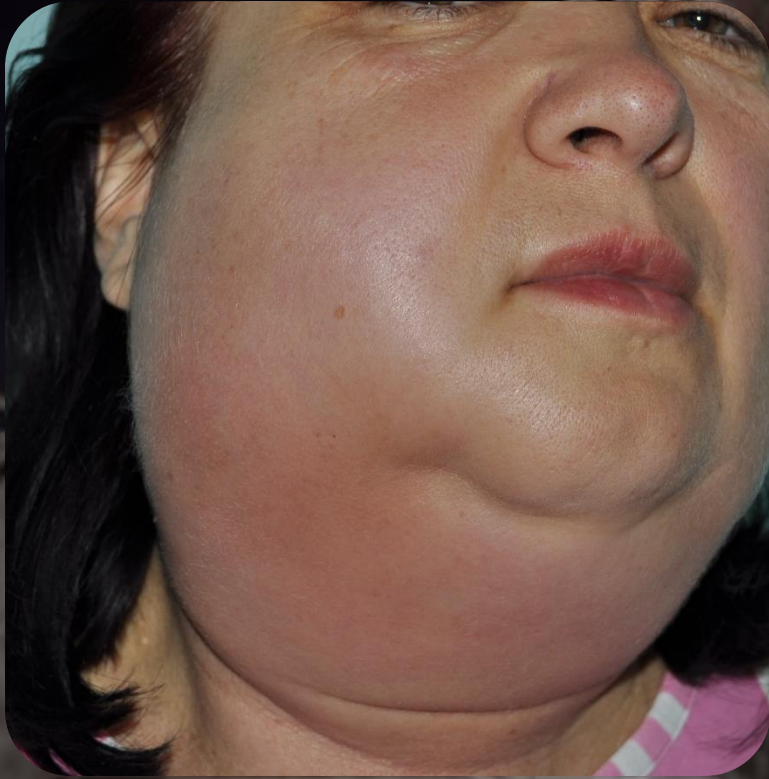
CA PAROTIDE



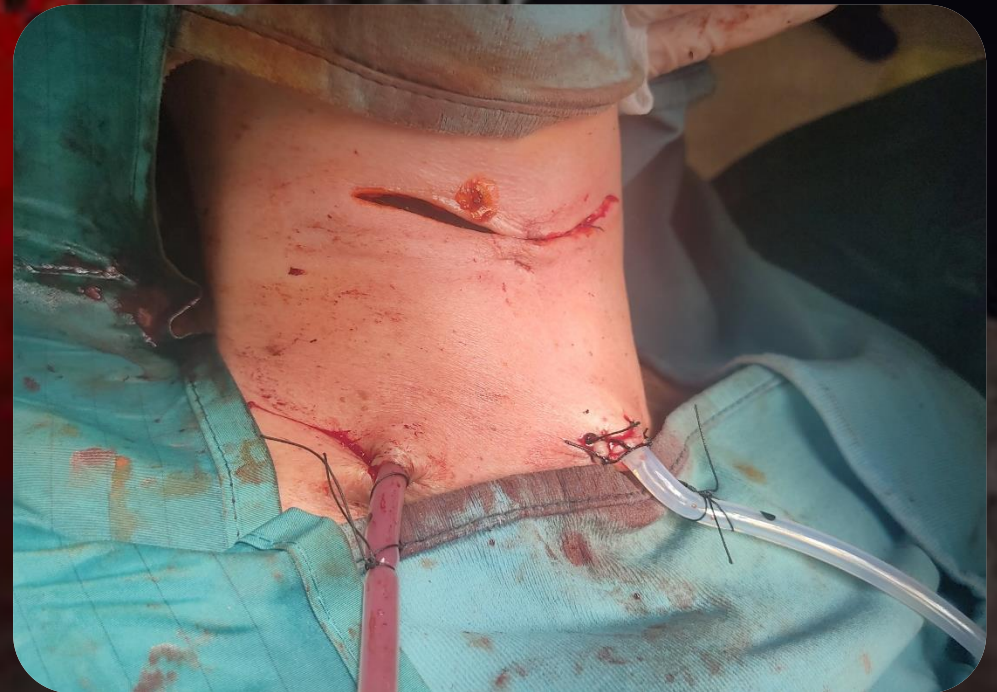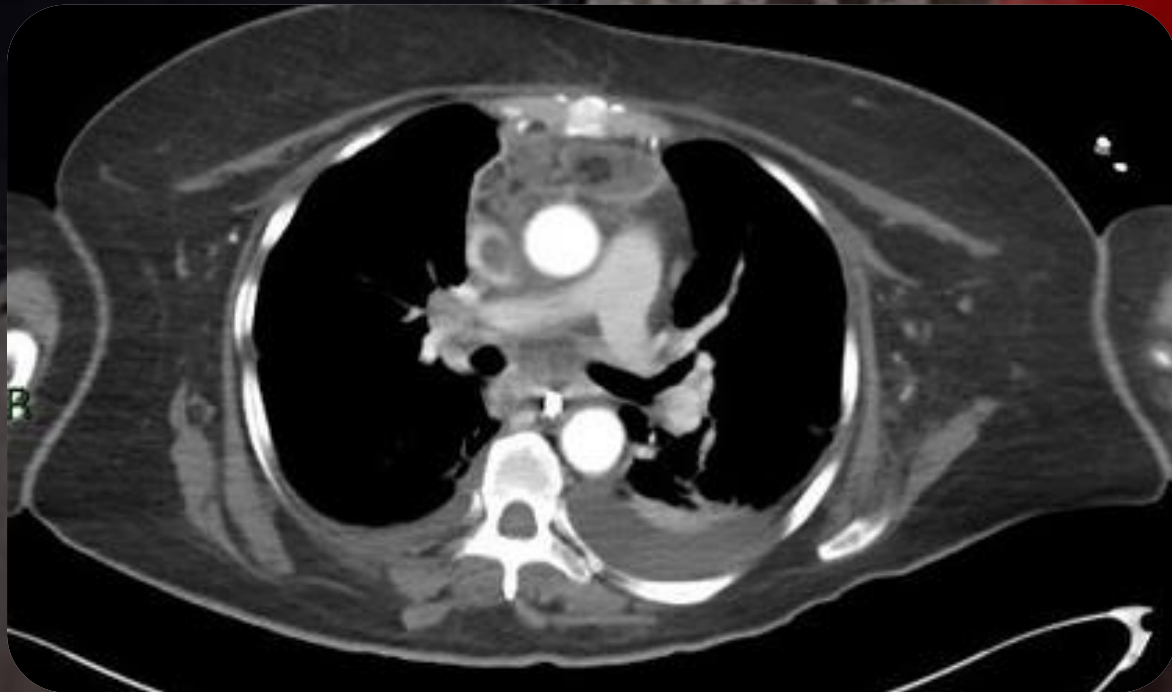Ascessi e flemmoni del distretto maxillo-facciale



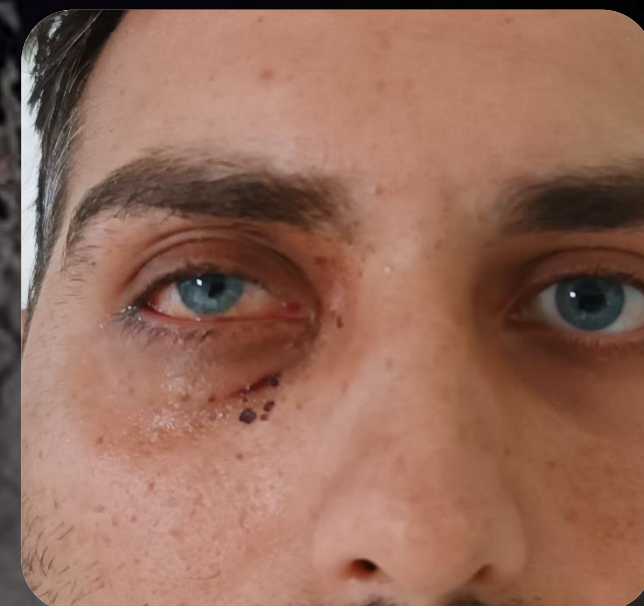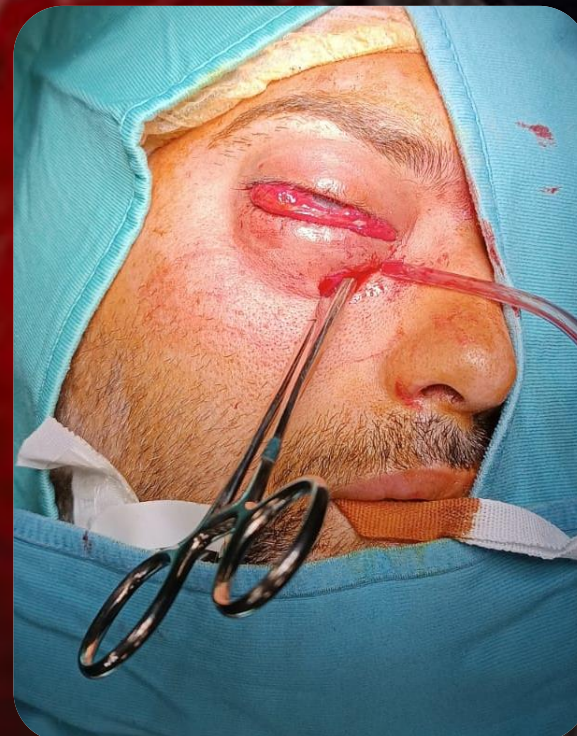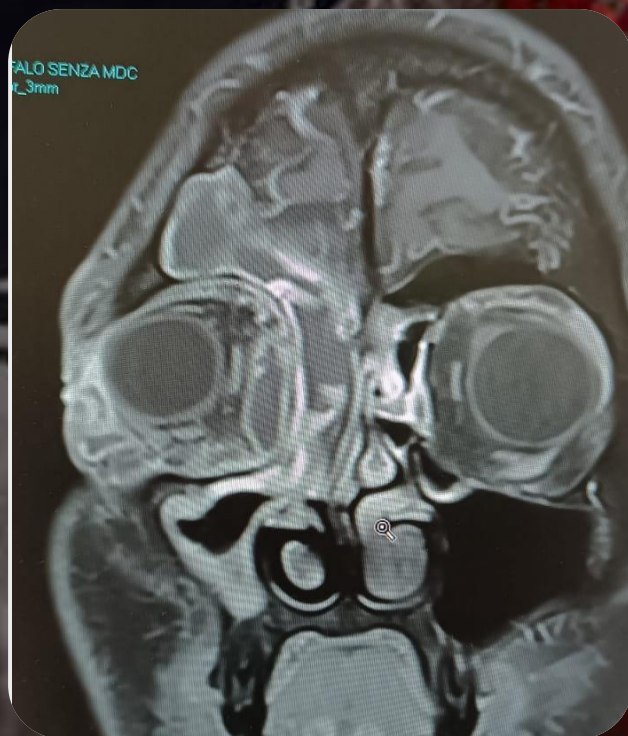
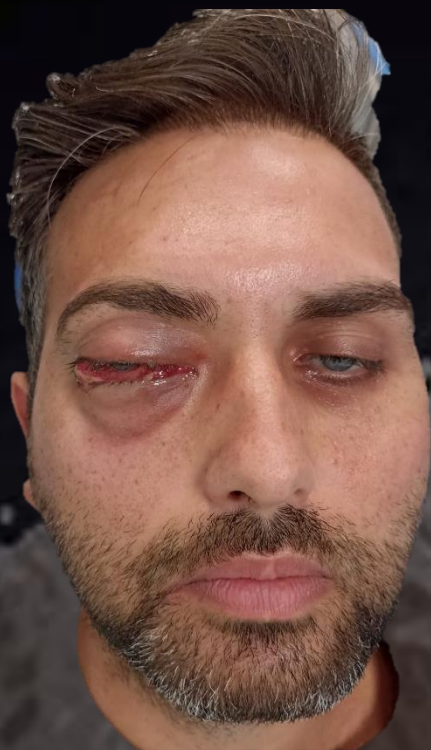Ascessi cervico-facciali



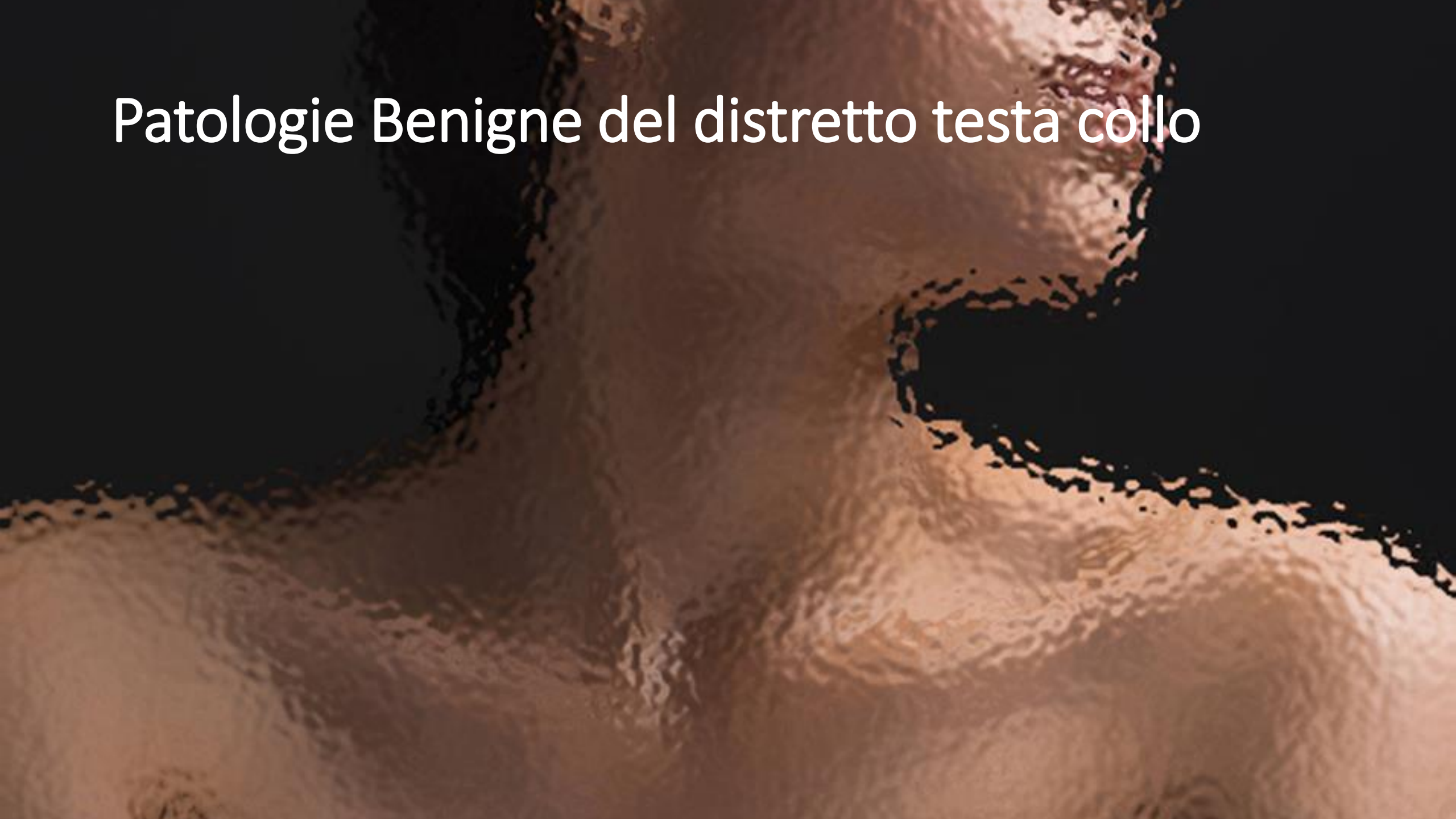
Mediastiniti



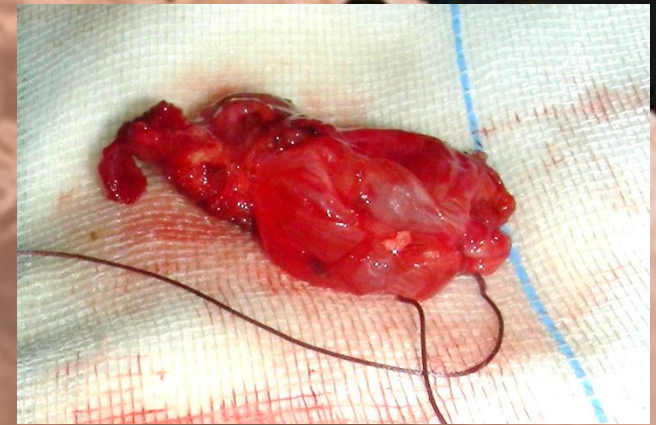
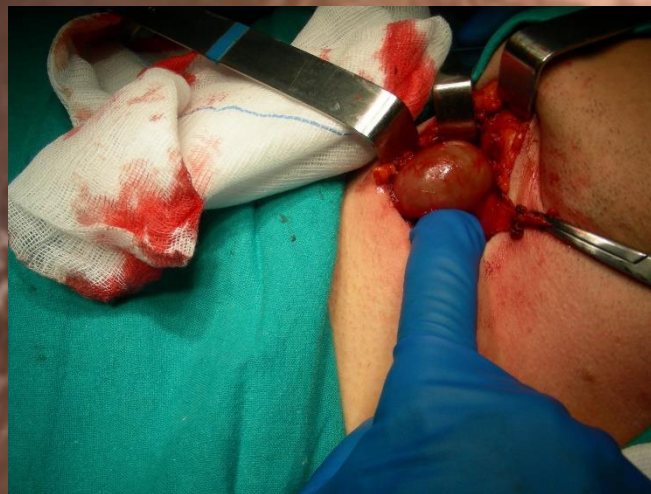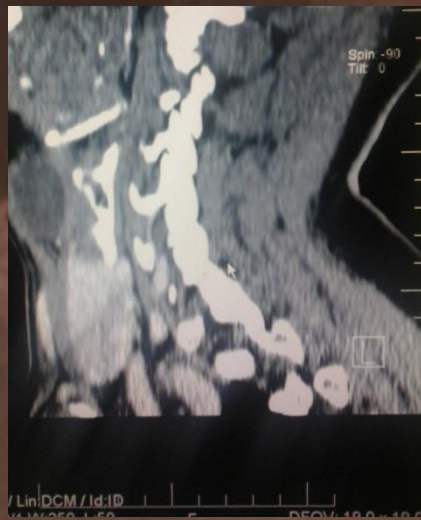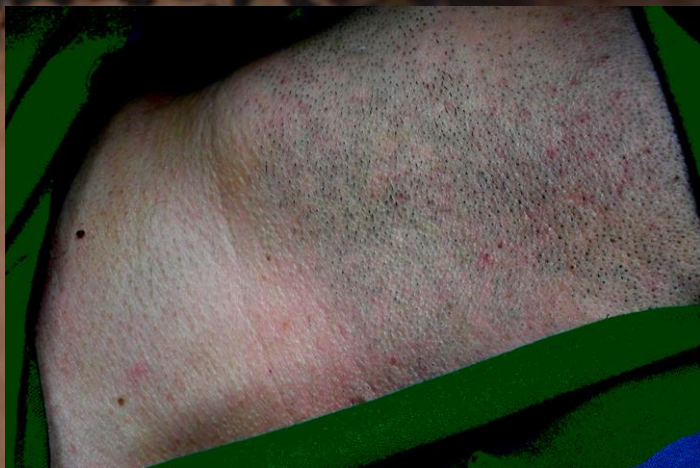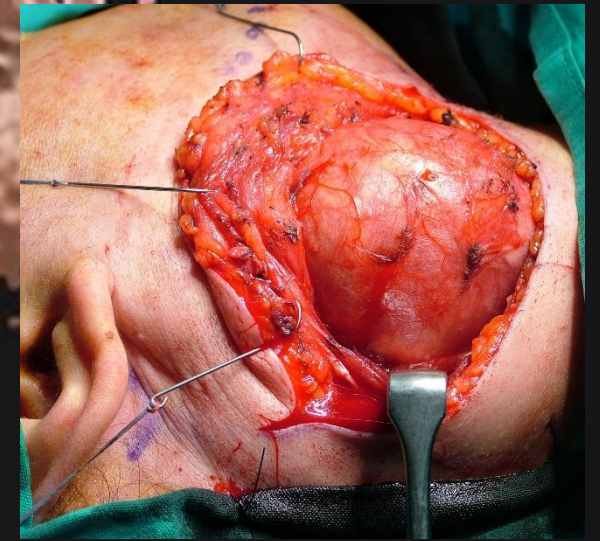
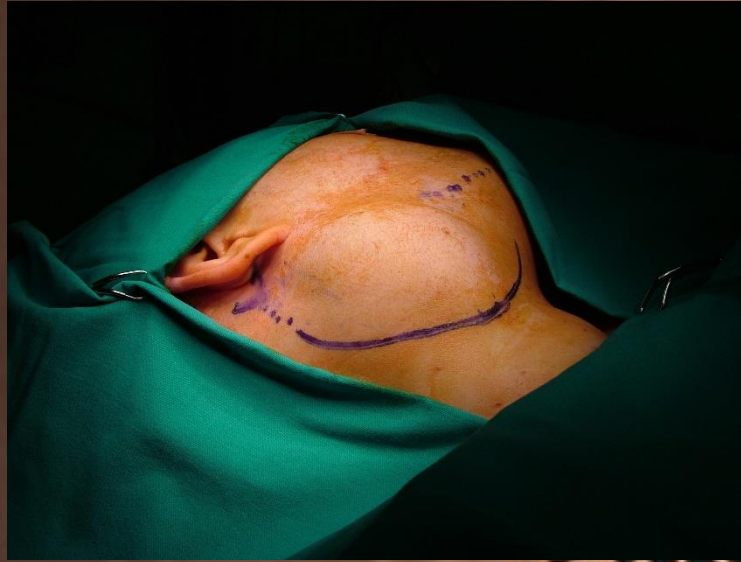
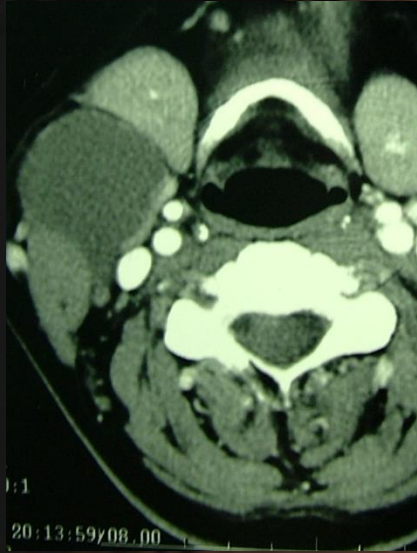
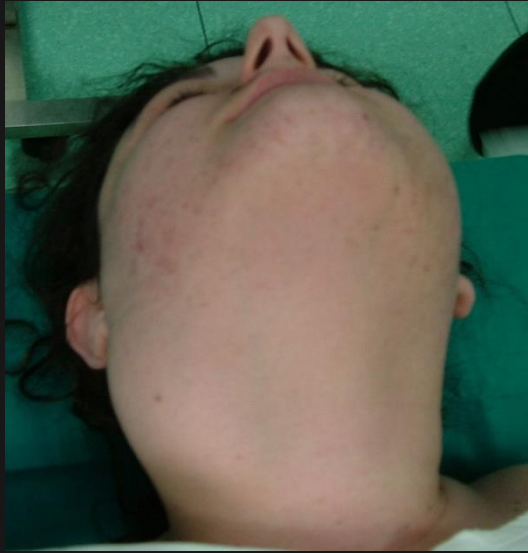ASCESSO ORBITARIO



Patologie Benigne del distretto testa collo



Cisti e fistole mediane e laterali del collo



Grazie per l'Attenzione!



Cordialità