

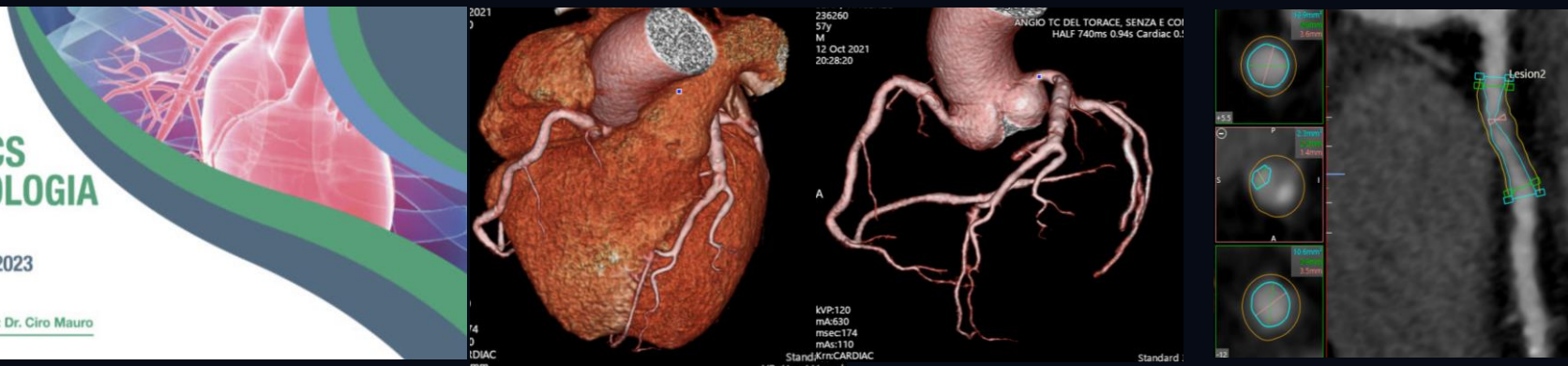HOT TOPICS IN CARDIOLOGIA 2023

13 e 14 Novembre 2023

Villa Doria D'Angri
Via F. Petrarca 80, Napoli

Presidente del congresso: **Dr. Ciro Mauro**

AORN Cardarelli, Napoli

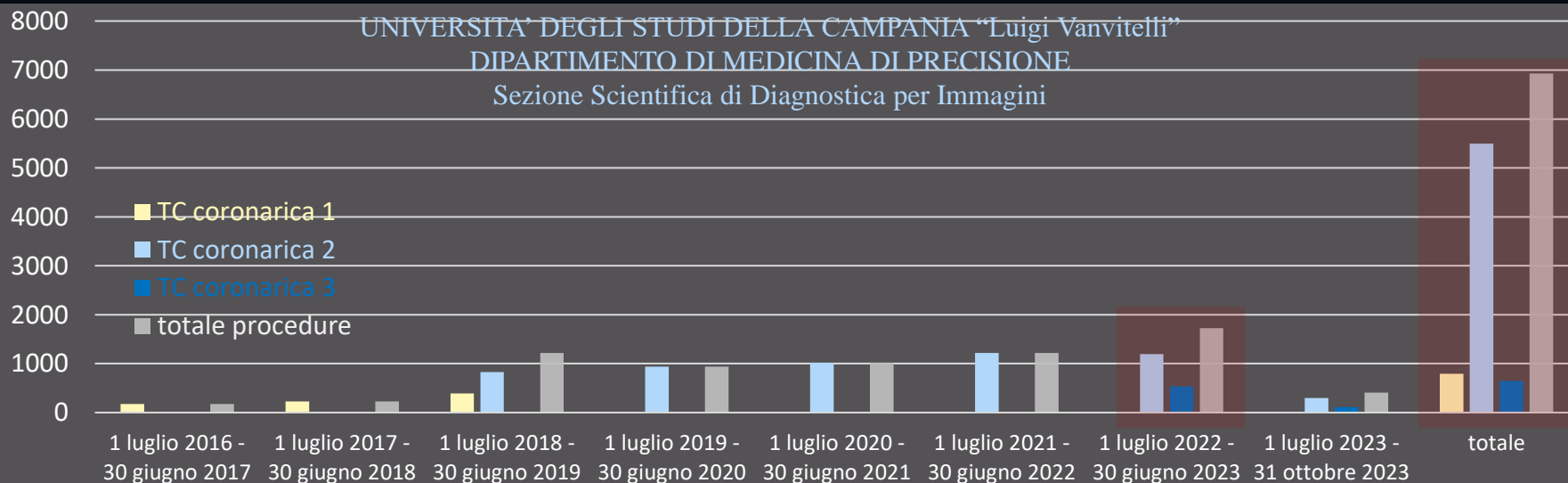


T.C. CORONARICA

UN'ALTERNATIVA ALLA CORONAROGRAFIA INVASIVA ?

Luca Del Viscovo

UNIVERSITA' DEGLI STUDI DELLA CAMPANIA "Luigi Vanvitelli"
DIPARTIMENTO DI MEDICINA DI PRECISIONE
Sezione Scientifica di Diagnostica per Immagini



CAD

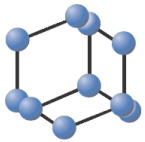
```
graph TD; CAD[CAD] --- A[studio anatomico]; CAD --- B[valutazione funzionale]; B --- C[FFR-CT]
```

studio
anatomico

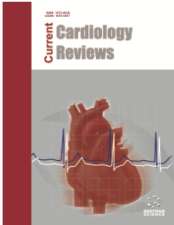valutazione
funzionale

FFR-CT



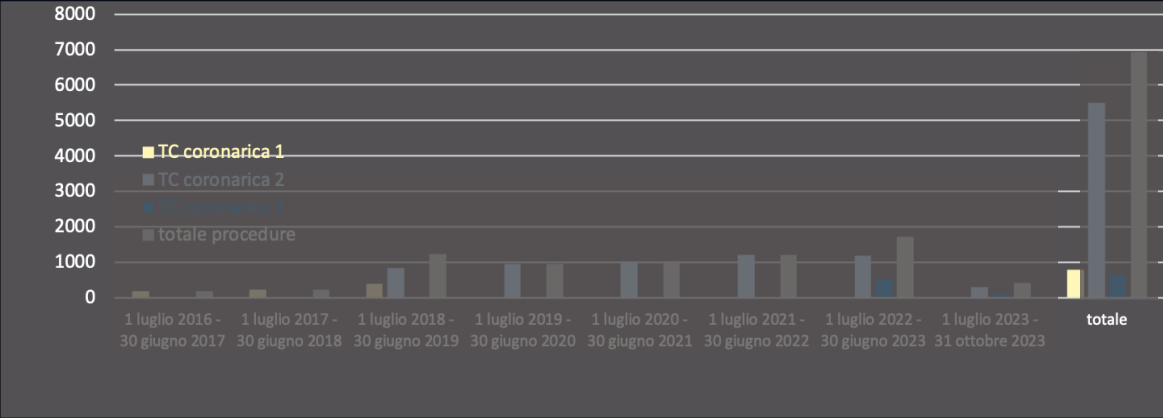
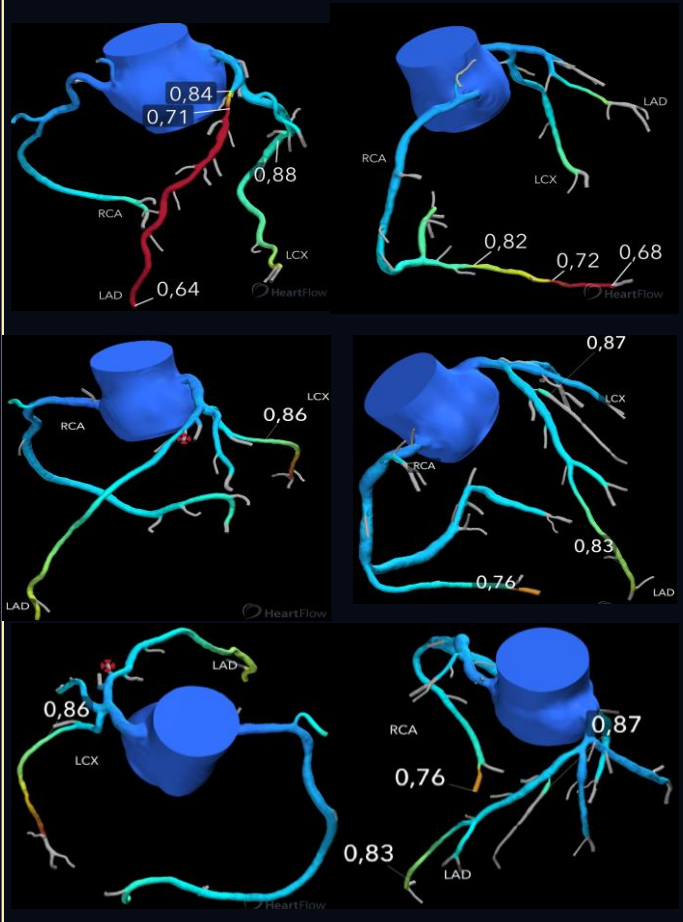


Is it the Time to Move Towards Coronary Computed Tomography Angiography-Derived Fractional Flow Reserve Guided Percutaneous Coronary Intervention? The Pros and Cons



Mohammadbagher Sharifkazemi¹, Zahra Hooshanginezhad¹, Arezou Zoroufian² and Kamran Shamsa^{3,*}

$$p \frac{\partial u}{\partial t} + p(u \cdot \nabla u) + \nabla p - 2u \nabla \varepsilon(u) = 0$$



- post-processing calculation
- lack of global access to calculation
- blood characteristics
- image quality
- artifacts
- misalignment
- motion artifact
- beam hardening
- image noise

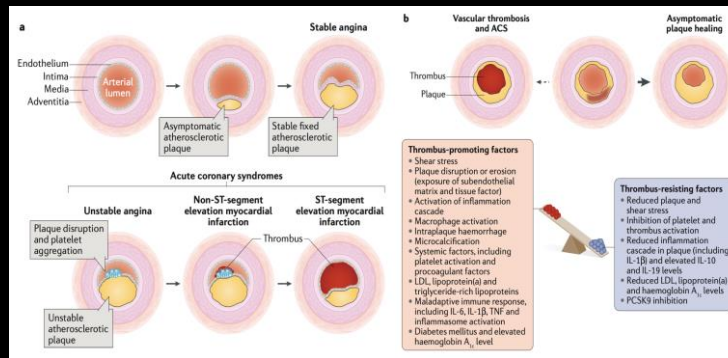
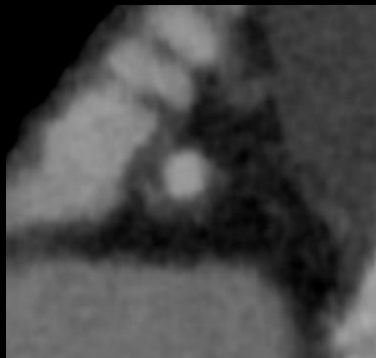


CAD

studio
anatomico


valutazione
funzionale

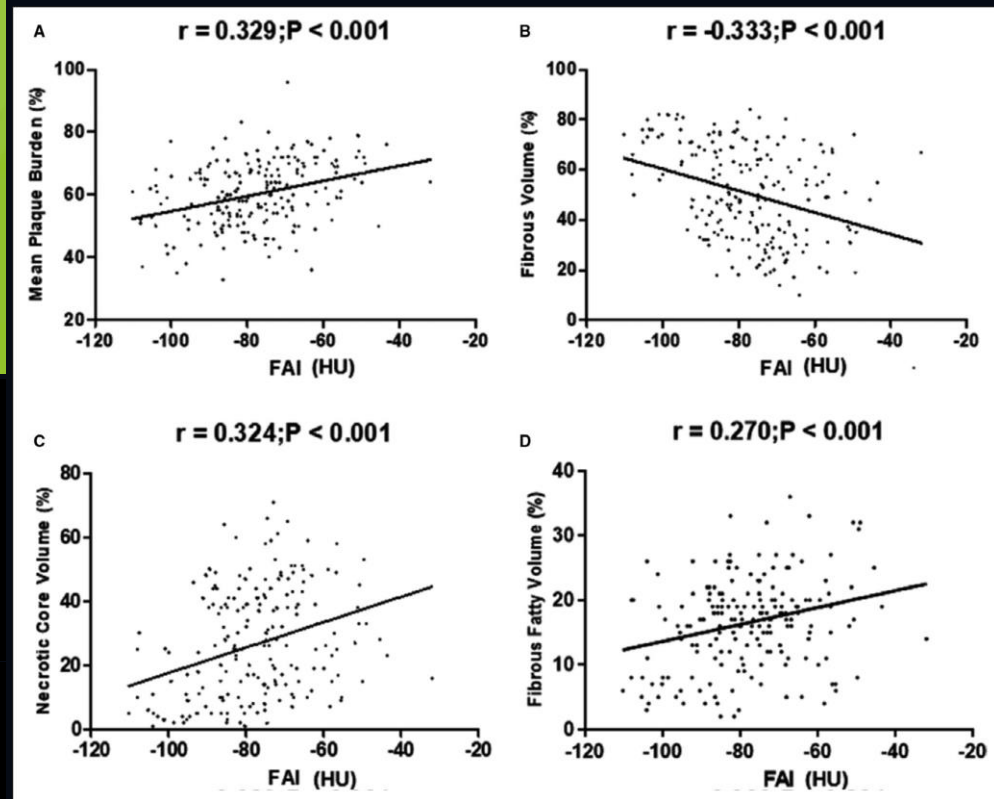
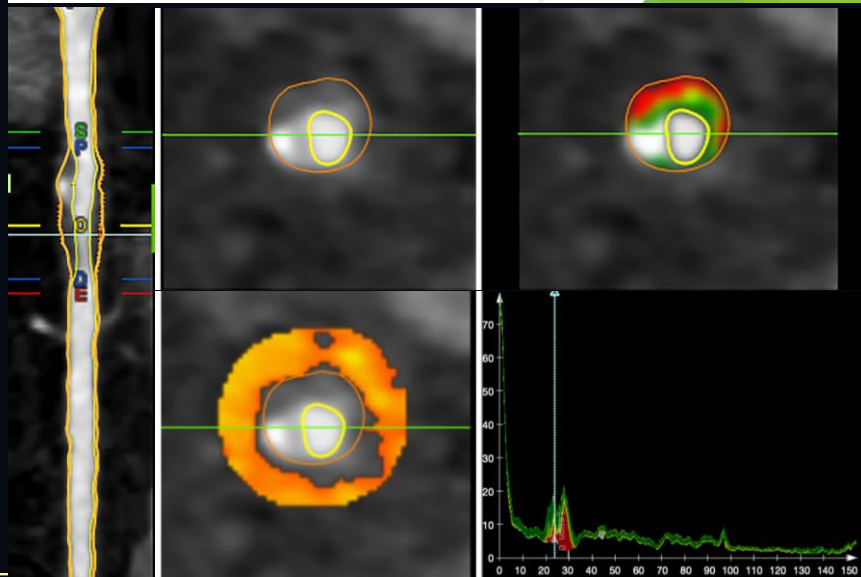
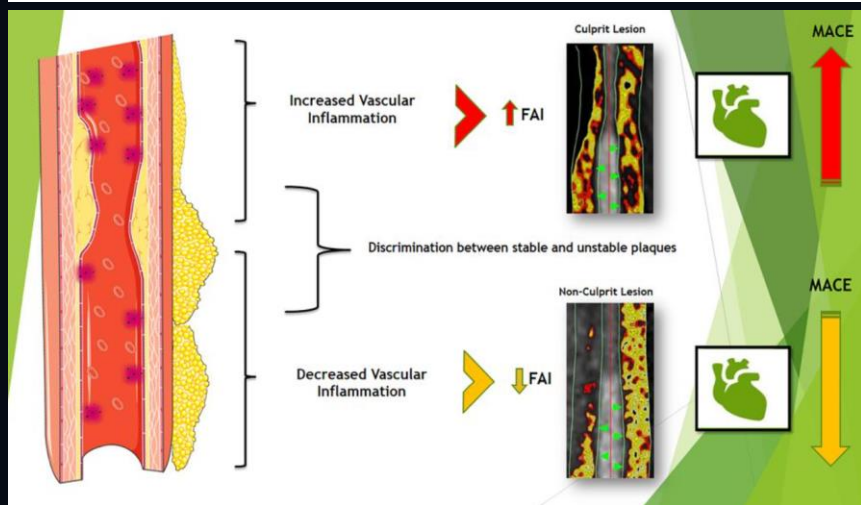
FFR-CT



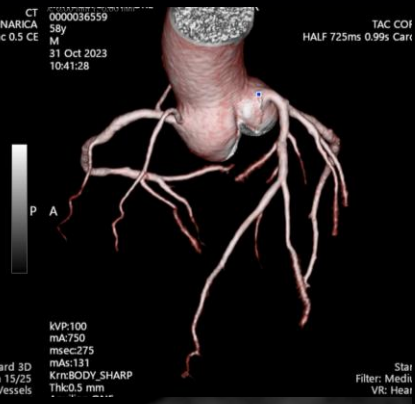
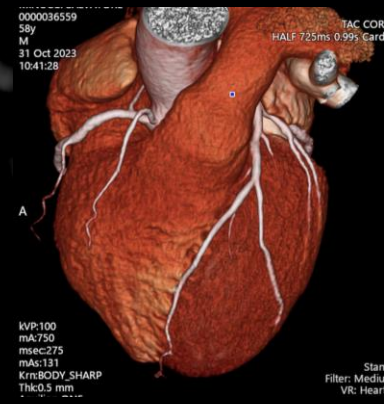
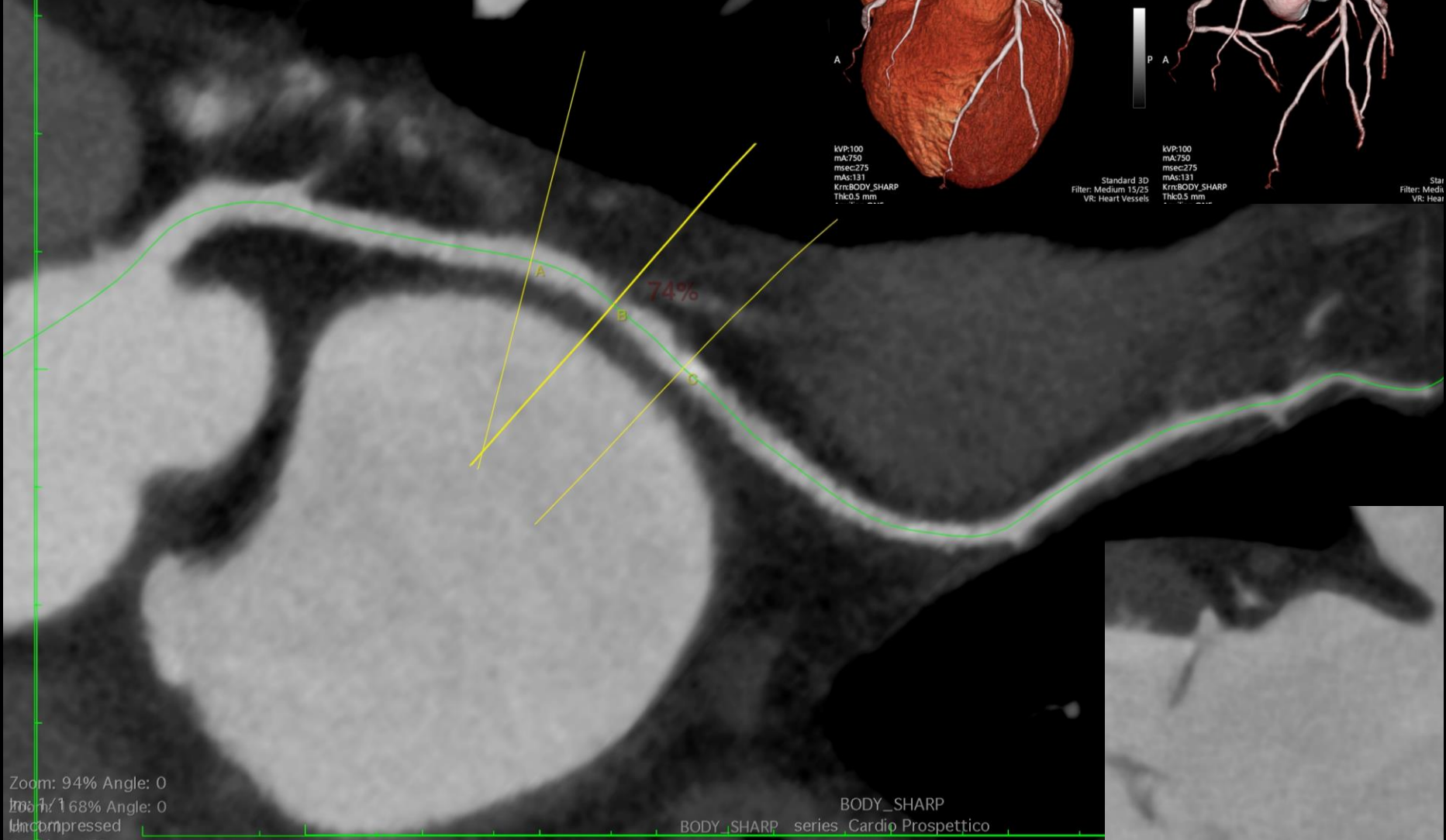
ORIGINAL RESEARCH

Pericoronary Fat Attenuation Index Is Associated With Vulnerable Plaque Components and Local Immune-Inflammatory Activation in Patients With Non-ST Elevation Acute Coronary Syndrome

Jia Teng Sun, MD, PhD*; Xin Cheng Sheng, MD*; Qi Feng, MD, PhD; Yan Yin, MD, PhD; Zheng Li, MD; Song Ding , MD, PhD; Jun Pu, MD, PhD



View size: 23362x19849
WL: 188 WW: 1278
A-B: 0.81 cm
B-C: 0.81 cm
A-C: 1.61 cm



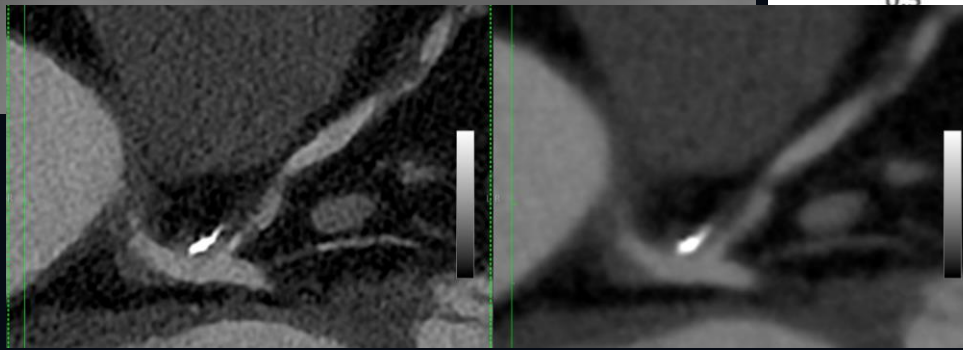
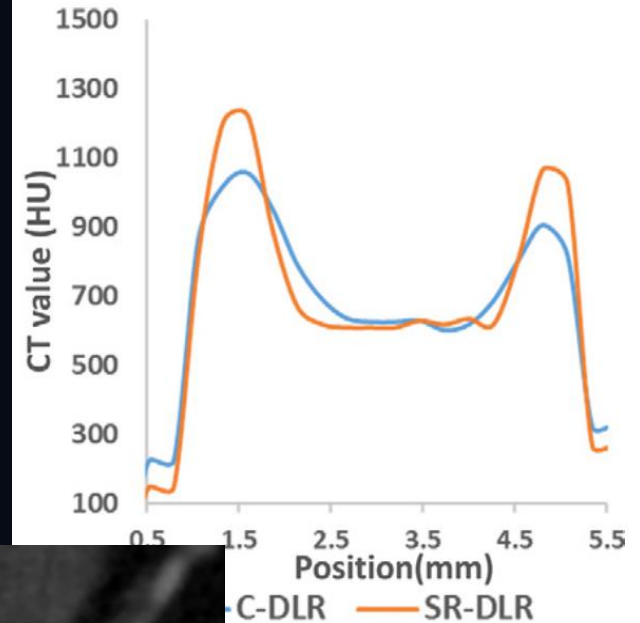


Zoom: 94% Angle: 0
1/168% Angle: 0
Uncompressed

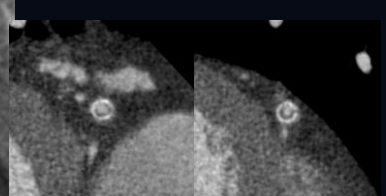
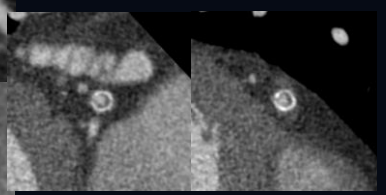
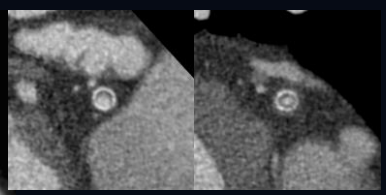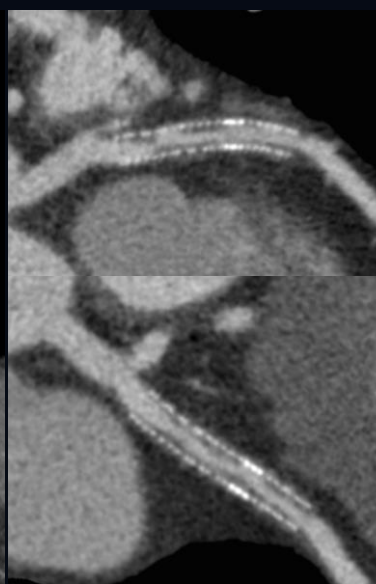
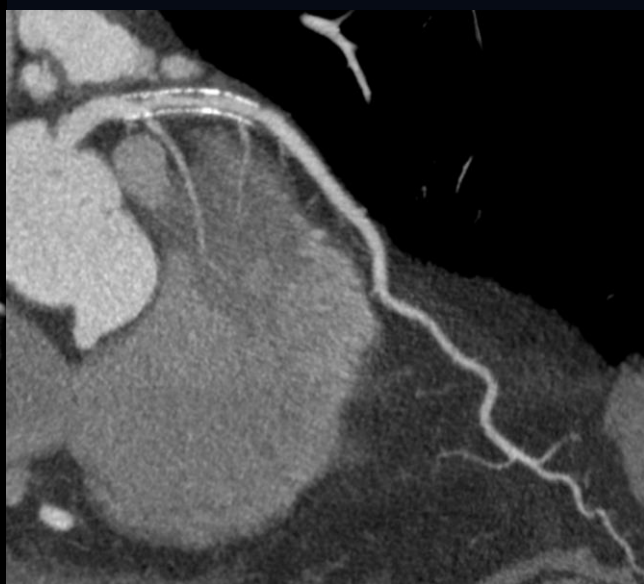
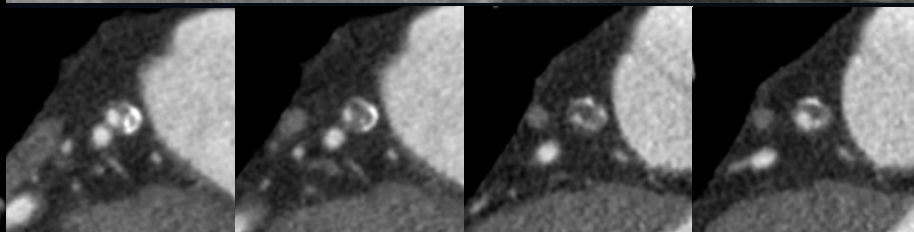
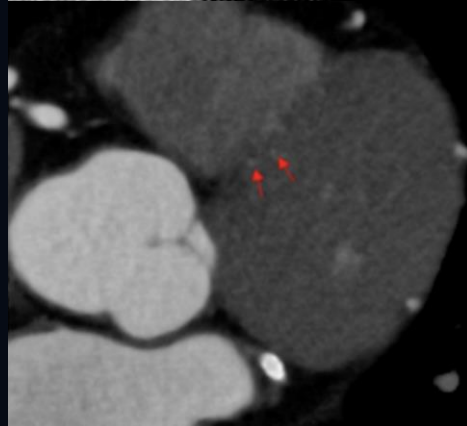
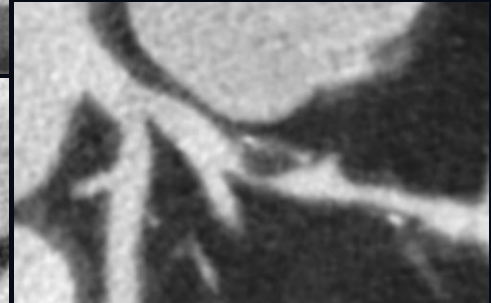
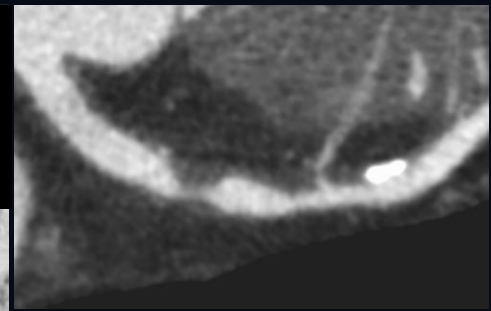
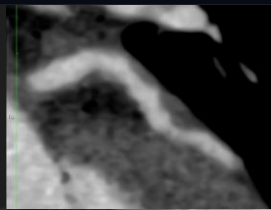
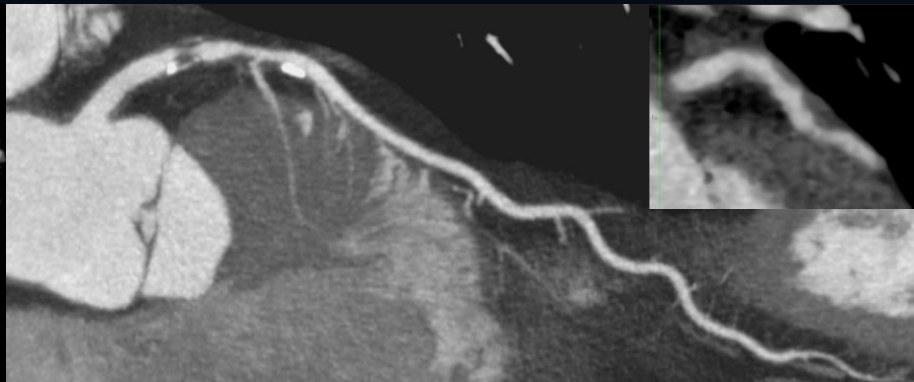
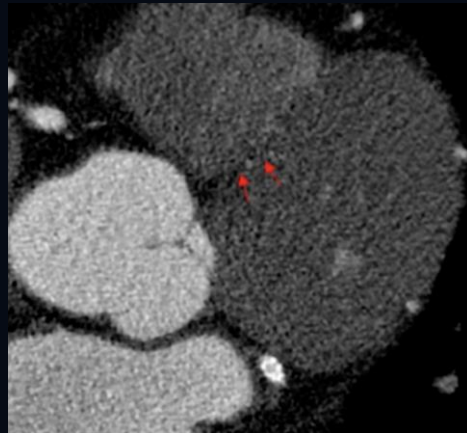
BODY_SHARP series Cardio Prospettico

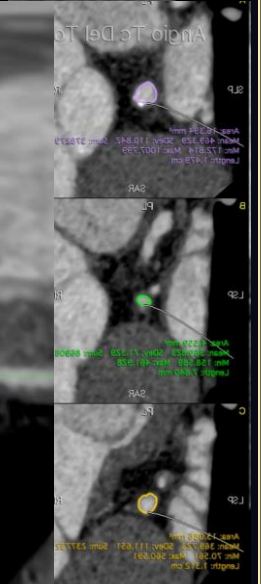
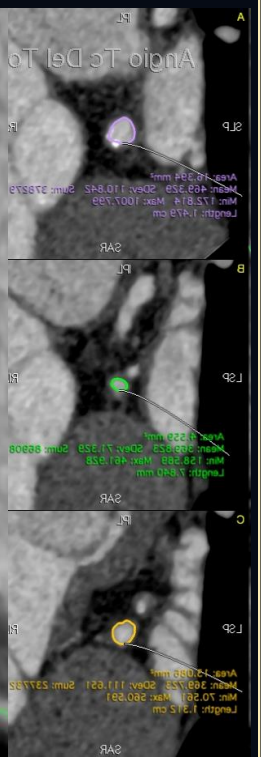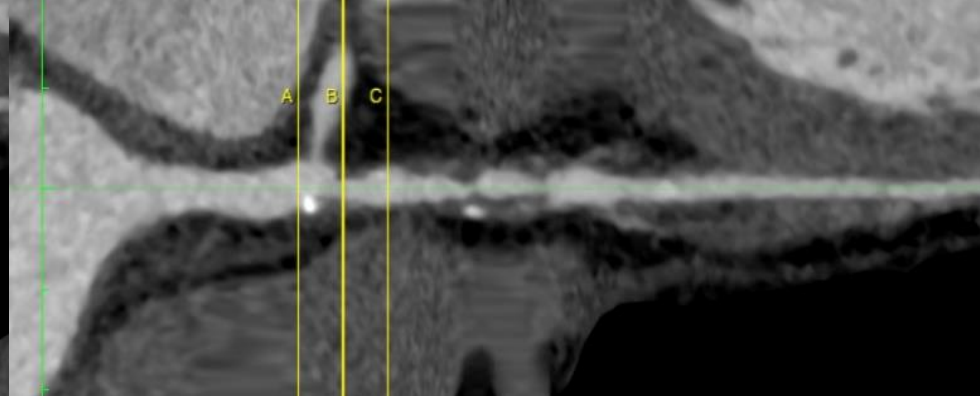
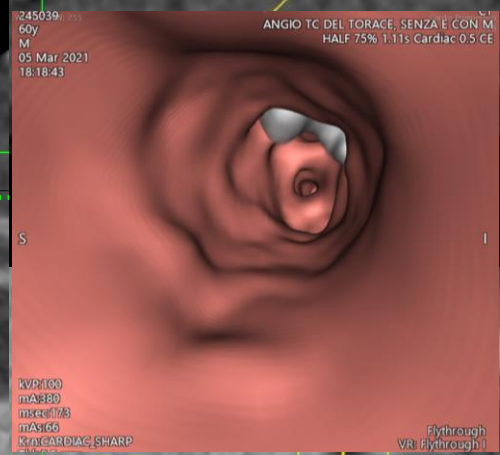
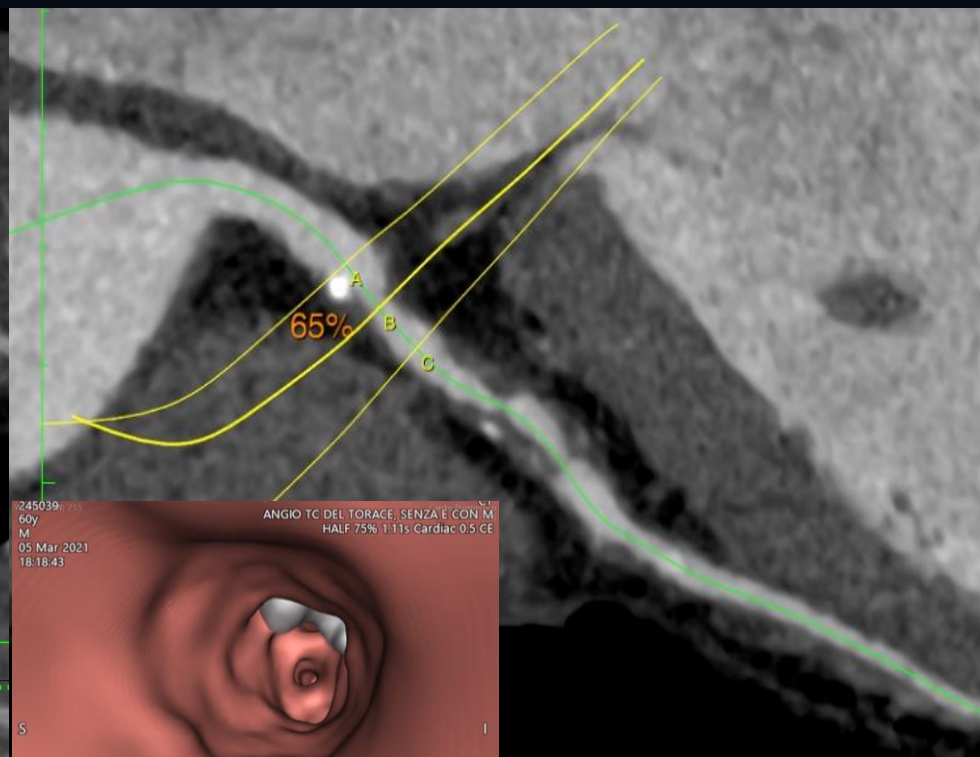
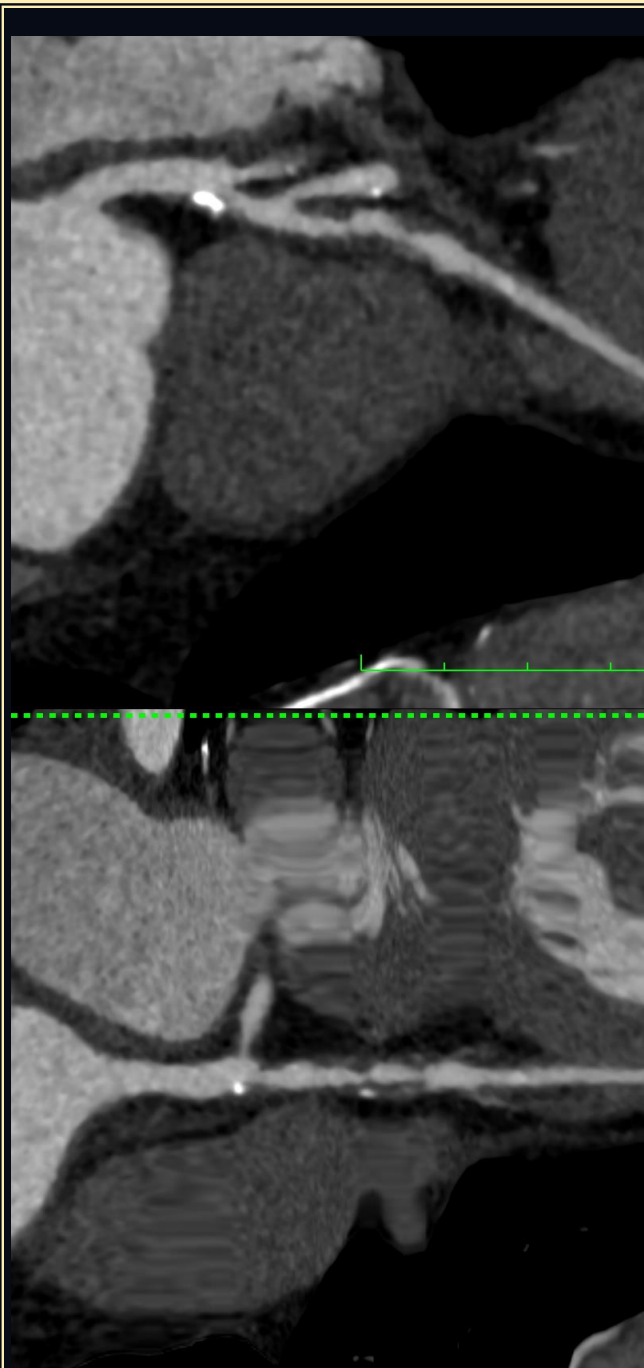


Super-Resolution Deep Learning Reconstruction for Improved Image Quality of Coronary CT Angiography

Masafumi Takafuji, MD, PhD • Kakuya Kitagawa, MD, PhD • Sachio Mizutani, RT • Akane Hamaguchi, RT • Ryosuke Kisou, RT • Kotaro Iio, MD • Kazuhide Ichikawa, MD • Daisuke Izumi, MD • Hajime Sakuma, MD, PhD







CARATTERIZZAZIONE PLACCA

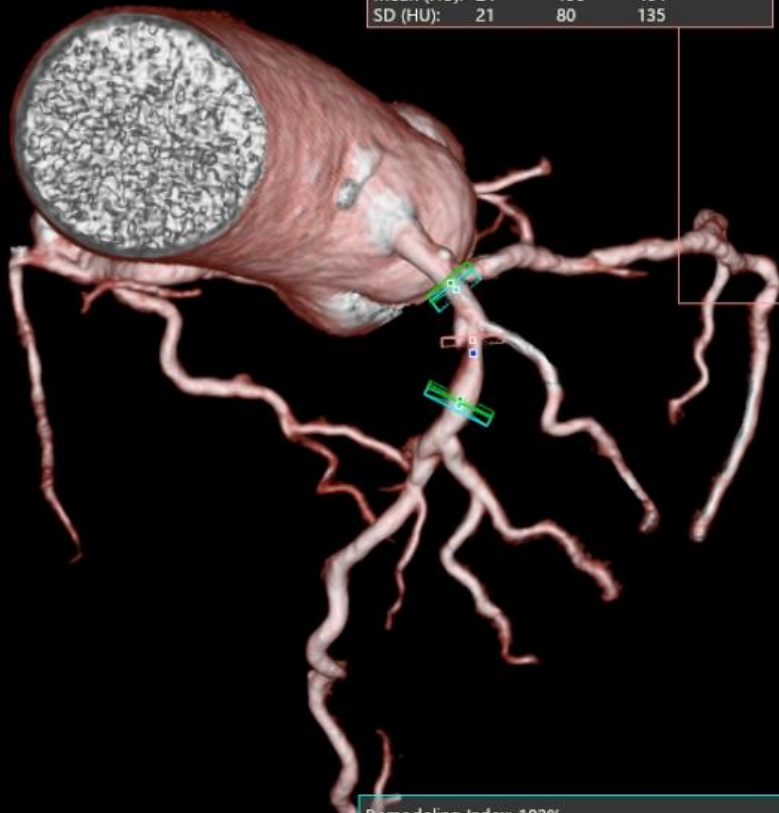27 WW: 255

2023

J

Vessel Area: 25.0mm²
 Wall/Lumen Ratio (Area): 1122.4%
 Plaque burden: 91.8%

	Plaque1	Plaque2	Calcium	All
	-100:49	50:329	329:1300	
Area (mm ²):	3.6	16.9	2.3	22.8
Area (%):	15.6	74.1	10.3	100
Mean (HU):	24	156	464	
SD (HU):	21	80	135	



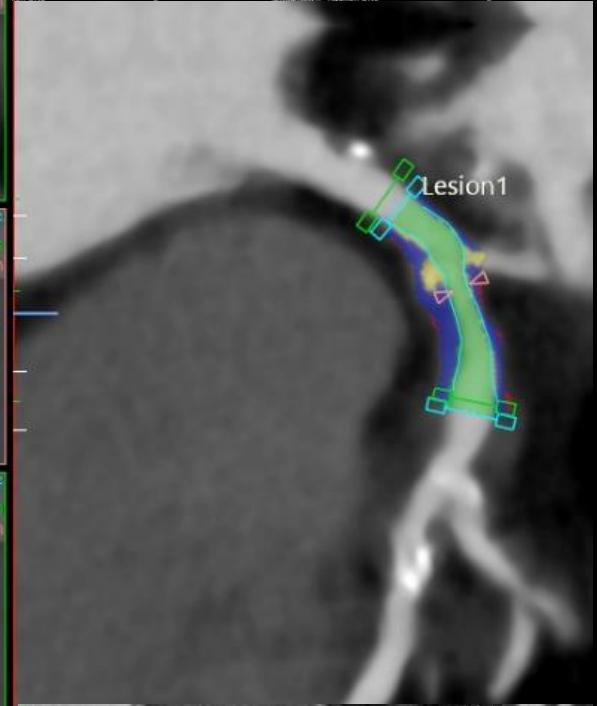
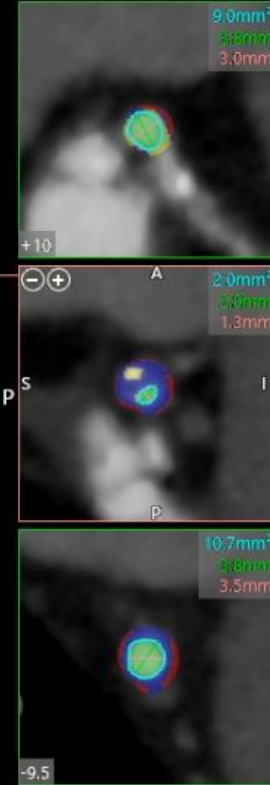
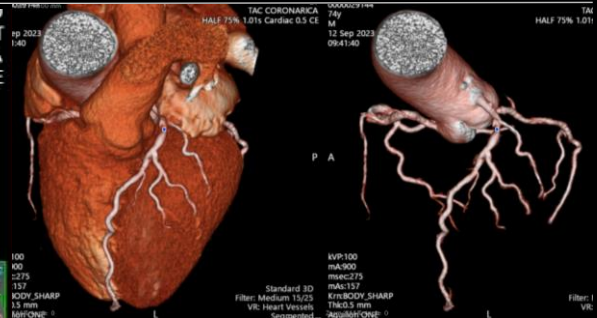
Remodeling Index: 102%
 Vessel Volume: 435.9mm³
 Wall/Lumen Ratio (Volume): 306.4%
 Plaque burden: 75.4%

	Plaque1	Plaque2	Calcium	All
	-100:49	50:329	329:1300	
Volume (mm ³):	64.3	232.4	31.7	328
Volume (%):	19.6	70.8	9.6	100
Mean (HU):	20	146	510	157
SD (HU):	22	72	222	156

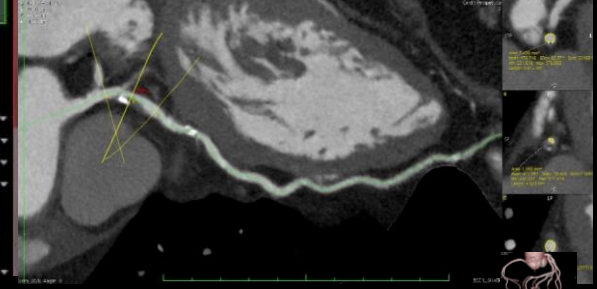
92% Angle: 0

VR_SHARP

IAC CENTRO VOMERO
 CT
 TAC CORONARICA
 HALF 75% 1.01s Cardiac 0.5 CE



Standard 3D
 172%
 Filter: Medium 15/25
 Volume Render
 W/L: 205 150 Vessels
 VR: Heart Vessels
 Segmented
 IAO 169 CRA 00



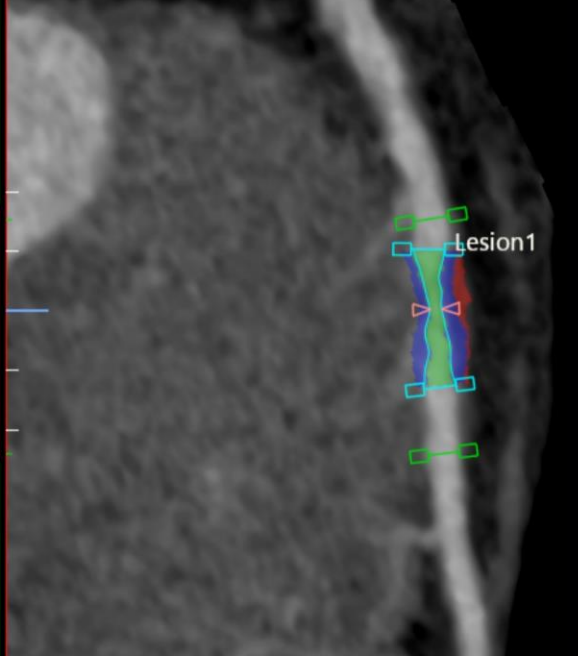
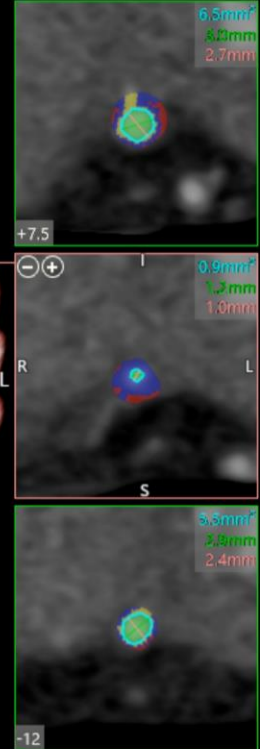
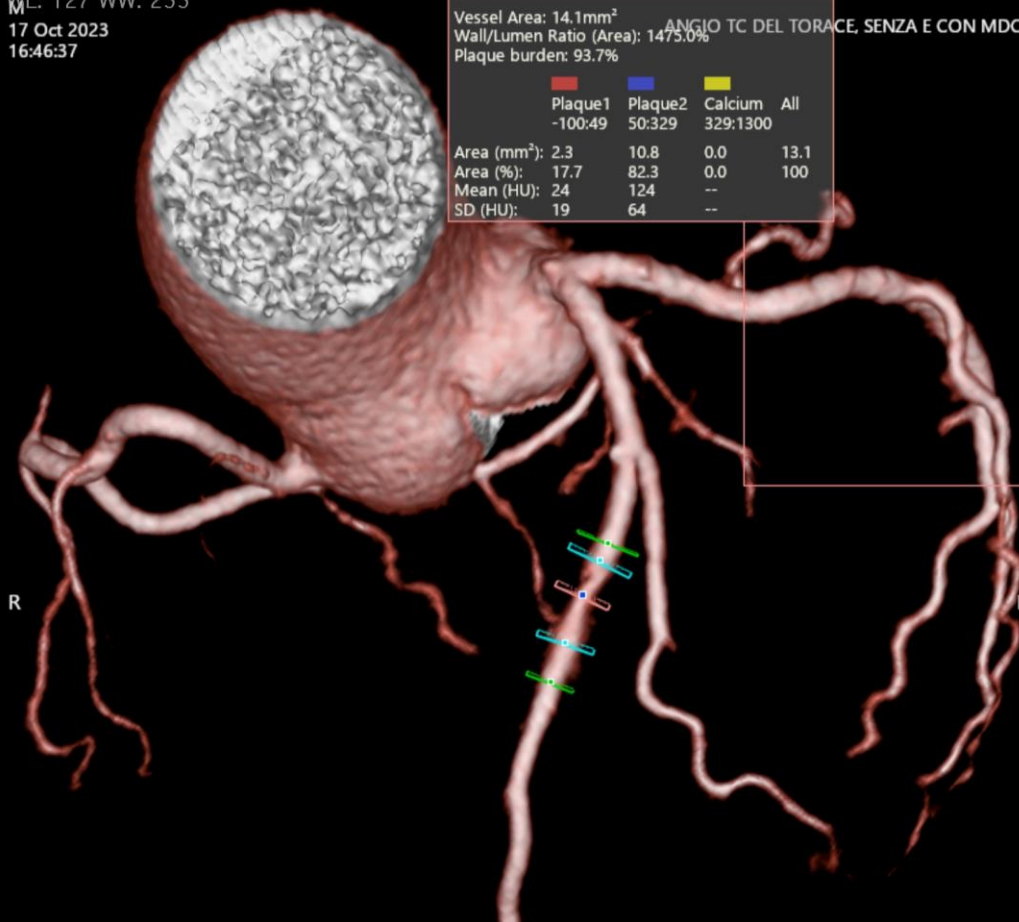
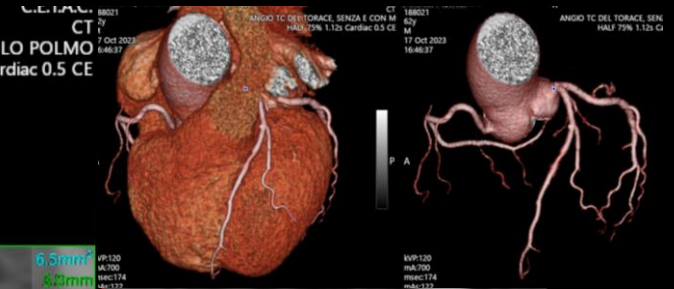
CARATTERIZZAZIONE PLACCA

RAY
ML: 127 WW: 255
17 Oct 2023
16:46:37

ANGIO TC DEL TORACE, SENZA E CON MDC COMPRESO CIRCOLO POLMO
HALF 75% 1.12s Cardiac 0.5 CE

Vessel Area: 14.1mm²
Wall/Lumen Ratio (Area): 1475.0%
Plaque burden: 93.7%

	Plaque1	Plaque2	Calcium	All
	-100:49	50:329	329:1300	
Area (mm ²):	2.3	10.8	0.0	13.1
Area (%):	17.7	82.3	0.0	100
Mean (HU):	24	124	--	
SD (HU):	19	64	--	

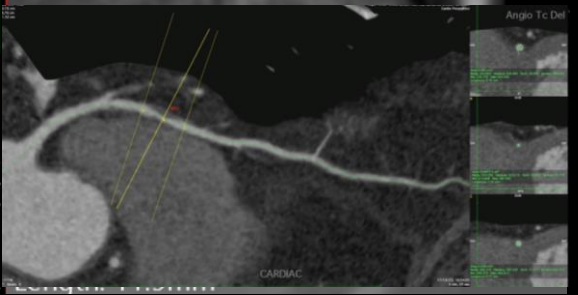


Remodeling Index: 87%
Vessel Volume: 207.2mm³
Wall/Lumen Ratio (Volume): 580.4%
Plaque burden: 85.3%

	Plaque1	Plaque2	Calcium	All
	-100:49	50:329	329:1300	
Volume (mm ³):	35.7	140.8	0.2	177
Volume (%):	20.2	79.7	0.1	100
Mean (HU):	20	136	348	112
SD (HU):	25	63	11	74

kVP:120
mA:700
mAs:174 90% Angle: 0
mAs:122
kVr:CARDIAC

Standard 3D 215%
Volume Render W/L: 205 150 Vessels
VR: Heart Vessels
Segmented
RAO 12 CRA 73



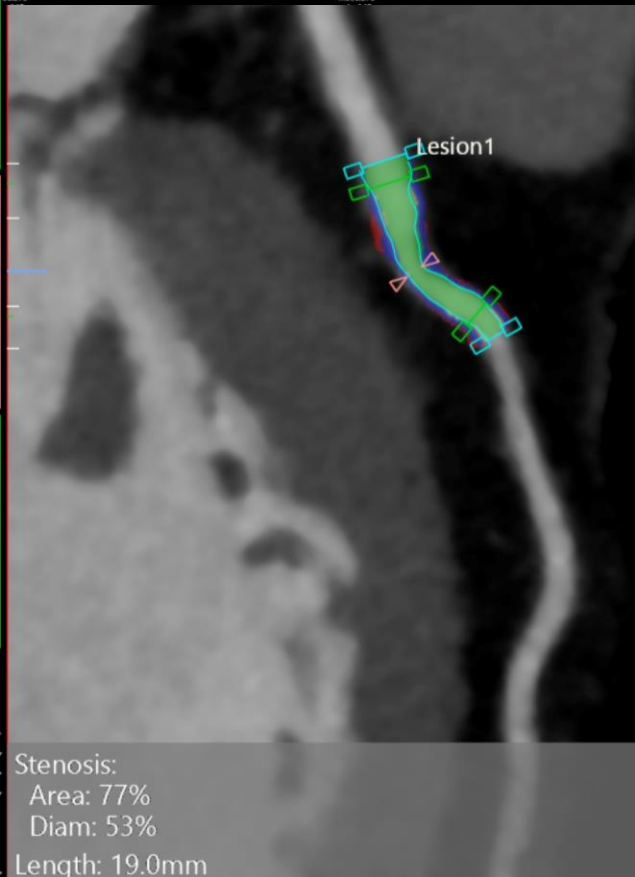
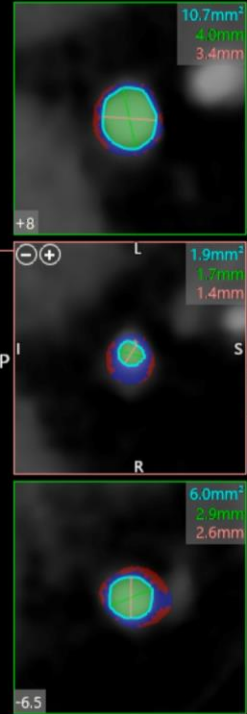
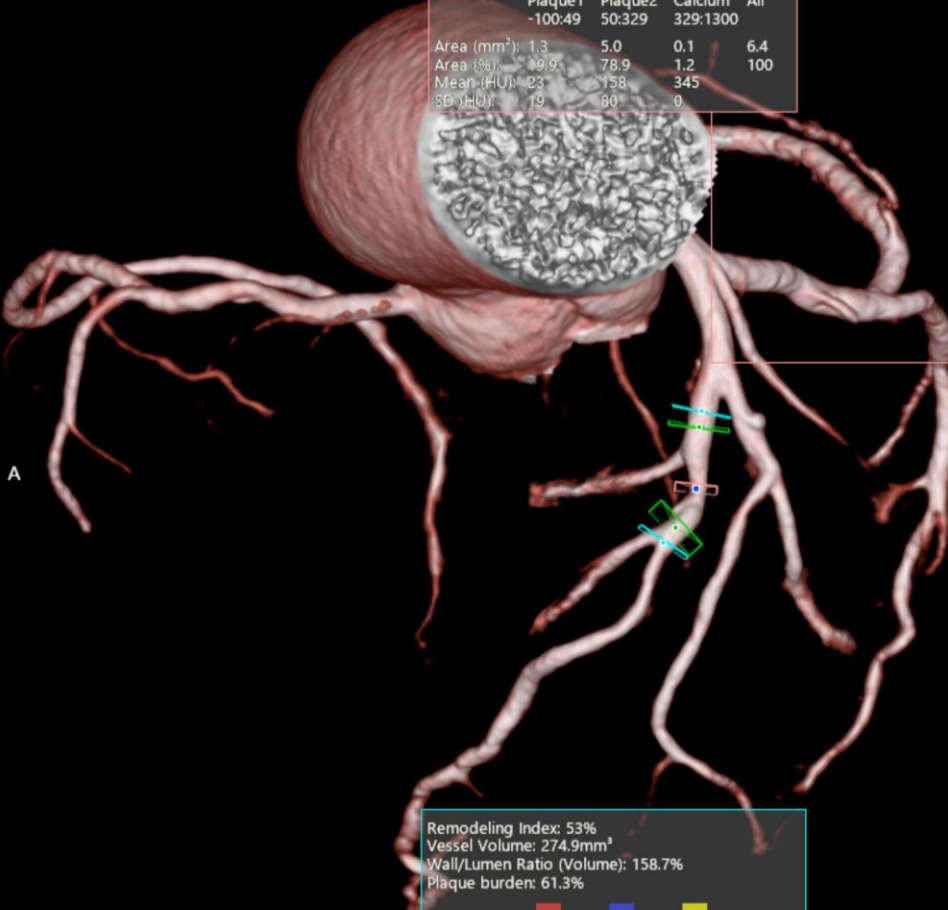
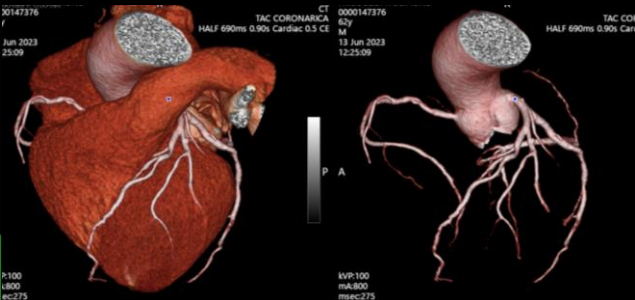
CARATTERIZZAZIONE PLACCA

62y
M
127 WW: 255
13 Jun 2023
12:25:09

Vessel Area: 8.3mm²
Wall/Lumen Ratio (Area): 327.0%
Plaque burden: 76.6%

	Plaque1	Plaque2	Calcium	All
	-100:49	50:329	329:1300	
Area (mm ²):	1.3	5.0	0.1	6.4
Area (%):	19.9	78.9	1.2	100
Mean (HU):	23	158	345	
SD (HU):	79	80	0	

IAC CENTRO VOMEKU 20147376
CT
TAC CORONARICA
Jun 2023
25:09
HALF 690ms 0.90s Cardiac 0.5 CE



Remodeling Index: 53%
Vessel Volume: 274.9mm³
Wall/Lumen Ratio (Volume): 158.7%
Plaque burden: 61.3%

	Plaque1	Plaque2	Calcium	All
	-100:49	50:329	329:1300	
Volume (mm ³):	46.9	105.2	16.6	169
Volume (%):	27.8	62.4	9.8	100
Mean (HU):	9	157	386	139
SD (HU):	29	78	38	123

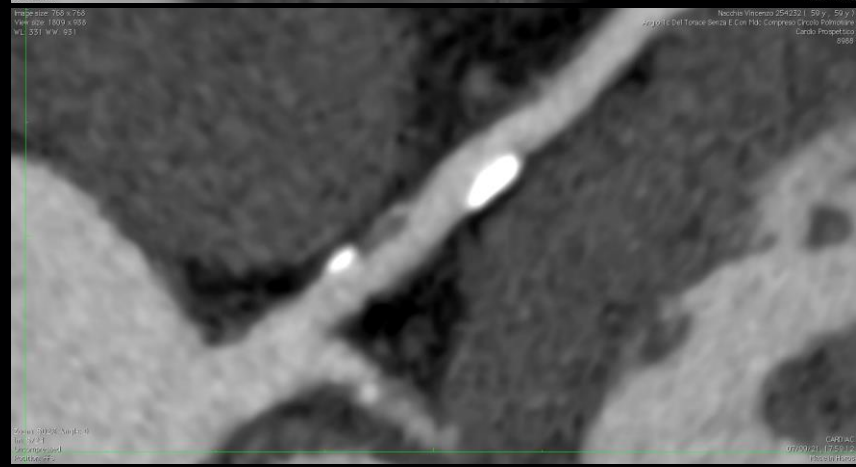
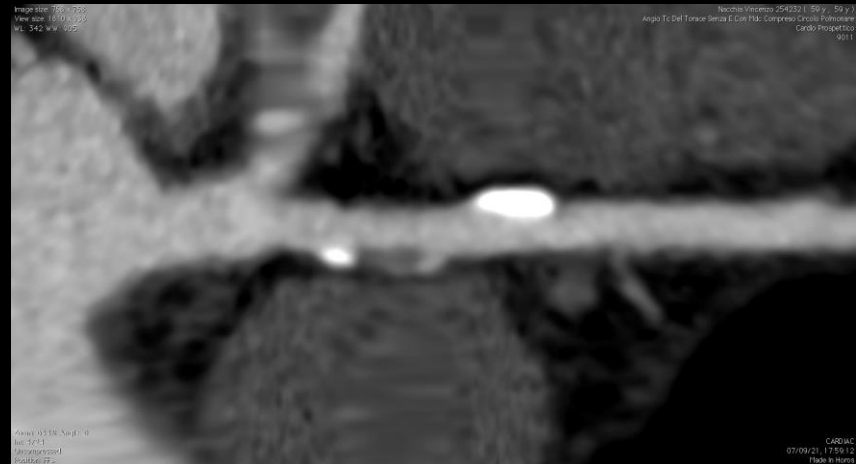
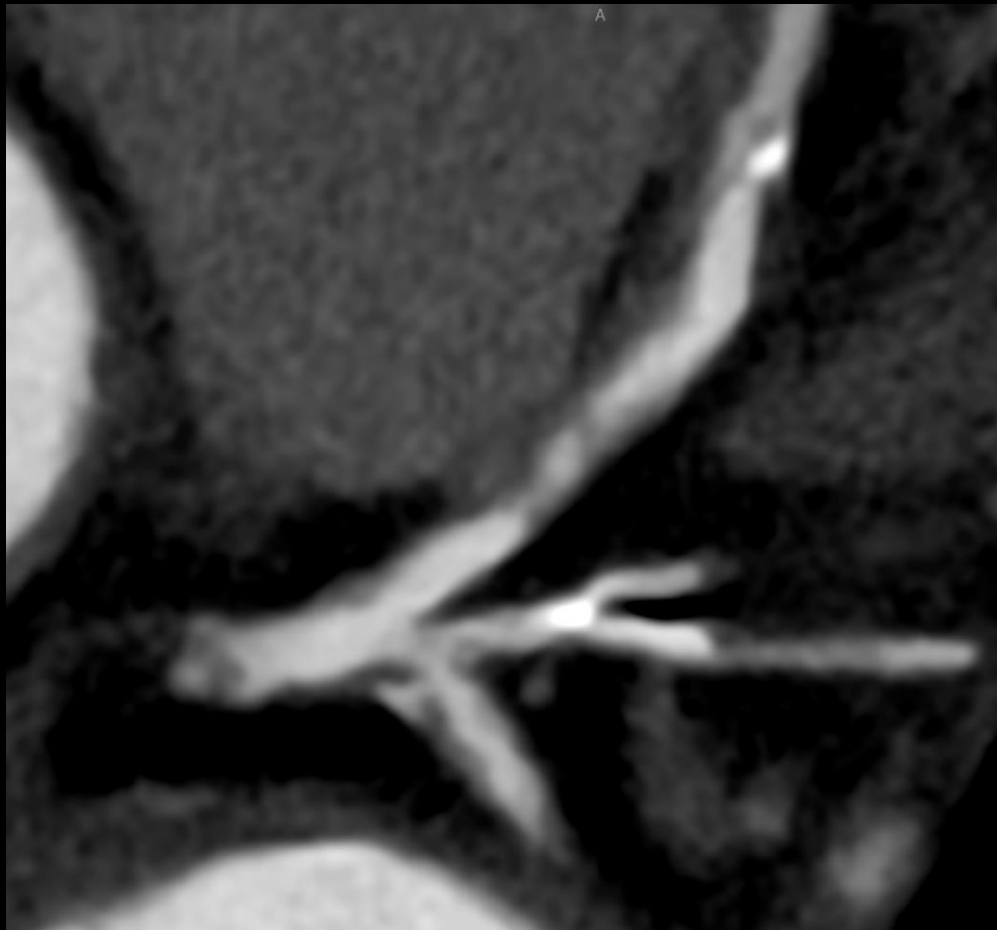
Standard 3D
219%
Filter: Medium 15/25
Volume Render
W/L: 205 150 Vessels
VR: Heart Vessels
Segmented
RAO 44 CRA 76

Stenosis:
Area: 77%
Diam: 53%
Length: 19.0mm

kVP:100
mA:800
msec:275
90% Angle: 0
mAs:140
Krn:BODY_SHARP

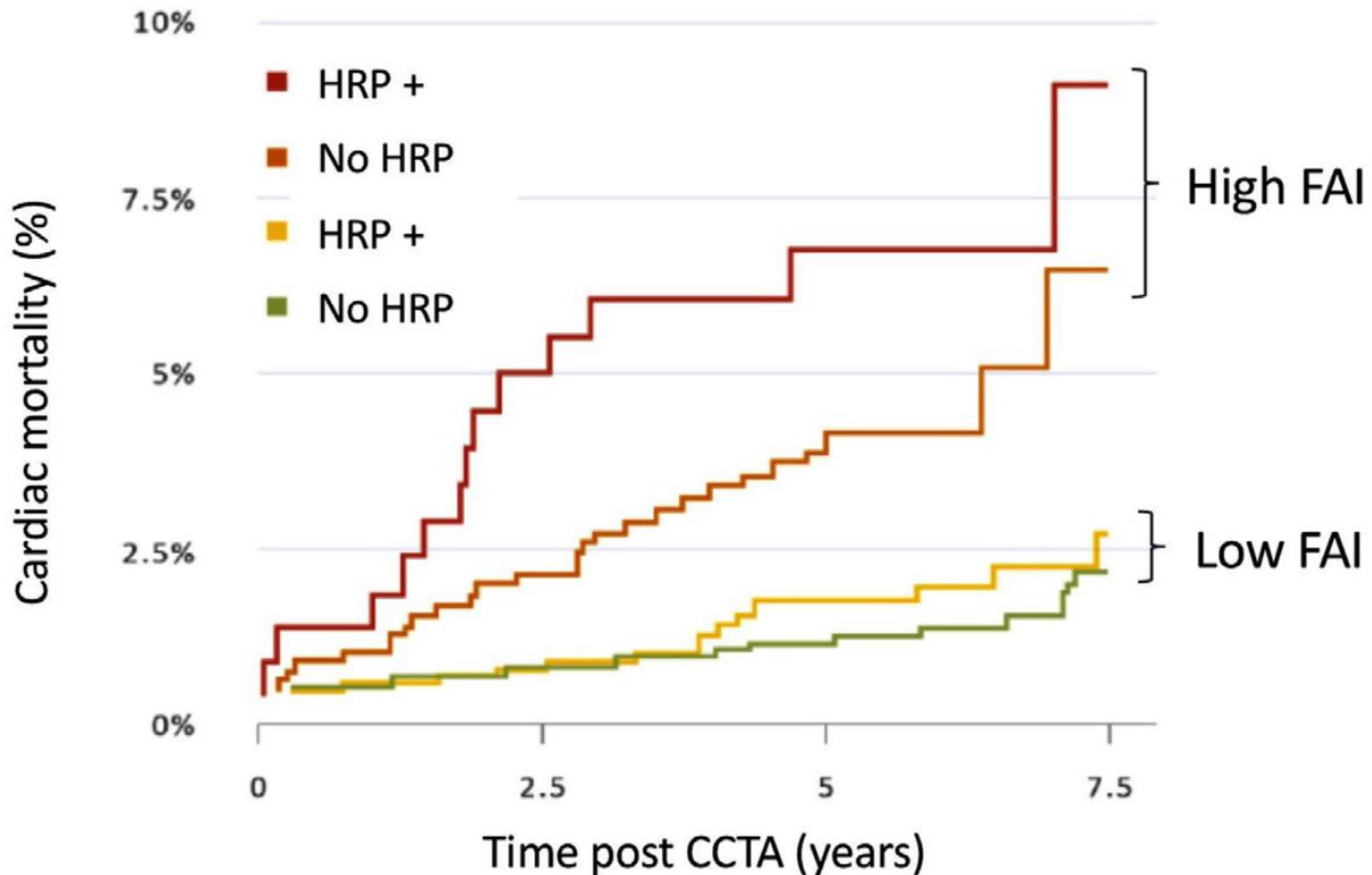


CARATTERIZZAZIONE PLACCA

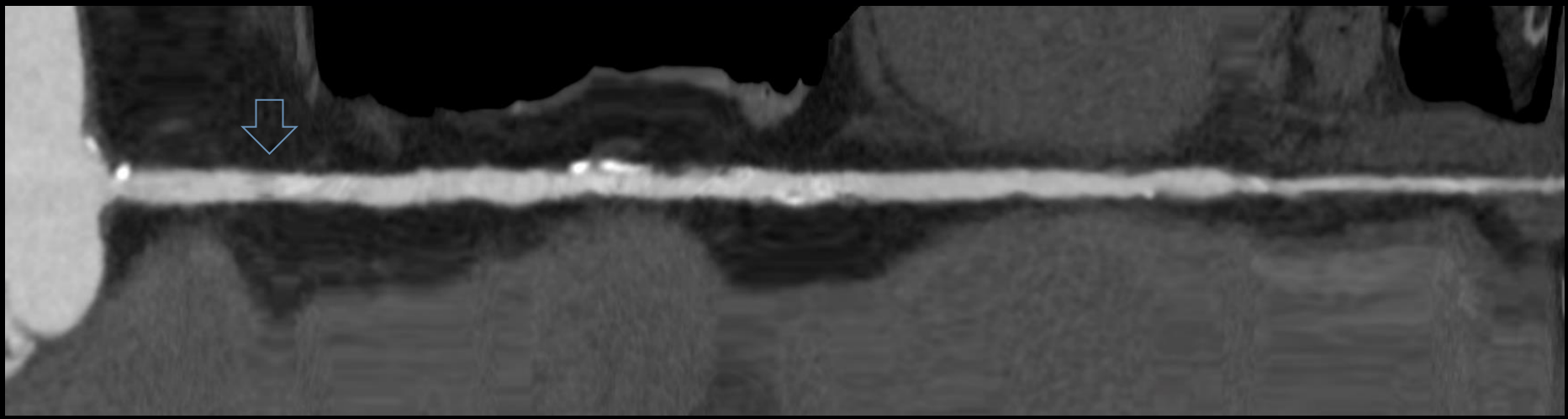
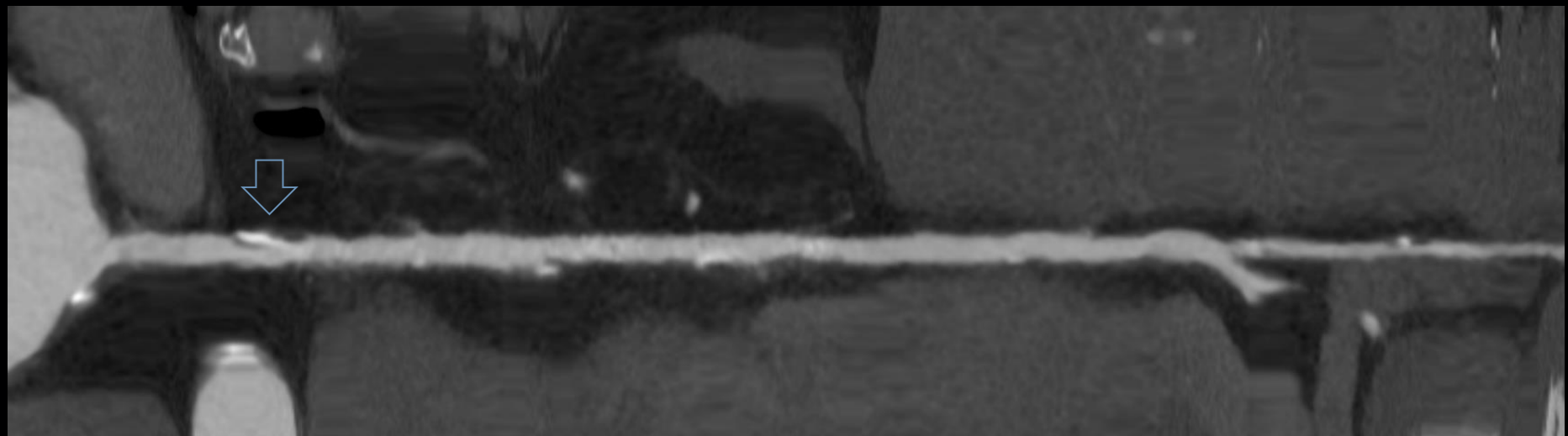


Cardiovascular computed tomography imaging for coronary artery disease risk: plaque, flow and fat

Channon KM, et al. *BMJ - Heart* 2022;0:1-6



QUANTIZZAZIONE STENOSI



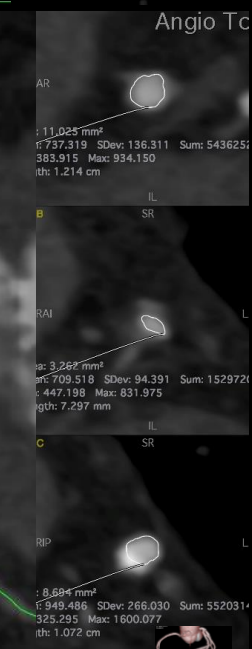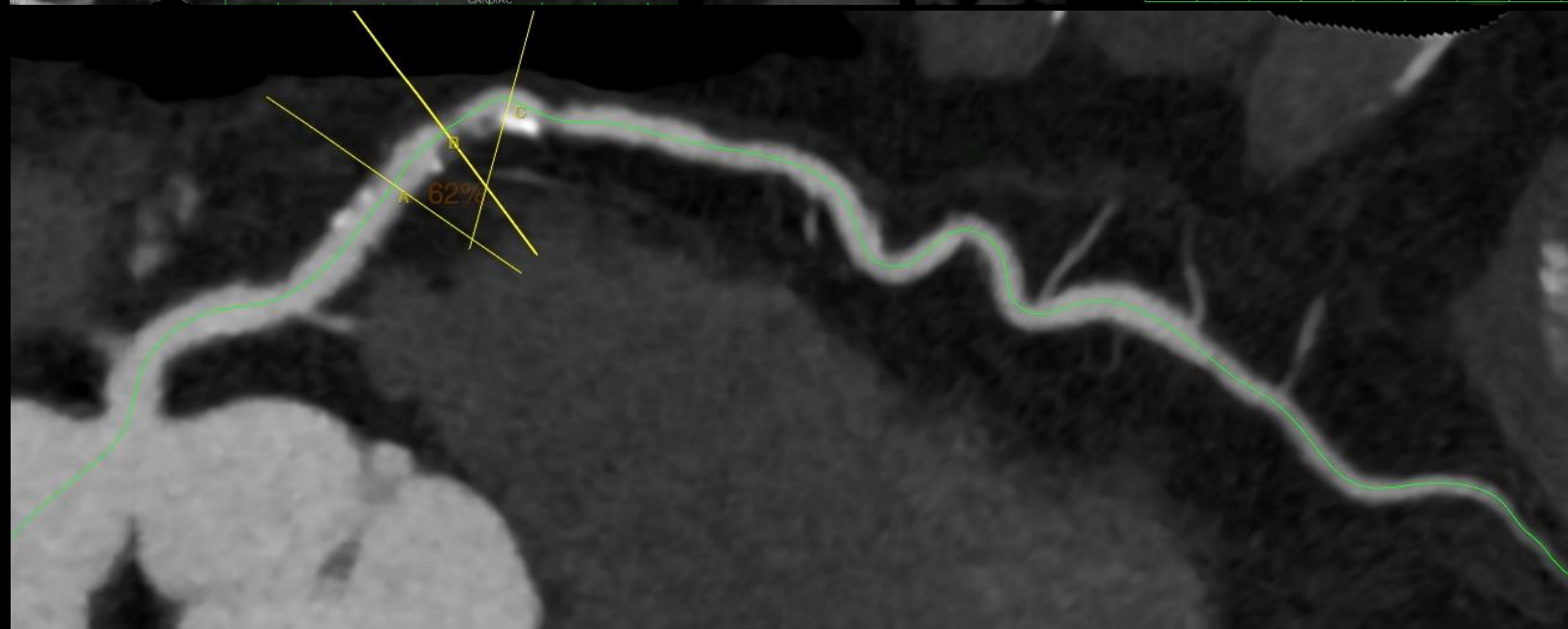
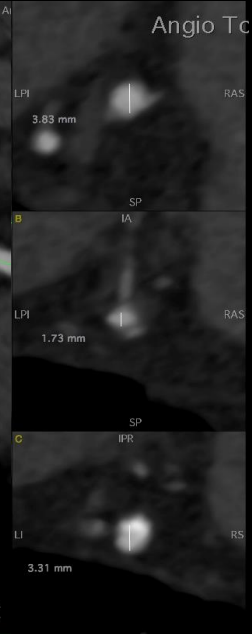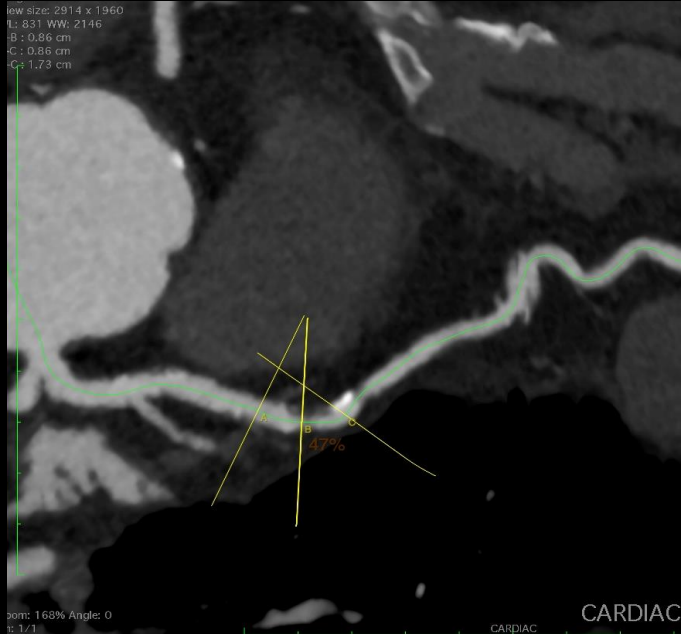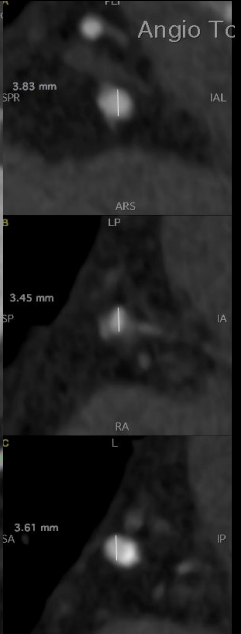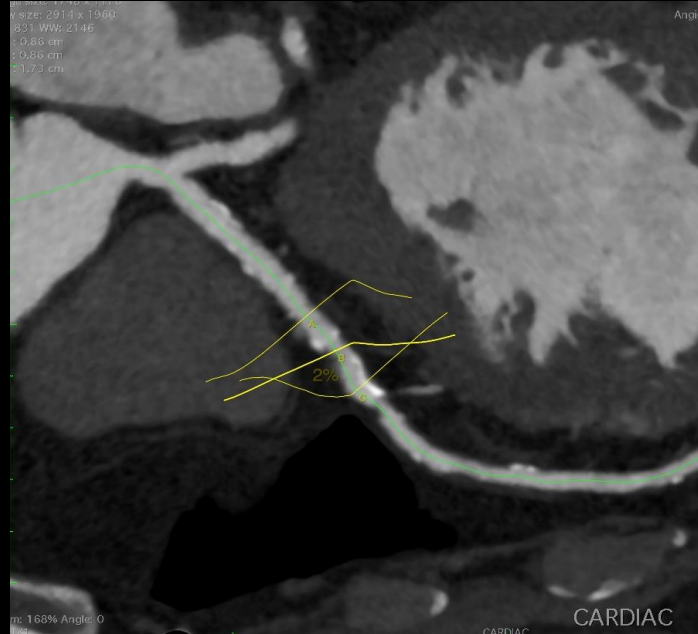x-rays



x-rays



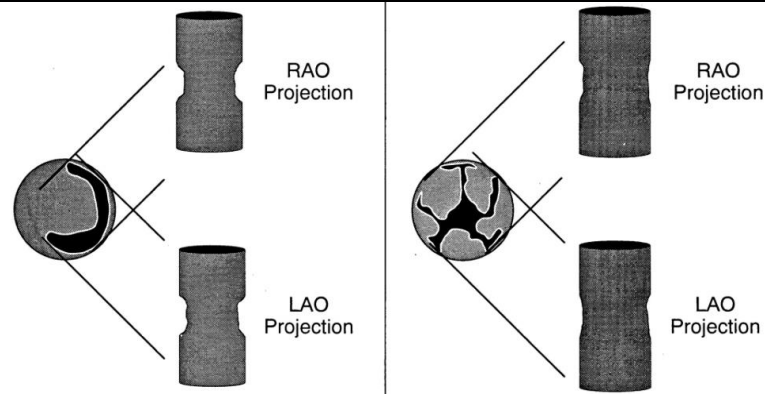
QUANTIZZAZIONE STENOSI



Our Preoccupation With Coronary Luminology

The Dissociation Between Clinical and Angiographic Findings in Ischemic Heart Disease

Eric J. Topol and Steven E. Nissen



Circulation



Volume 92, Issue 8, 15 October 1995; Pages 2333-2342

CORONAROGRAFIA INVASIVA

UN'ALTERNATIVA ALLA T.C. CORONARICA?

