L'imaging nell'endocardite infettiva

Dr. Fabio Marsico, Dirigente Medico I Livello AORN Cardarelli, Napoli

Dimensione del problema

L’endocardite infettiva è una patologia ad elevata mortalità

Nonostante i miglioramenti nella diagnosi e terapia, persiste un’elevate mortalità con complicanze anche severe

L’incidenza di endocardite è quasi raddoppiata negli ultimi 20 anni in Europa

Pertanto la prevenzione gioca un ruolo chiave

Heart 2021;8:e001846e

Profilassi

Table 3 **Cardiac conditions at highest risk of infective endocarditis for which prophylaxis should be considered when a high-risk procedure is performed**

Recommendations	Class[a]	Level[b]
Antibiotic prophylaxis should be considered for patients at highest risk for IE: (1) Patients with any prosthetic valve, including a transcatheter valve, or those in whom any prosthetic material was used for cardiac valve repair. (2) Patients with a previous episode of IE. (3) Patients with CHD: (a) Any type of cyanotic CHD. (b) Any type of CHD repaired with a prosthetic material, whether placed surgically or by percutaneous techniques, up to 6 months after the procedure or lifelong if residual shunt or valvular regurgitation remains.	IIa	C
Antibiotic prophylaxis is not recommended in other forms of valvular or CHD.	III	C

Table 4 **Non-specific prevention measures to be followed in high-risk and intermediate-risk patients**

These measures should ideally be applied to the general population and particularly reinforced in high-risk patients:
• Strict dental and cutaneous hygiene. Dental follow-up should be performed twice a year in high-risk patients and yearly in the others.
• Disinfection of wounds.
• Eradication or decrease of chronic bacterial carriage: skin, urine.
• Curative antibiotics for any focus of bacterial infection.
• No self-medication with antibiotics.
• Strict infection control measures for any at-risk procedure.
• Discourage piercing and tattooing.
• Limit the use of infusion catheters and invasive procedure when possible. Favour peripheral over central catheters, and systematic replacement of the peripheral catheter every 3–4 days. Strict adherence to care bundles for central and peripheral cannulae should be performed.

ESC guidelines

‘Team endocarditi’

When to refer a patient with IE to an ‘Endocarditis Team’ in a reference centre

1. Patients with complicated IE (i.e. endocarditis with HF, abscess, or embolic or neurological complication or CHD), should be referred early and managed in a reference centre with immediate surgical facilities.
2. Patients with non-complicated IE can be initially managed in a non-reference centre, but with regular communication with the reference centre, consultations with the multidisciplinary ‘Endocarditis Team’, and, when needed, with external visit to the reference centre.

Characteristics of the reference centre

1. Immediate access to diagnostic procedures should be possible, including TTE, TOE, multislice CT, MRI, and nuclear imaging.
2. Immediate access to cardiac surgery should be possible during the early stage of the disease, particularly in case of complicated IE (HF, abscess, large vegetation, neurological, and embolic complications).
3. Several specialists should be present on site (the ‘Endocarditis Team’), including at least cardiac surgeons, cardiologists, anaesthesiologists, ID specialists, microbiologists and, when available, specialists in valve diseases, CHD, pacemaker extraction, echocardiography and other cardiac imaging techniques, neurologists, and facilities for neurosurgery and interventional neuroradiology .

Role of the ‘Endocarditis Team’

1. The ‘Endocarditis Team’ should have meetings on a regular basis in order to discuss cases, take surgical decisions, and define the type of follow-up.
2. The ‘Endocarditis Team’ chooses the type, duration, and mode of follow up of antibiotic therapy, according to a standardized protocol, following the current guidelines.
3. The ‘Endocarditis Team’ should participate in national or international registries, publicly report the mortality and morbidity of their centre, and be involved in a quality improvement programme, as well as in a patient education programme.
4. The follow-up should be organized on an outpatient visit basis at a frequency depending on the patient’s clinical status (ideally at 1, 3, 6, and 12 months after hospital discharge, since the majority of events occur during this period[57]).

ESC guidelines

Imaging nell'endocardite infettiva

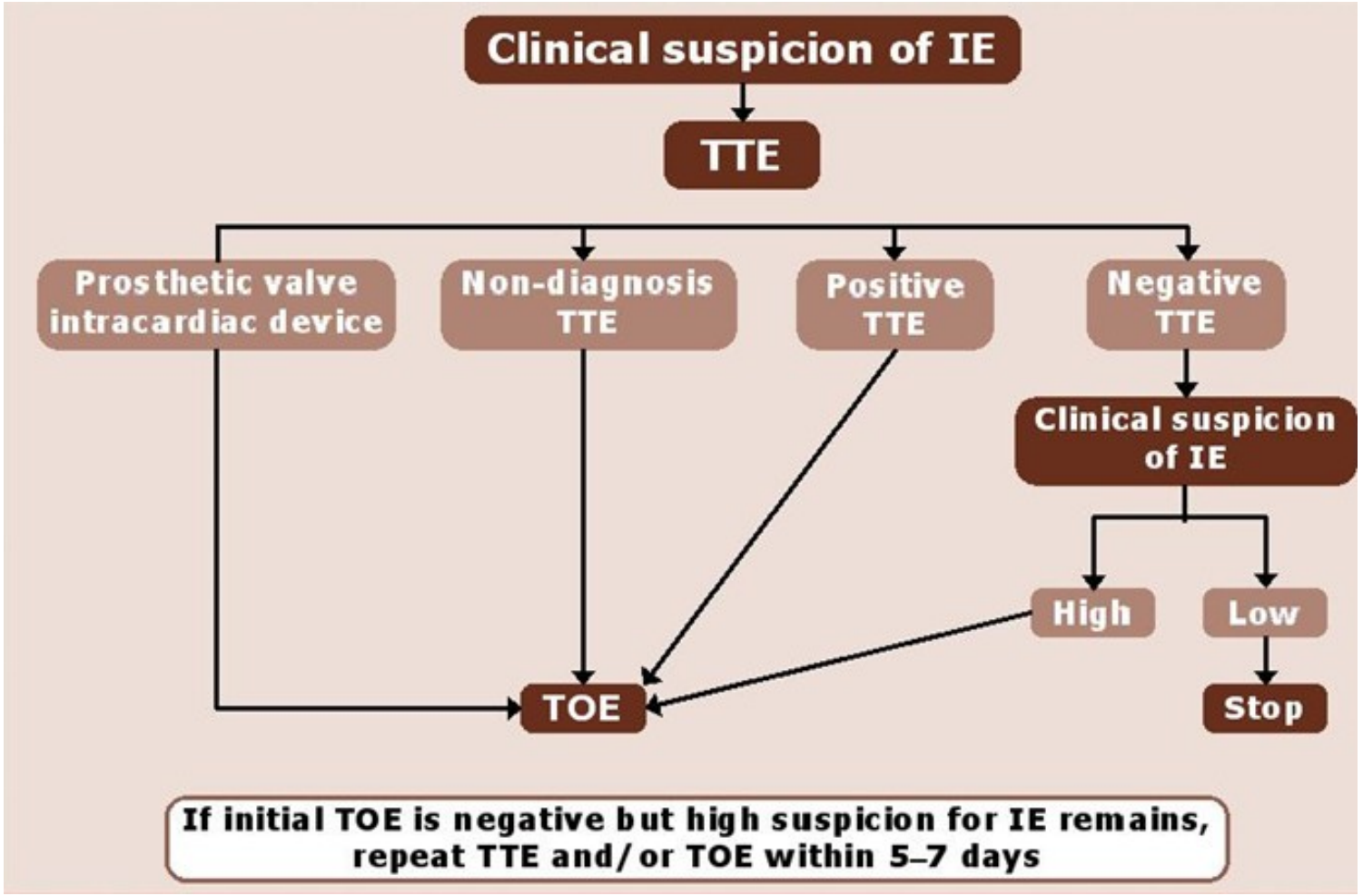

ESC guidelines

Imaging nell'endocardite infettiva

	Surgery/necropsy	Echocardiography
Vegetation	Infected mass attached to an endocardial structure or on implanted intracardiac material.	Oscillating or non-oscillating intracardiac mass on valve or other endocardial structures, or on implanted intracardiac material.
Abscess	Perivalvular cavity with necrosis and purulent material not communicating with the cardiovascular lumen.	Thickened, non-homogeneous perivalvular area with echodense or echolucent appearance.
Pseudoaneurysm	Perivalvular cavity communicating with the cardiovascular lumen.	Pulsatile perivalvular echo-free space, with colour-Doppler flow detected.
Perforation	Interruption of endocardial tissue continuity.	Interruption of endocardial tissue continuity traversed by colour-doppler flow.
Fistula	Communication between two neighbouring cavities through a perforation.	Colour-Doppler communication between two neighbouring cavities through a perforation.
Valve aneurysm	Saccular outpouching of valvular tissue.	Saccular bulging of valvular tissue.
Dehiscence of a prosthetic valve	Dehiscence of the prosthesis.	Paravalvular regurgitation identified by TTE/TOE, with or without rocking motion of the prosthesis.

ESC guidelines

Imaging nell'endocardite infettiva

Recommendations	Class	Level
A. Diagnosis		
TTE is recommended as the first-line imaging modality in suspected IE.	I	B
TOE is recommended in all patients with clinical suspicion of IE and a negative or non-diagnostic TTE.	I	B
TOE is recommended in patients with clinical suspicion of IE, when a prosthetic heart valve or an intracardiac device is present.	I	B
Repeat TTE/TOE within 5–7 days is recommended in case of initially negative examination when clinical suspicion of IE remains high.	I	C
Echocardiography should be considered in *Staphylococcus aureus* bacteraemia.	IIa	B
TOE should be considered in the majority of adult patients with suspected IE, even in cases with positive TTE.	IIa	C

ESC guidelines

Imaging nell'endocardite infettiva

Recommendations	Class	Level
B. Follow-up under medical therapy		
Repeat TTE and/or TOE are recommended as soon as a new complication of IE is suspected (new murmur, embolism, persisting fever, HF, abscess, atrioventricular block).	I	B
Repeat TTE and/or TOE should be considered during follow-up of uncomplicated IE, in order to detect new silent complications and monitor vegetation size. The timing and mode (TTE or TOE) of repeat examination depend on the initial findings, type of microorganism, and initial response to therapy.	IIa	B
C. Intra-operative echocardiography		
Intra-operative echocardiography is recommended in all cases of IE requiring surgery.	I	B
D. Following completion of therapy		
TTE is recommended at completion of antibiotic therapy for evaluation of cardiac and valve morphology and function.	I	C

ESC guidelines

Imaging nell'endocardite infettiva

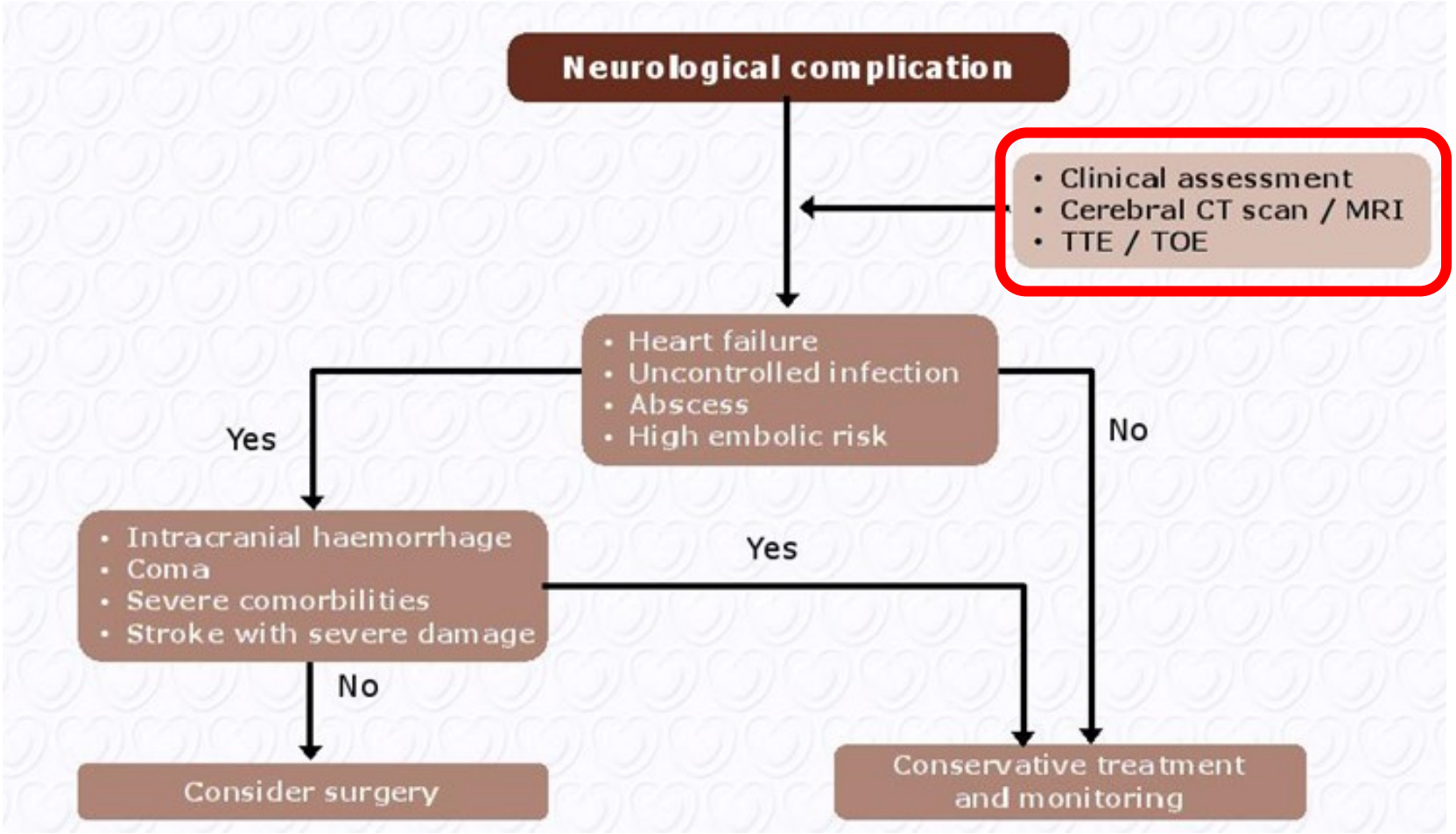

ESC guidelines

Imaging nell'endocardite infettiva

Major criteria

1. Blood cultures positive for IE

a. Typical microorganisms consistent with IE from 2 separate blood cultures:
- *Viridans streptococci, Streptococcus gallolyticus (Streptococcus bovis), HACEK group, Staphylococcus aureus*; or
- Community-acquired enterococci, in the absence of a primary focus; or

b. Microorganisms consistent with IE from persistently positive blood cultures:
- ≥2 positive blood cultures of blood samples drawn >12 h apart; or
- All of 3 or a majority of ≥4 separate cultures of blood (with first and last samples drawn ≥1 h apart); or

c. Single positive blood culture for *Coxiella burnetii* or phase I IgG antibody titre >1:800

2. Imaging positive for IE

a. Echocardiogram positive for IE:
- Vegetation
- Abscess, pseudoaneurysm, intracardiac fistula
- Valvular perforation or aneurysm
- New partial dehiscence of prosthetic valve

b. Abnormal activity around the site of prosthetic valve implantation detected by ^{18}F-FDG PET/CT (only if the prosthesis was implanted for >3 months) or radiolabelled leukocytes SPECT/CT.

c. Definite paravalvular lesions by cardiac CT.

ESC guidelines

Imaging nell'endocardite infettiva

Minor criteria
1. Predisposition such as predisposing heart condition, or injection drug use.
2. Fever defined as temperature >38°C.
3. Vascular phenomena **(including those detected only by imaging)**: major arterial emboli, septic pulmonary infarcts, infectious (mycotic) aneurysm, intracranial haemorrhage, conjunctival haemorrhages, and Janeway's lesions.
4. Immunological phenomena: glomerulonephritis, Osler's nodes, Roth's spots, and rheumatoid factor.
5. Microbiological evidence: positive blood culture but does not meet a major criterion as noted above or serological evidence of active infection with organism consistent with IE.

ESC guidelines

Imaging nell'endocardite infettiva

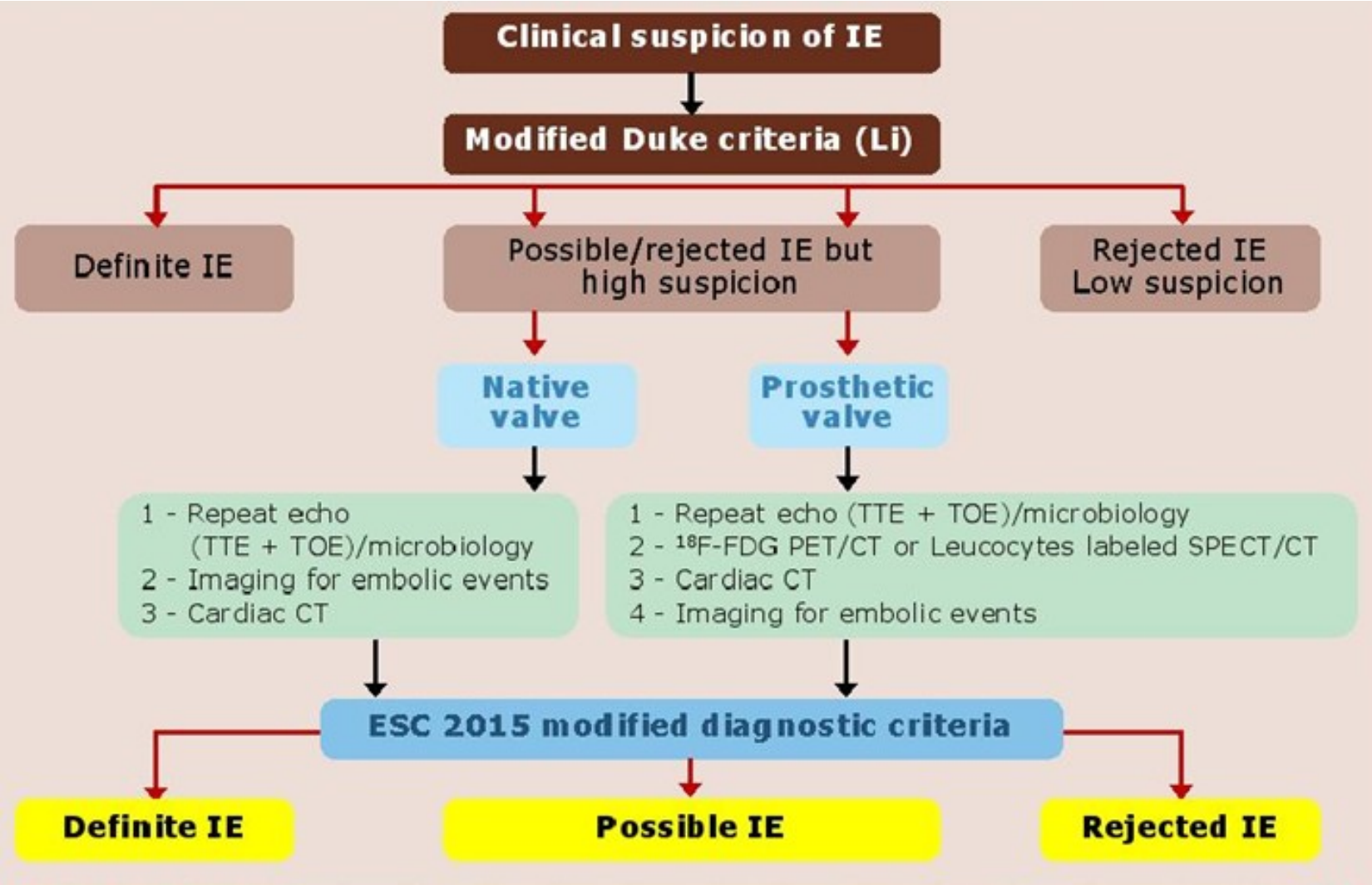

ESC guidelines

Imaging nell'endocardite infettiva

Cardiac device-related infective endocarditis (CDRIE)

Recommendations	Class	Level
A. Diagnosis		
1. Three or more sets of blood cultures are recommended before prompt initiation of antimicrobial therapy for CIED infection.	I	C
2. Lead-tip culture is indicated when the CIED is explanted.	I	C
3. TOE is recommended in patients with suspected CDRIE with positive or negative blood cultures, independent of the results of TTE, to evaluate lead-related endocarditis and heart valve infection	I	C
4. Intracardiac echocardiography may be considered in patients with suspected CDRIE, positive blood cultures and negative TTE and TOE.	IIb	C
5. Radiolabelled leukocyte scintigraphy and ^{18}F-FDG PET/CT scanning may be considered additive tools in patients with suspected CDRIE, positive blood cultures, and negative echocardiography.	IIb	C

ESC guidelines

Caso clinico 1

- **Paziente di 64 anni**
- **Dializzato**
- **Febbre da alcuni giorni**
- **Giunto per sospetta infezione di CVC**
- **In anamnesi sostituzione valvola mitralica con bioprotesi Epic Valve**

Caso clinico 1

Agli esami di laboratorio:

- **PCR 152 mg/L**
- **Procalcitonina 12,8 ng/ml**
- **Globuli bianchi 18000/mmc**
- **Neutrofili 15000/mmc**

Caso clinico 1

Ecocardiogramma transtoracico

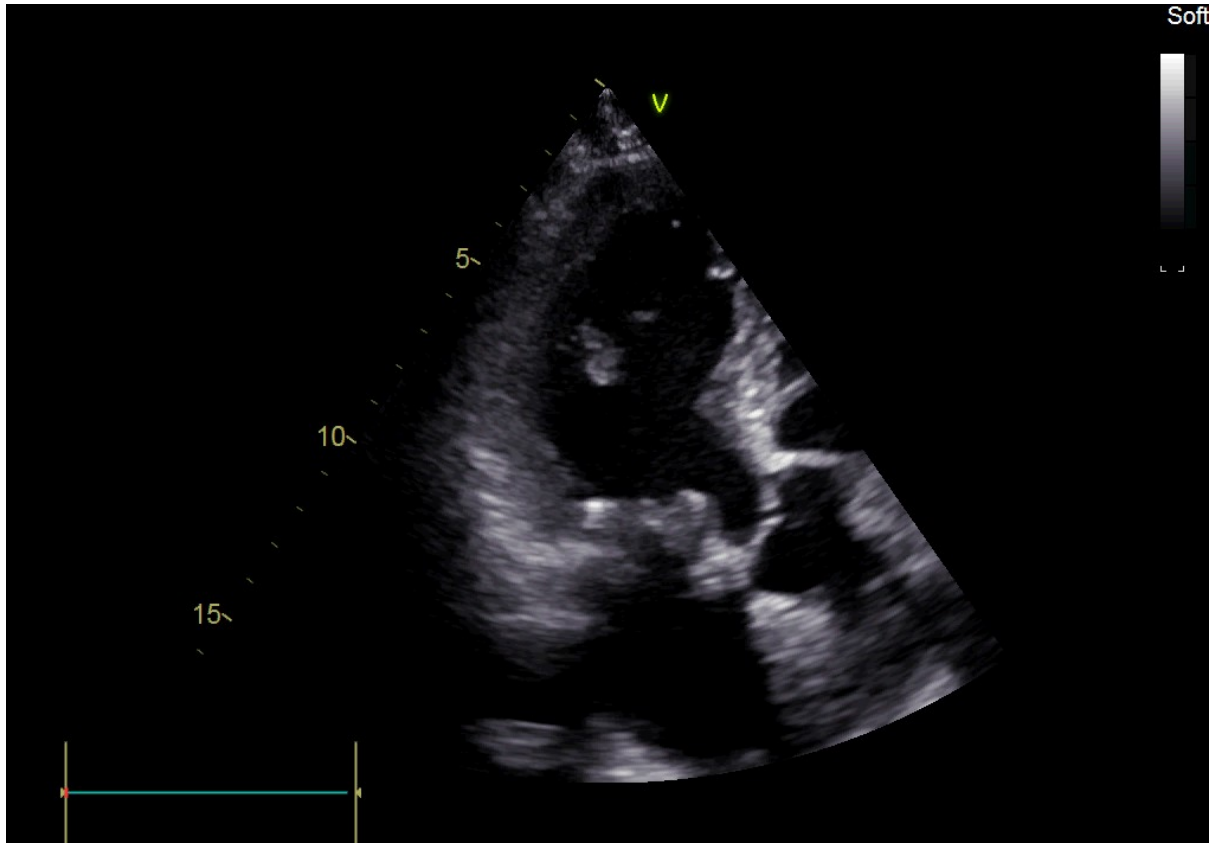

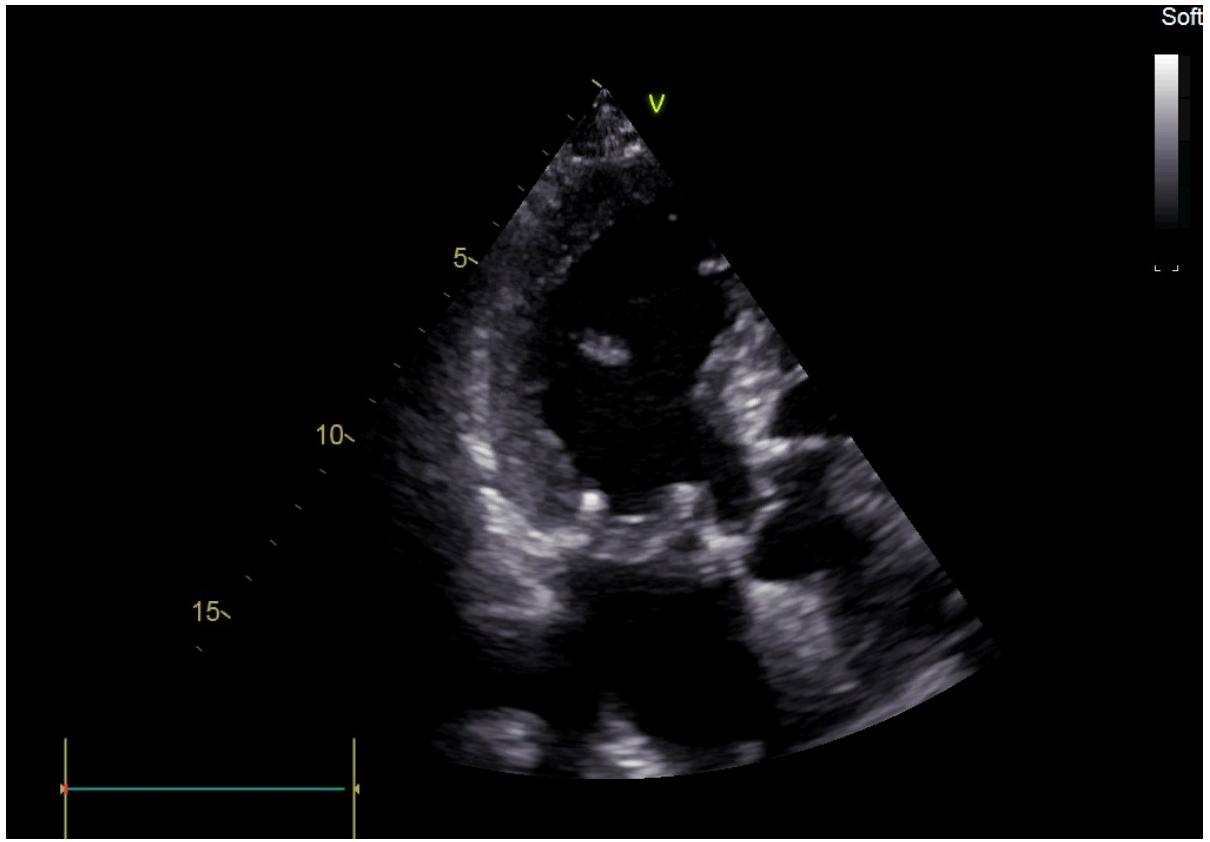

Caso clinico 1

Ecocardiogramma transesofageo

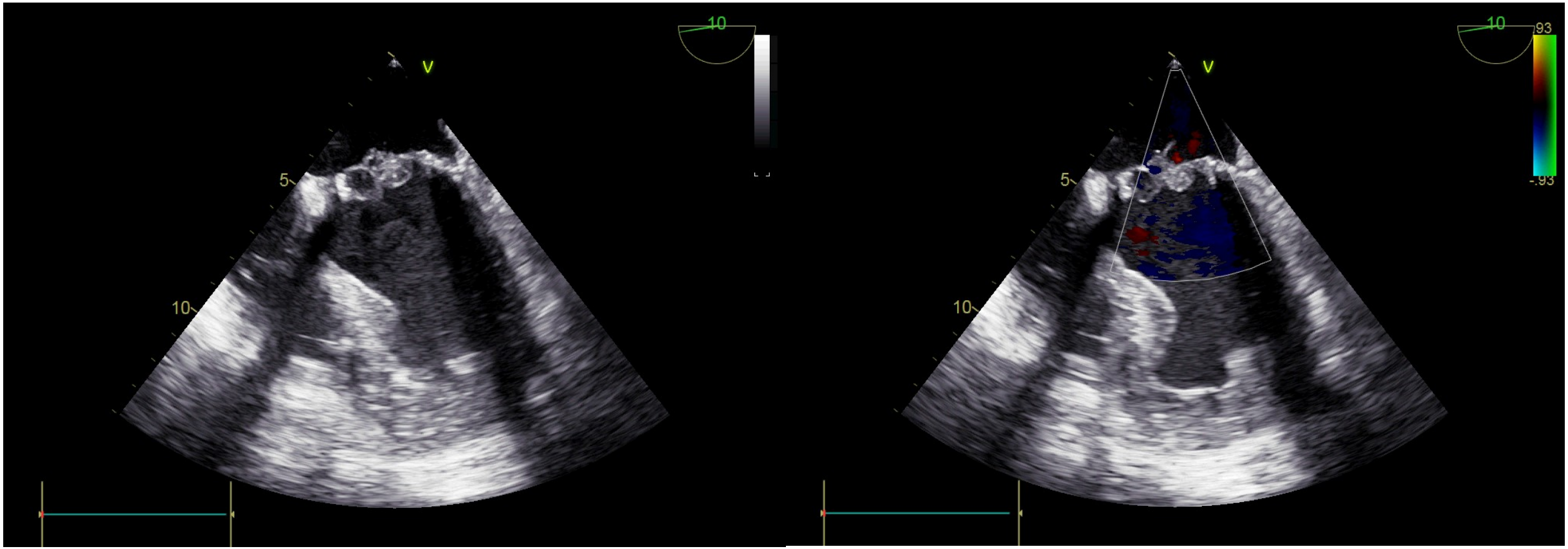

Caso clinico 1

Ecocardiogramma transesofageo

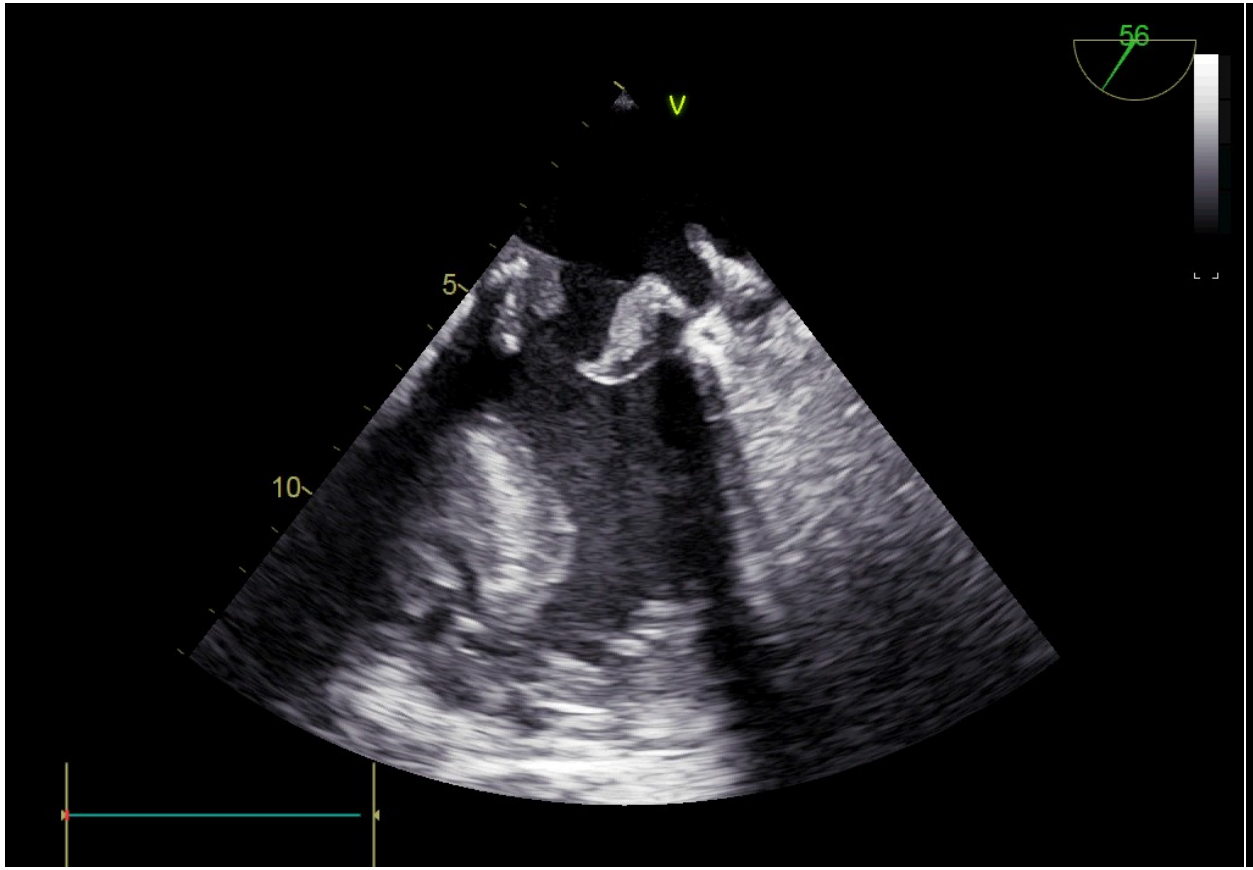

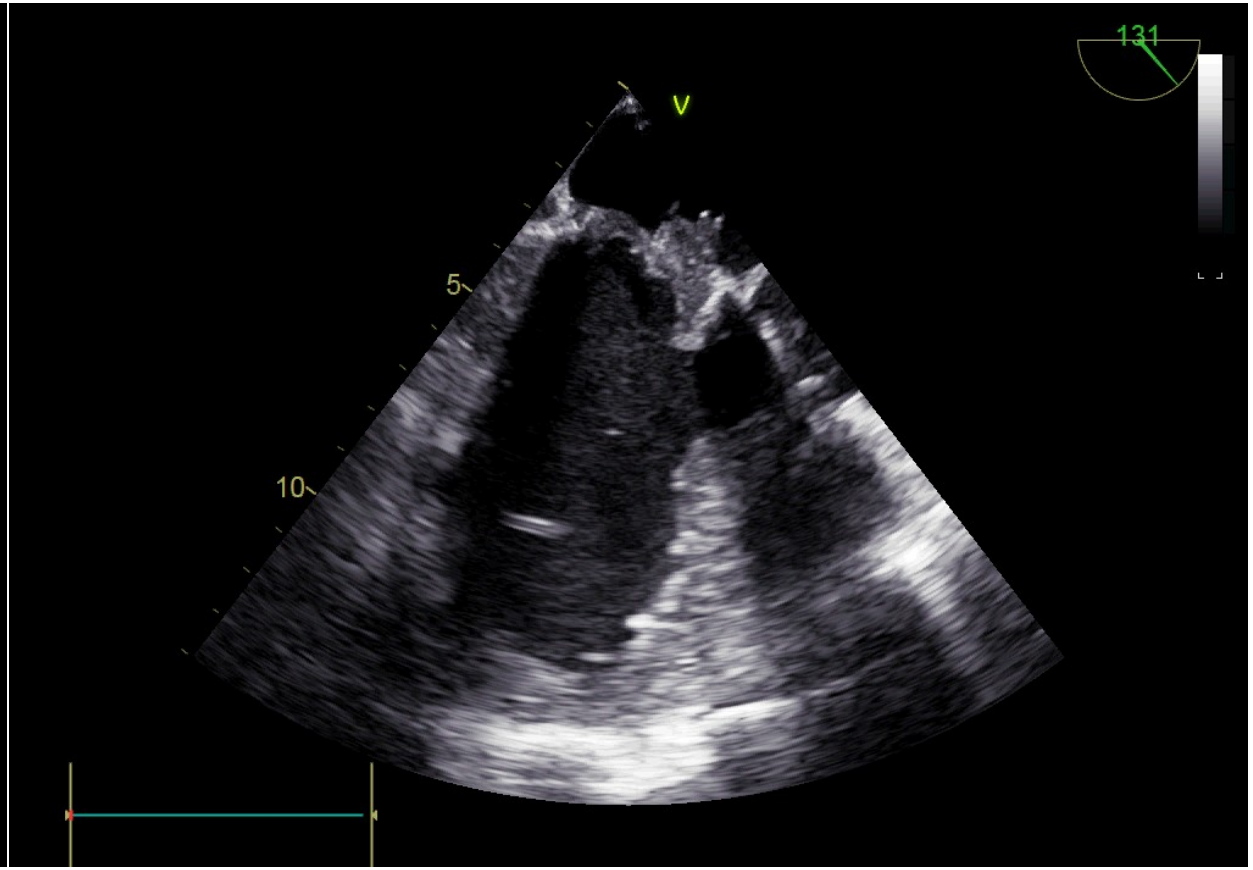

Caso clinico 2

- Paziente di 66 anni
- Anamnesi cardiologica negativa
- Apiretico
- Giunge per disturbi motori
- Evidenza di ictus cerebellare

Caso clinico 2

Agli esami di laboratorio:

- **PCR 15 mg/L**
- **Procalcitonina 0,7 ng/ml**
- **Globuli bianchi 7500/mmc**
- **Neutrofili 5600/mmc**

Caso clinico 2

Ecocardiogramma transtoracico

Caso clinico 2

Ecocardiogramma transtoracico

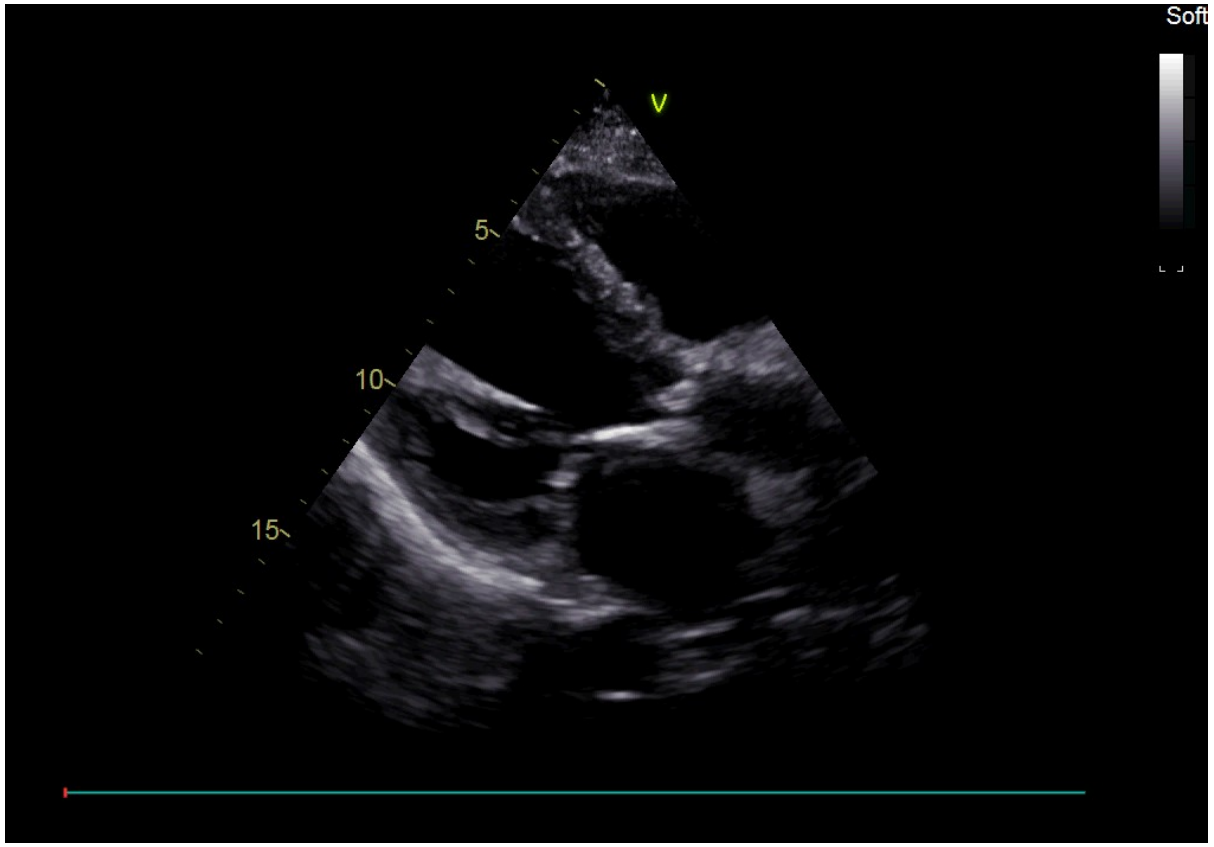

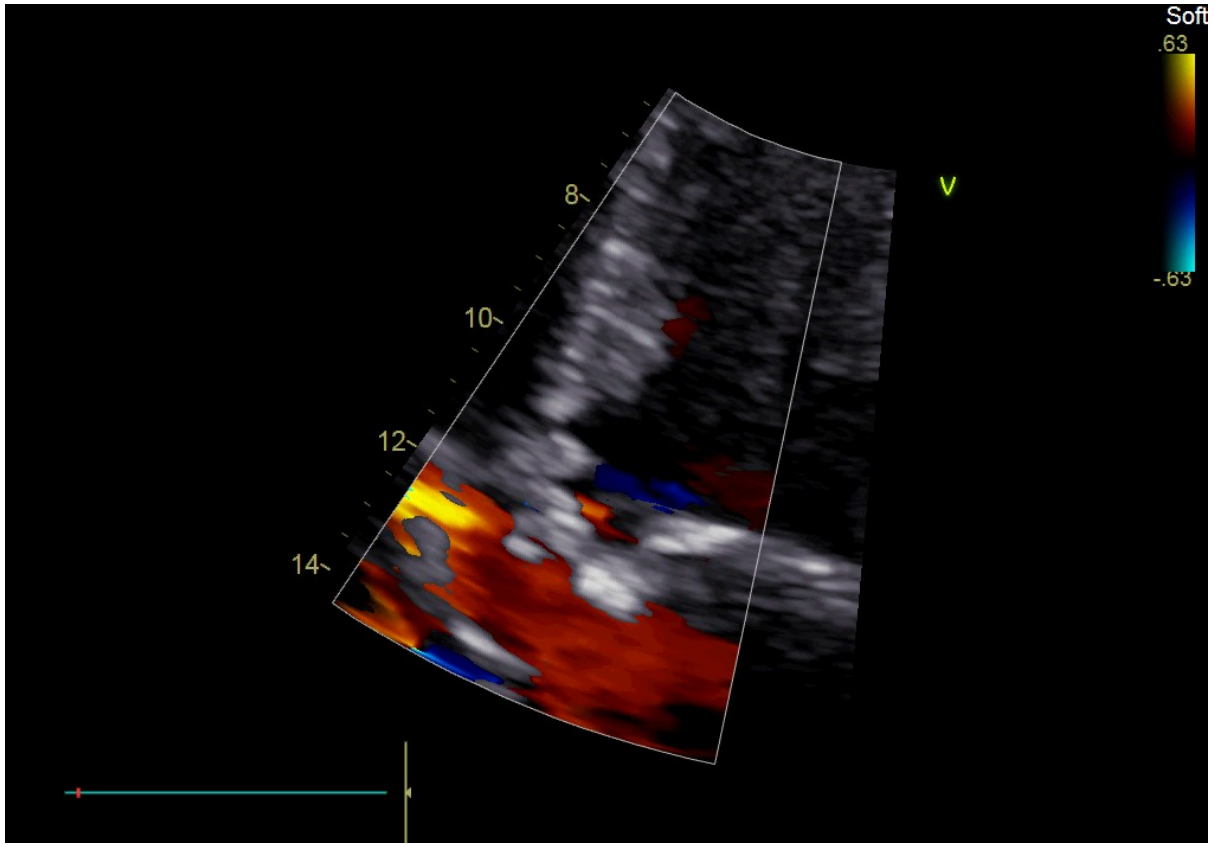

Caso clinico 2

Ecocardiogramma transesofageo…

Fondamentale per la stratificazione diagnostica definitiva…

GRAZIE PER L’ATTENZIONE