ADPKD: immagini – prognosi – terapia

Prof. Francesco Trepiccione

Torre del Greco 17/12/19

Cattedra di Nefrologia
Università della Campania
“L. Vanvitelli”

European Reference Networks

biogem s.c.ar.l.

Agenda

- ADPKD vs Reni Multicistici ruolo del RMN
- Diagnosi/prognosi per imaging
- Casi clinici

Progressi negli ultimi decenni

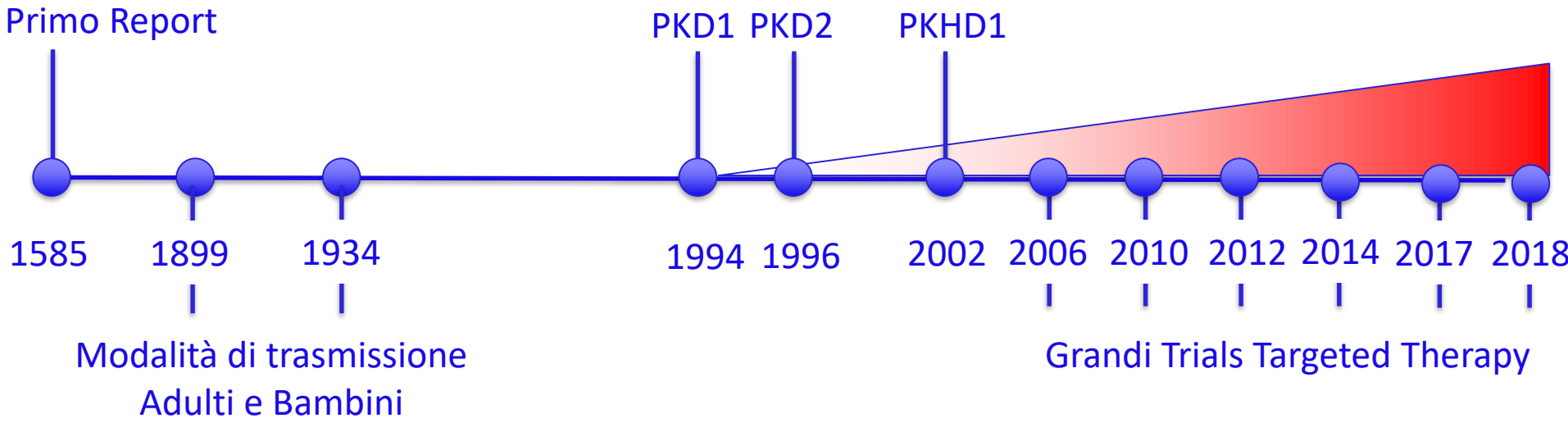

Diagnostica integrata

ADPKD vs Reni Multicistici

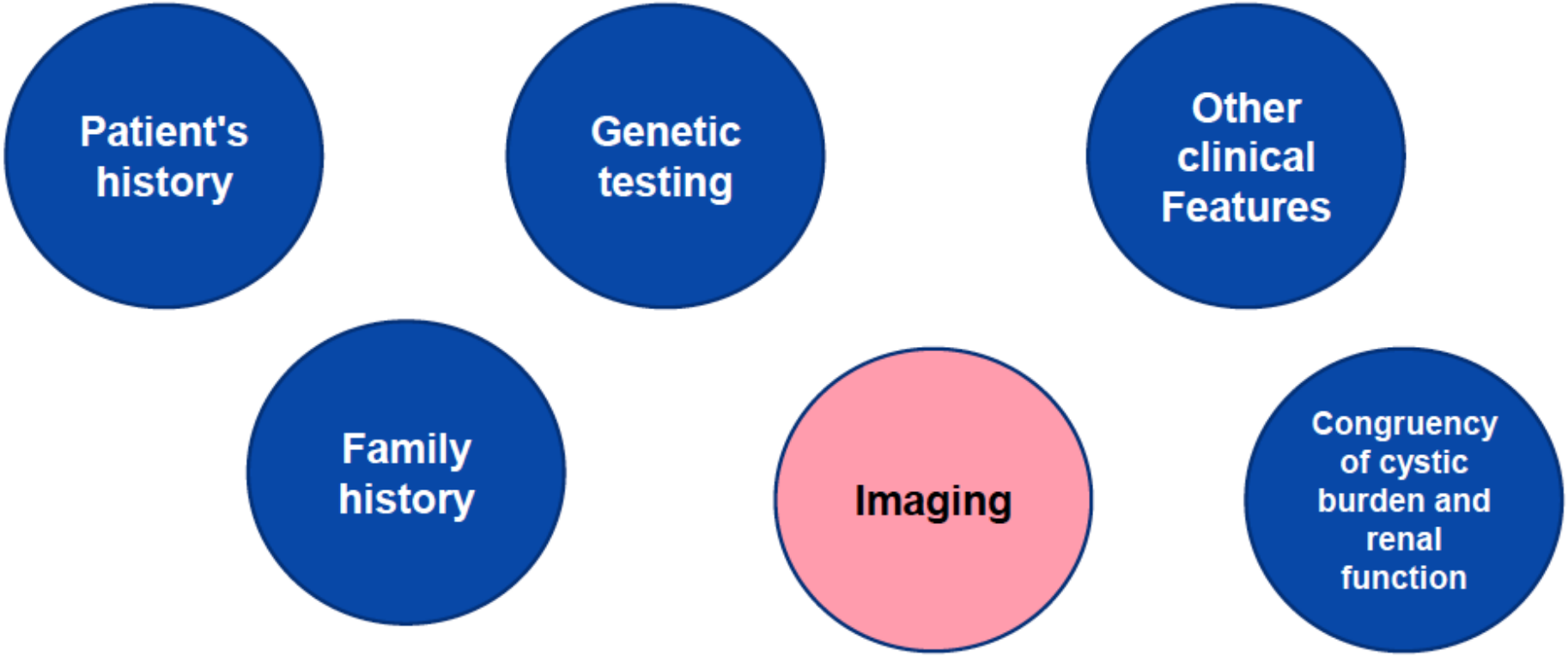

Confronto fra tecniche di imaging

Imaging modality	Ultrasonography	CT	MRI
Advantages	Cost-effective, high patient compliance	Fast imaging, highly reliable	Superb tissue contrast, highly reliable
Disadvantages	Operator-dependency, limited resolution	Radiation, iodinated contrast agent	Slow imaging (requiring longer breath-hold), increased concern for claustrophobia, gadolinium contrast agent
Quantitative imaging applications	Screening, long-term changes	Short-term changes, perfusion imaging	Short-term changes, imaging cysts without contrast agent, renal blood flow measurement, perfusion and diffusion imaging
Smallest diameter of renal cyst to be detected with confidence	7–10 mm (largely dependent on patient's body *habitus*)	2 mm (requiring contrast-enhanced CT)	2 mm (detectable on T2 or contrast-enhanced T1 MRI)

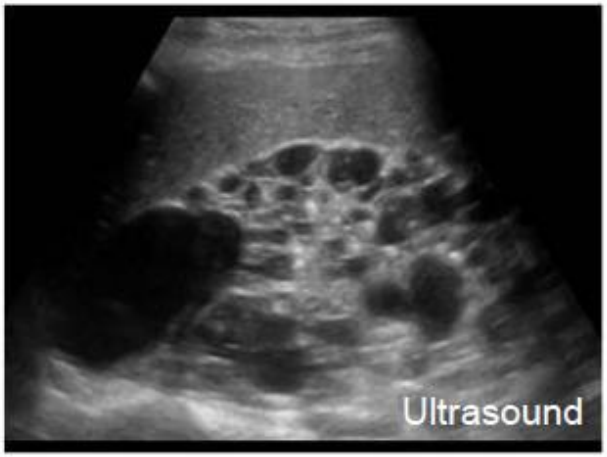

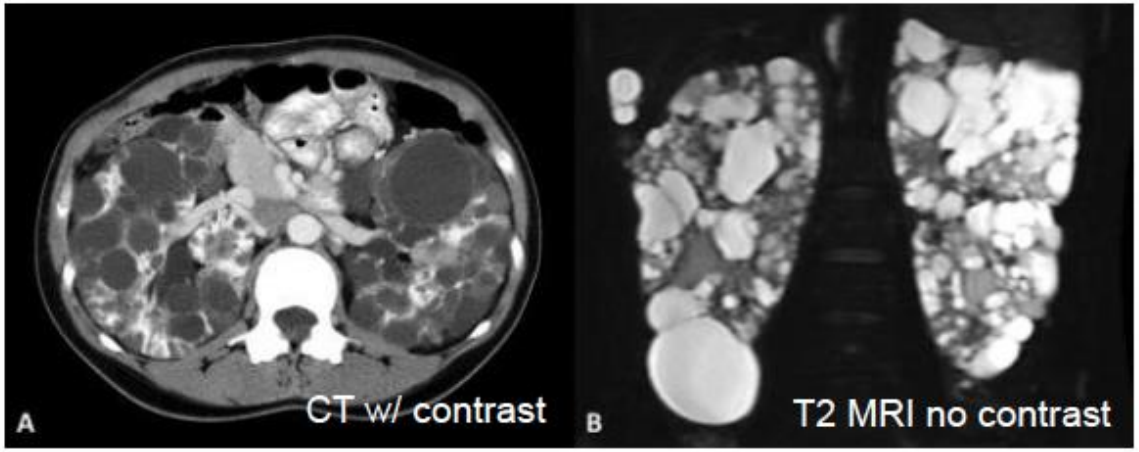

Criteri diagnostici su familiarità positiva

Positive family history		
	Ultrasound-based	**CT/MRI based**
Age 15-39	≥ 3 cysts (total)	> 10 cysts (total)
Age 40-59	≥ 2 cysts in each kidney	Not determined
Age > 60	≥ 4 cysts in each kidney	Not determined
Negative family history		
Any age	≥ 10 cysts in each kidney (bilateral kidney enlargement)	Not determined

Elementi suggestivi per il substrato genetico

- Helpful more in diagnosis than in prognosis
  - ***PKD1*:** One relative w/ ESRD onset ≤ 50 yo
  - ***PKD2*:** One relative w/ ESRD onset ≥ 70 yo
- Negative in 10% to 15% :
  - De novo mutations (5% of cases)
  - Mild disease from PKD2 mutations and non-truncating PKD1 mutations
  - Mosaicism
  - Unavailability of parental medical records

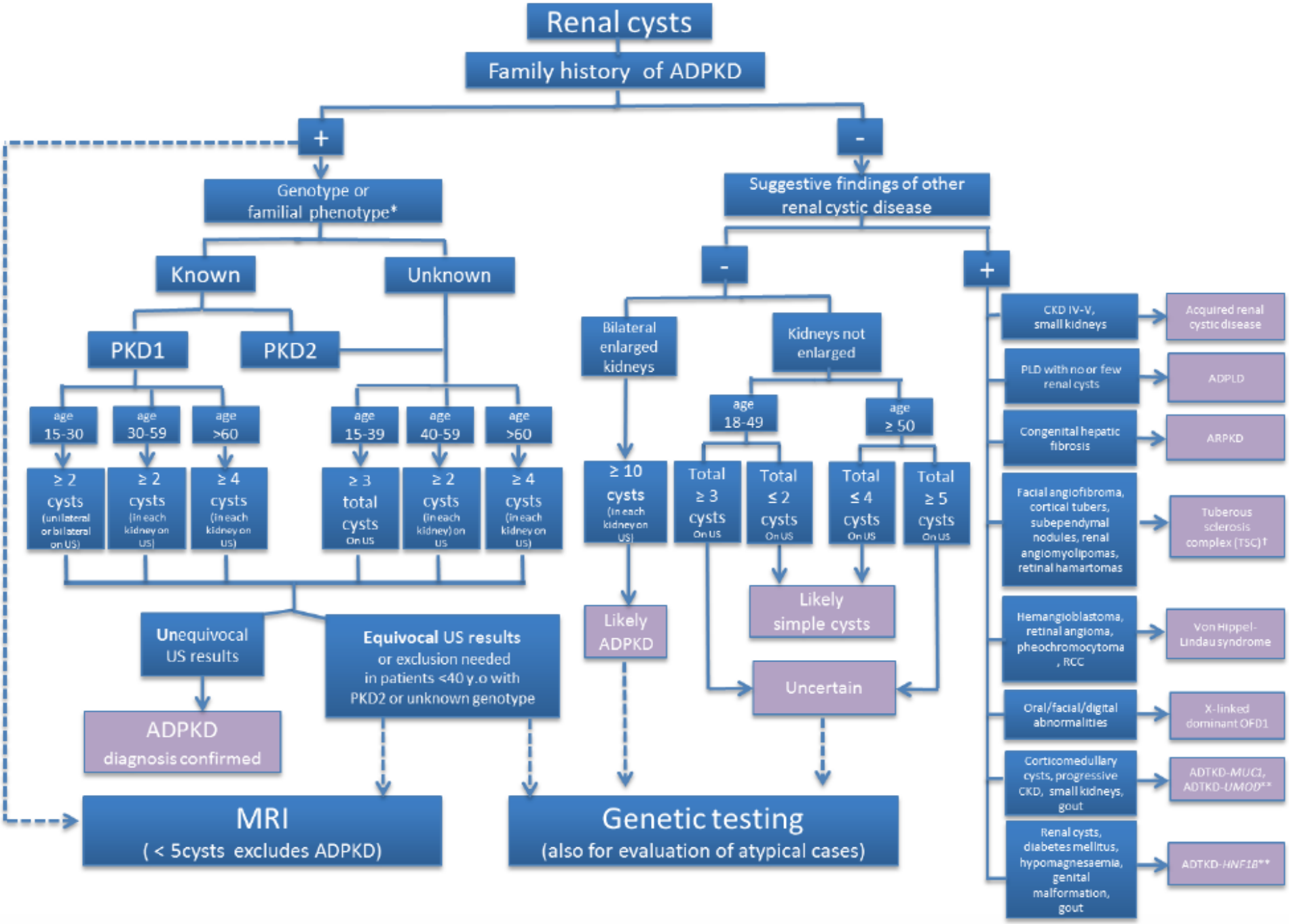

Chebib and Torres, AJKD 2016

Typical ADPKD: Class 1 (95%)

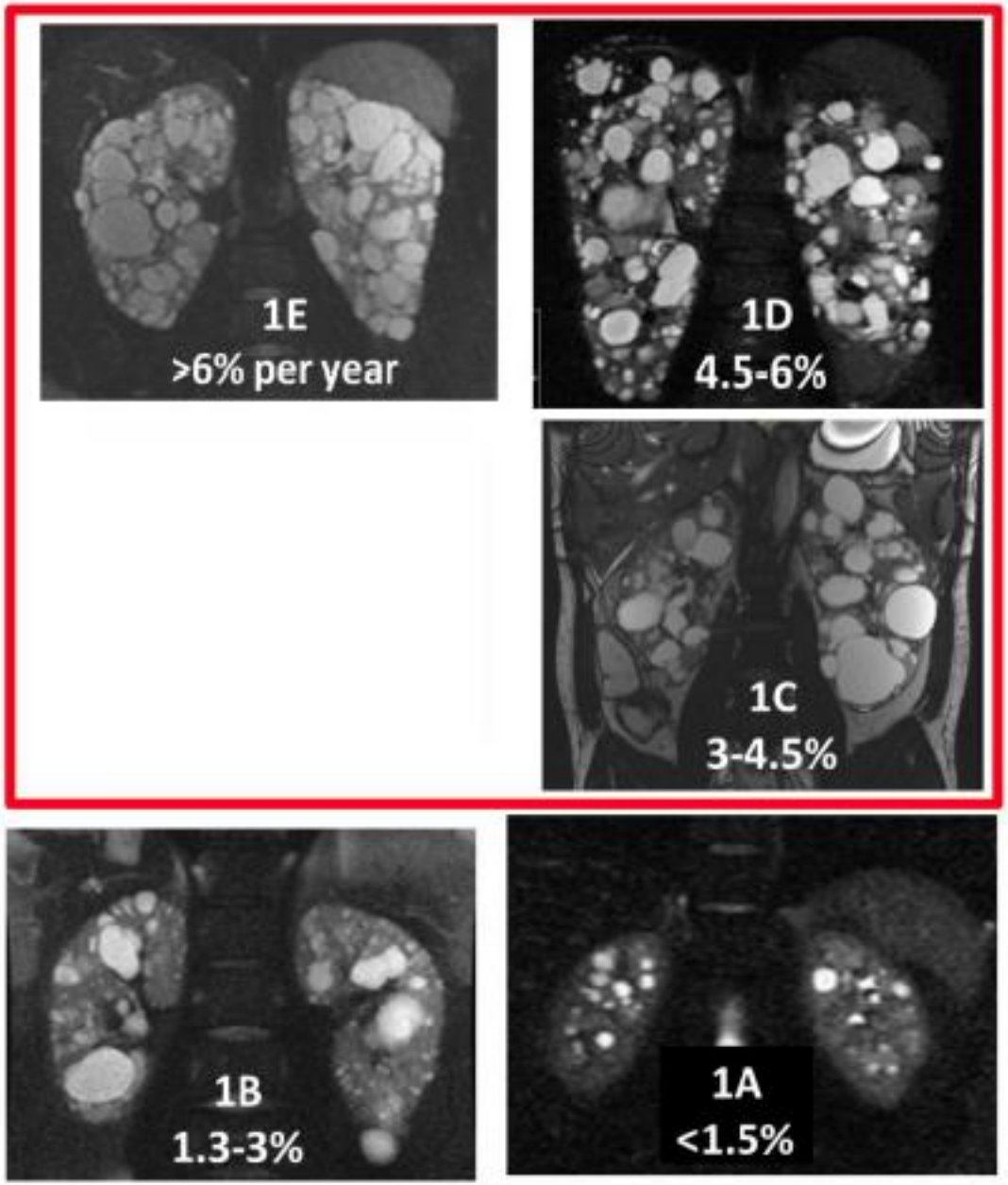

ADPKD Atipico: Classe II

Focal disease (2A)

Parenchymal atrophy (2B)

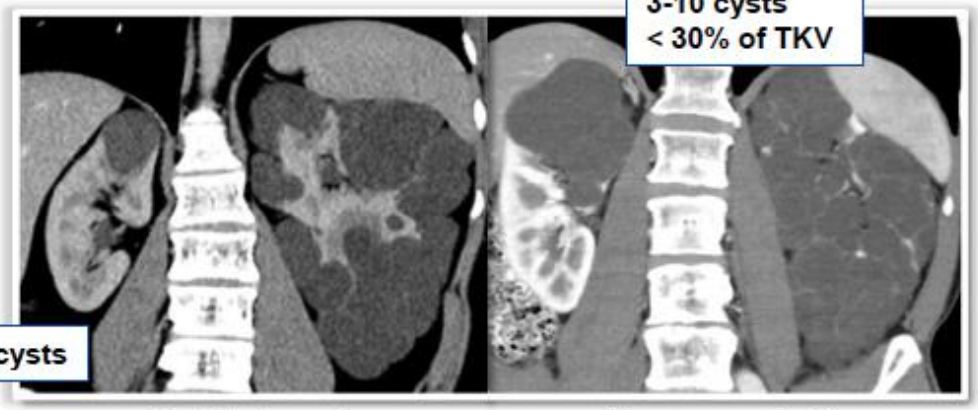

3-10 cysts
< 30% of TKV

0-2 cysts

Unilateral

Asymmetric

Enlargement in one kidney

atrophy in the other

Unilateral

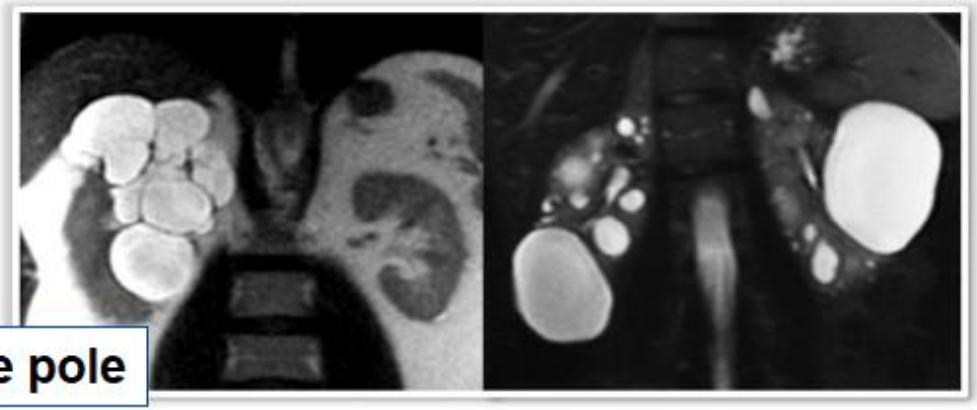

One pole

Segmental

Lop-sided

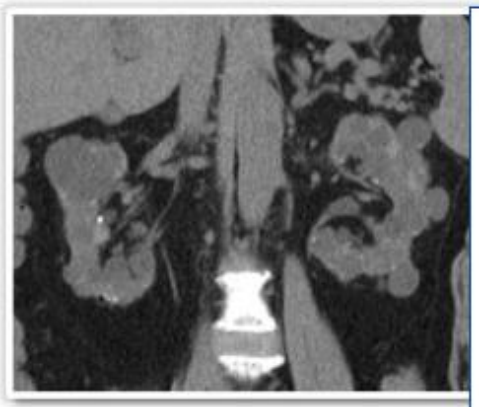

- Creat ≥1.5
- No kidney enlargement (<14.5 cm)
- replacement of kidney tissue by cysts
- Parenchymal atrophy

Bilateral

Influenza del genotipo sulla progressione del numero e volume delle cisti

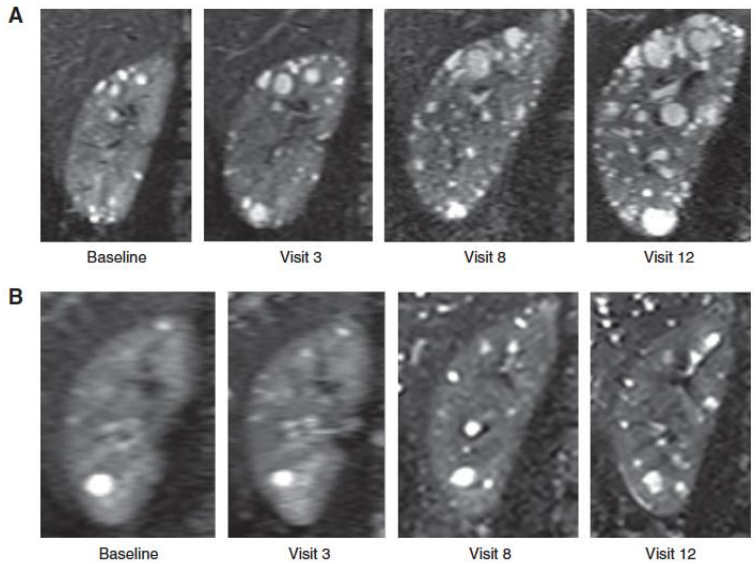

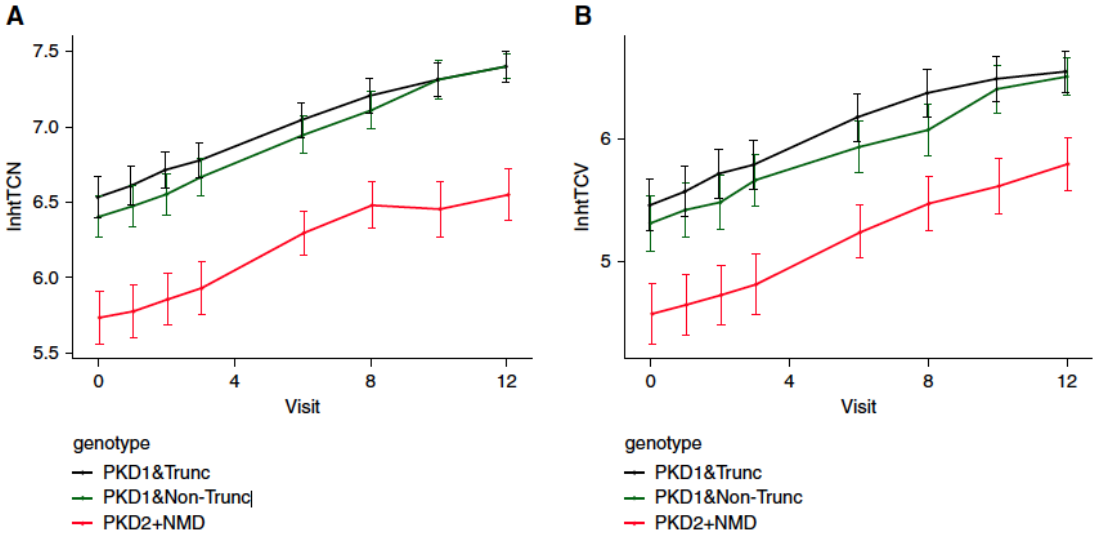

Bae KT, cJASN 2019

Valore prognostico del volume renale: studio CRISP

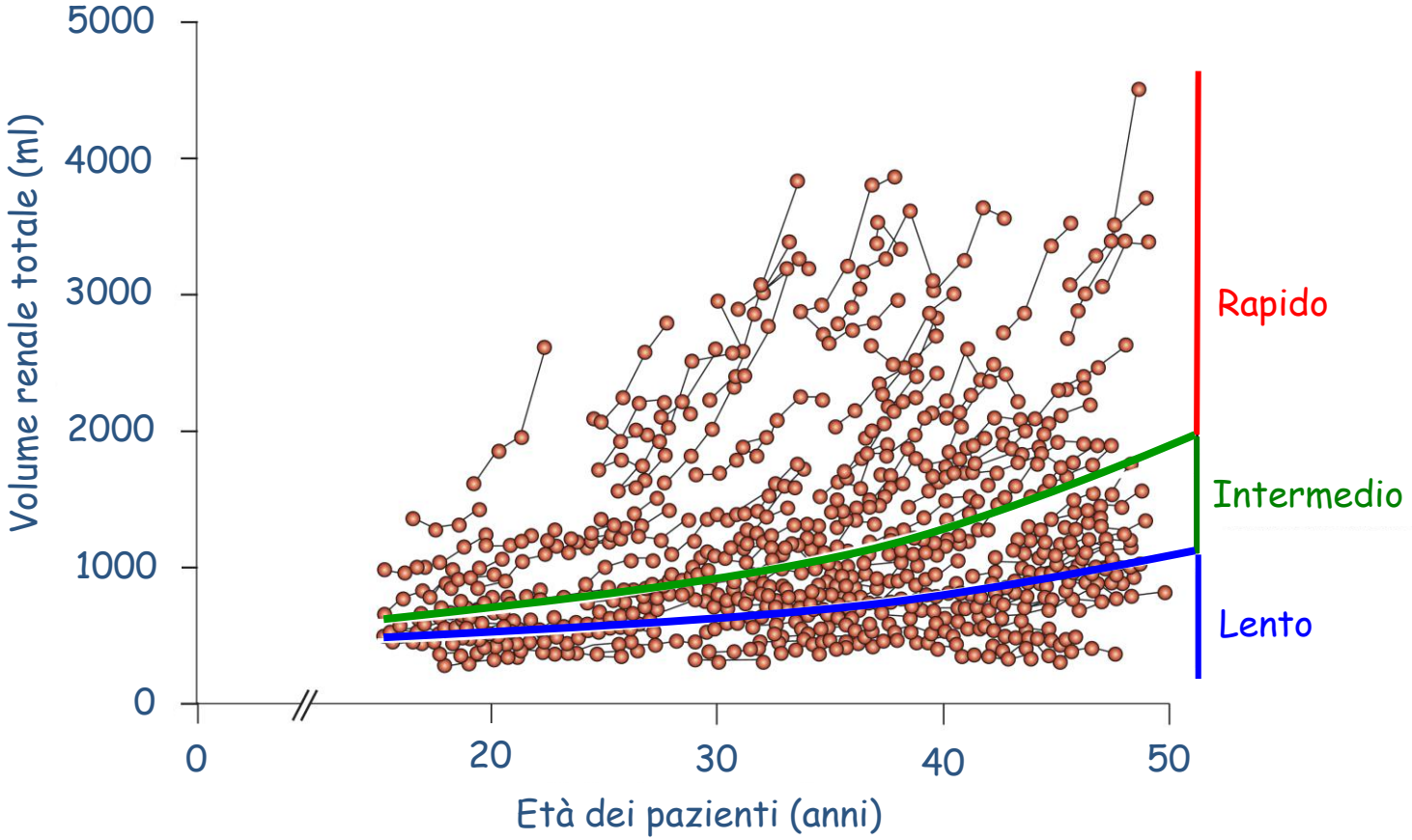

Grantham NEJM 2006

Mayo Clinic Classification hTKV and ADPKD progression

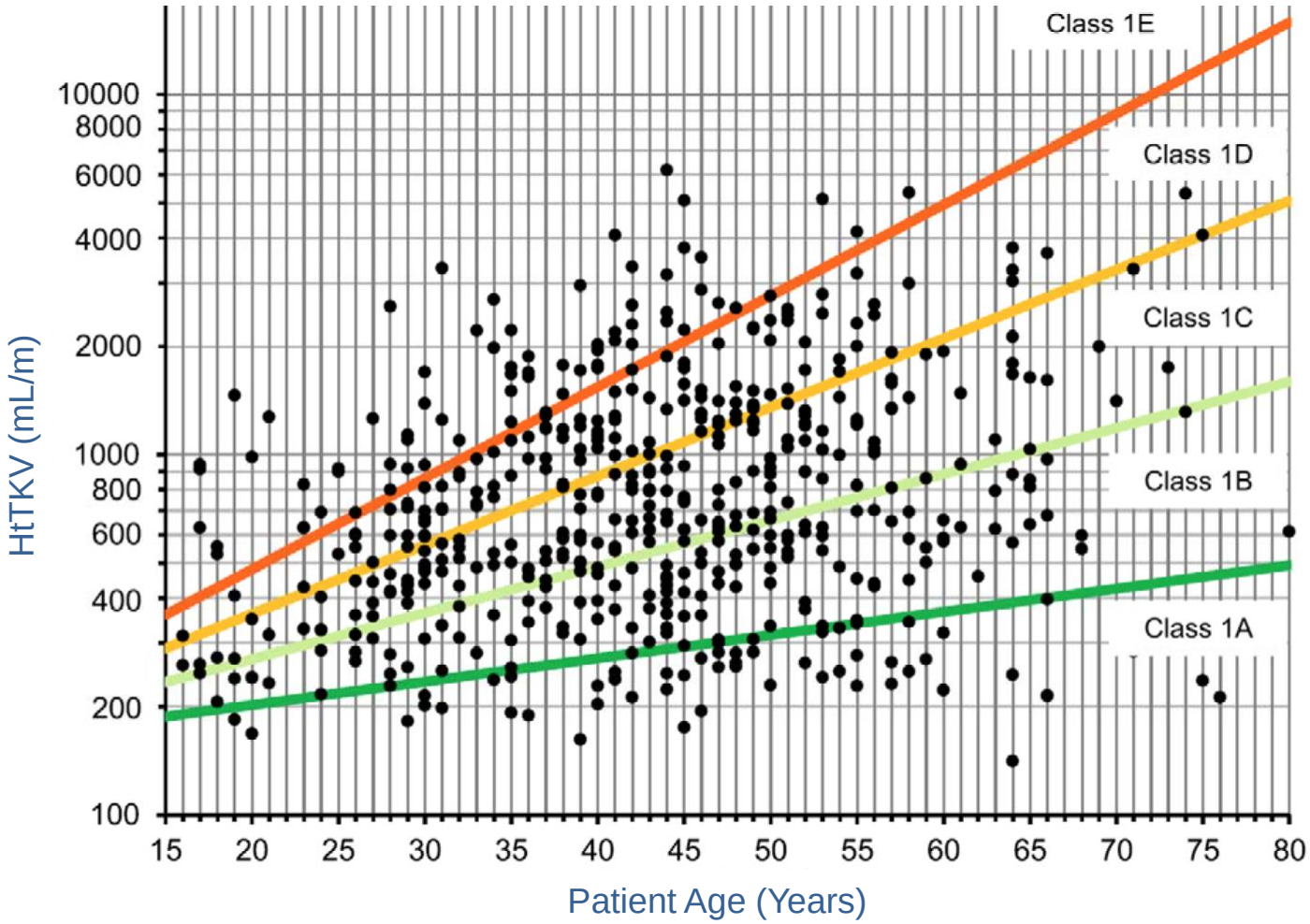

Irazabal MV JASN 2015

Mayo ADPKD classification

Typical ADPKD: Class 1 (95%)

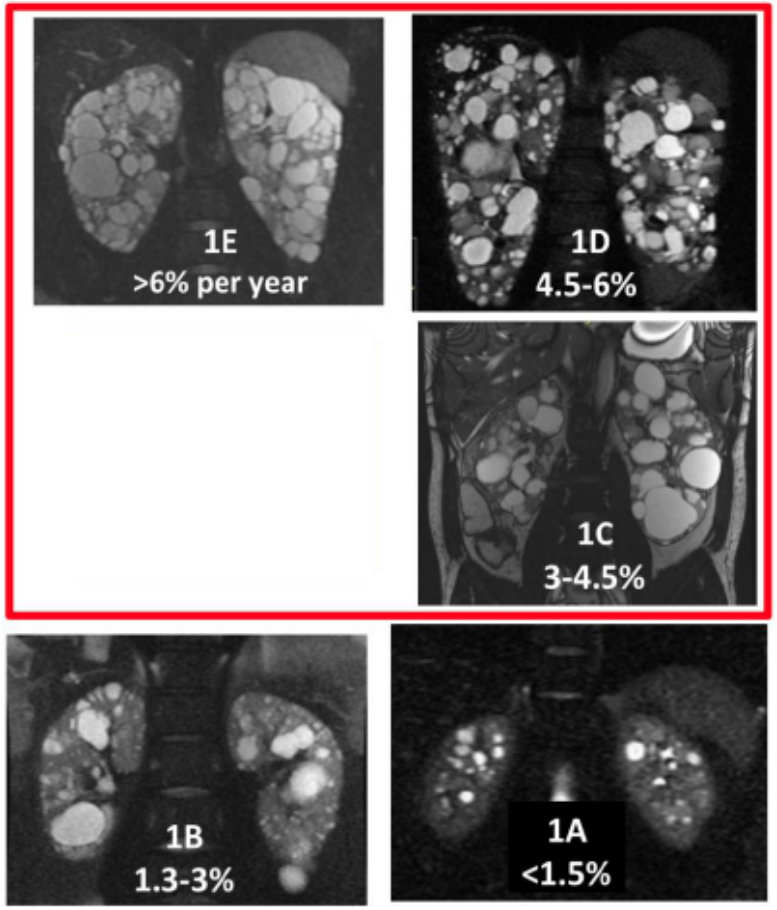

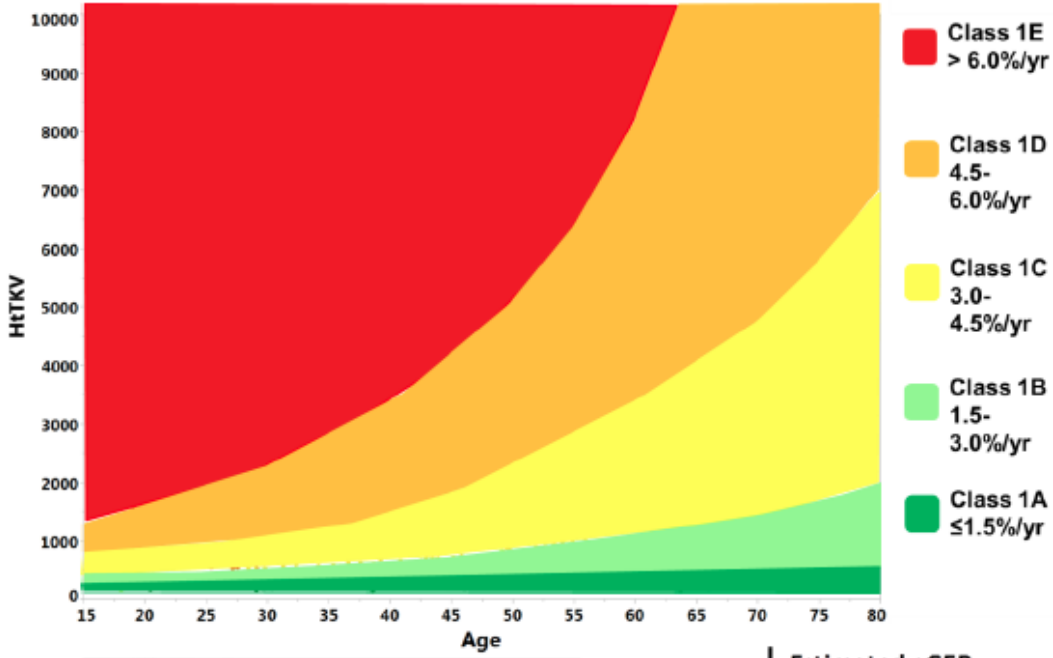

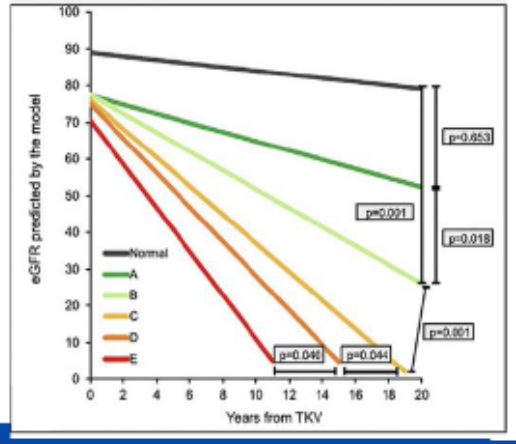

	Estimated eGFR slope (ml/min/SA per year)	
	Male	*Female*
Class 1A	-0.23	0.03
Class 1B	-1.33	-1.13
Class 1C	-2.36	-2.43
Class 1D	-3.48	-3.29
Class 1E	-4.78	-4.58

Irazabal et al. JASN 2015

©2018 MFMER

Step 1: Maximal sagittal length

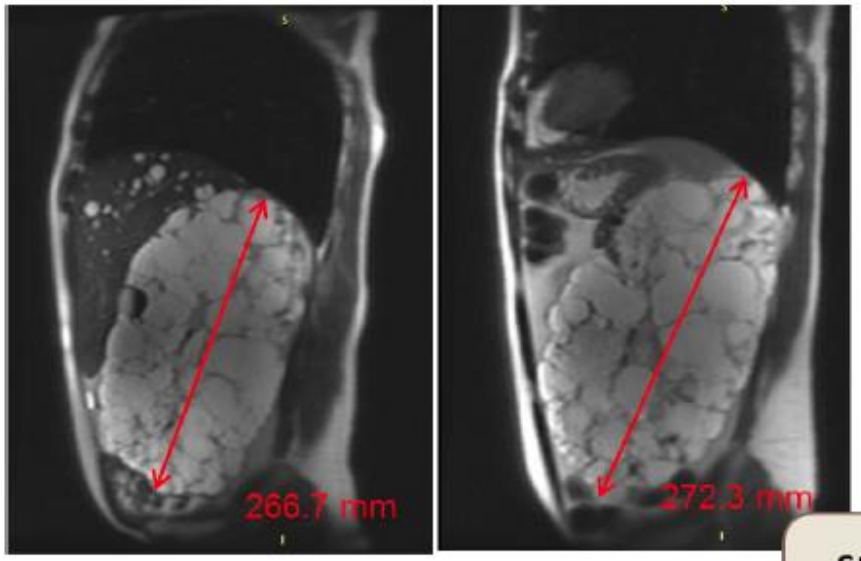

Step 2: Max. Coronal length

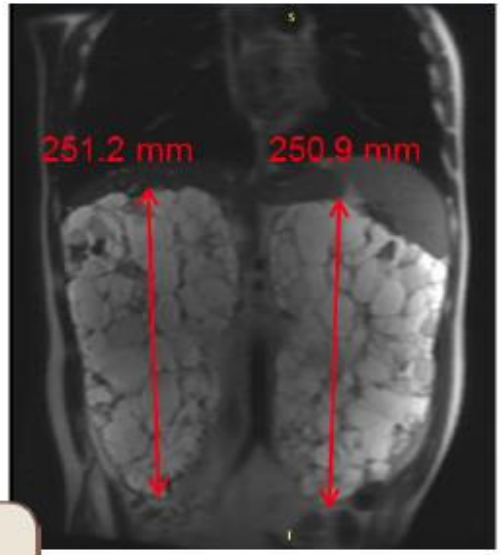

Step 3: Max. width and depth

©2018 MFMER | slide-42

Progressione del eGFR secondo le classi Mayo

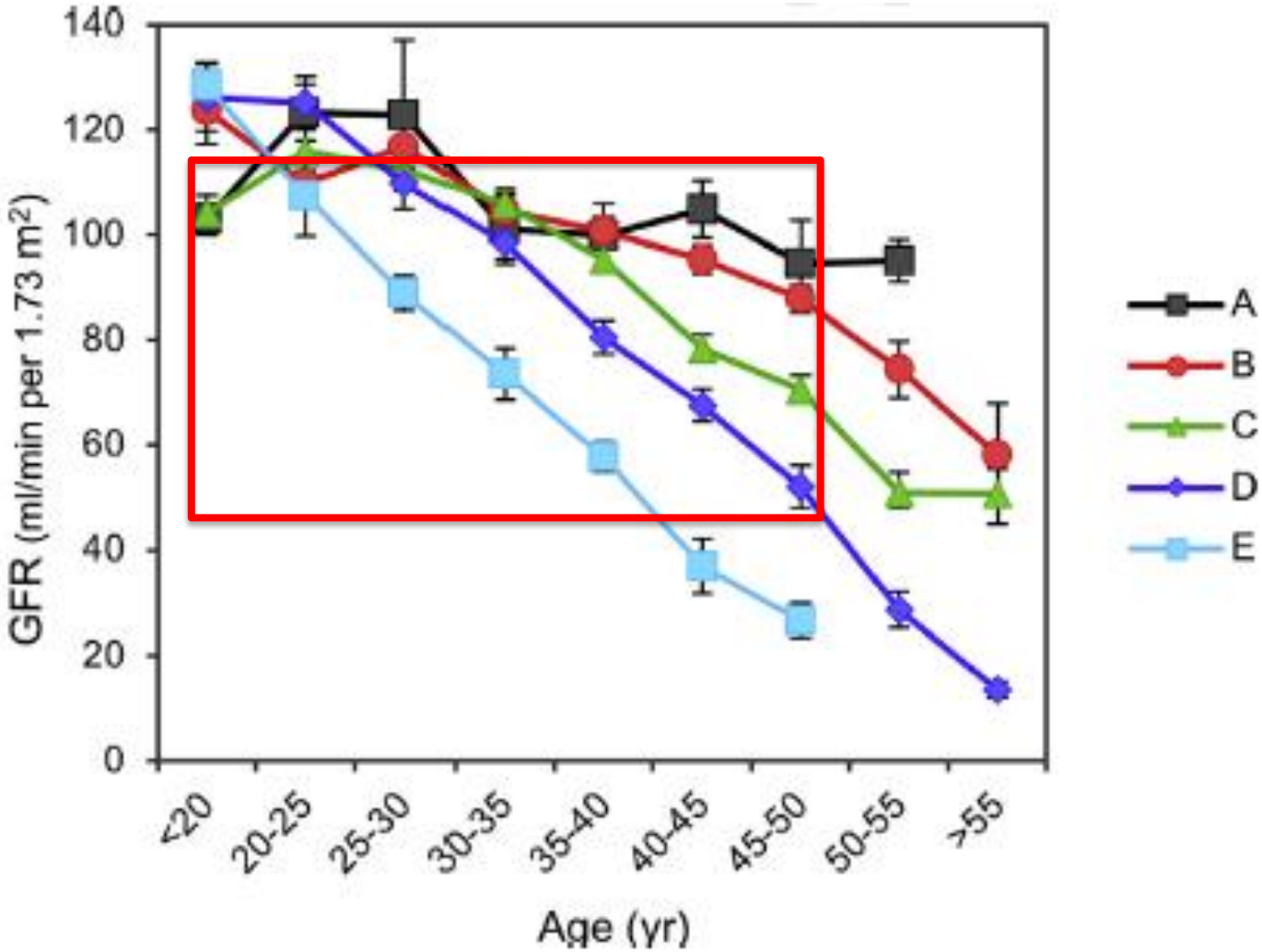

Yu ASL, Kid Int 2019

Traiettoria di predizione di declino dell' eGFR per classi di hTKV e genetica

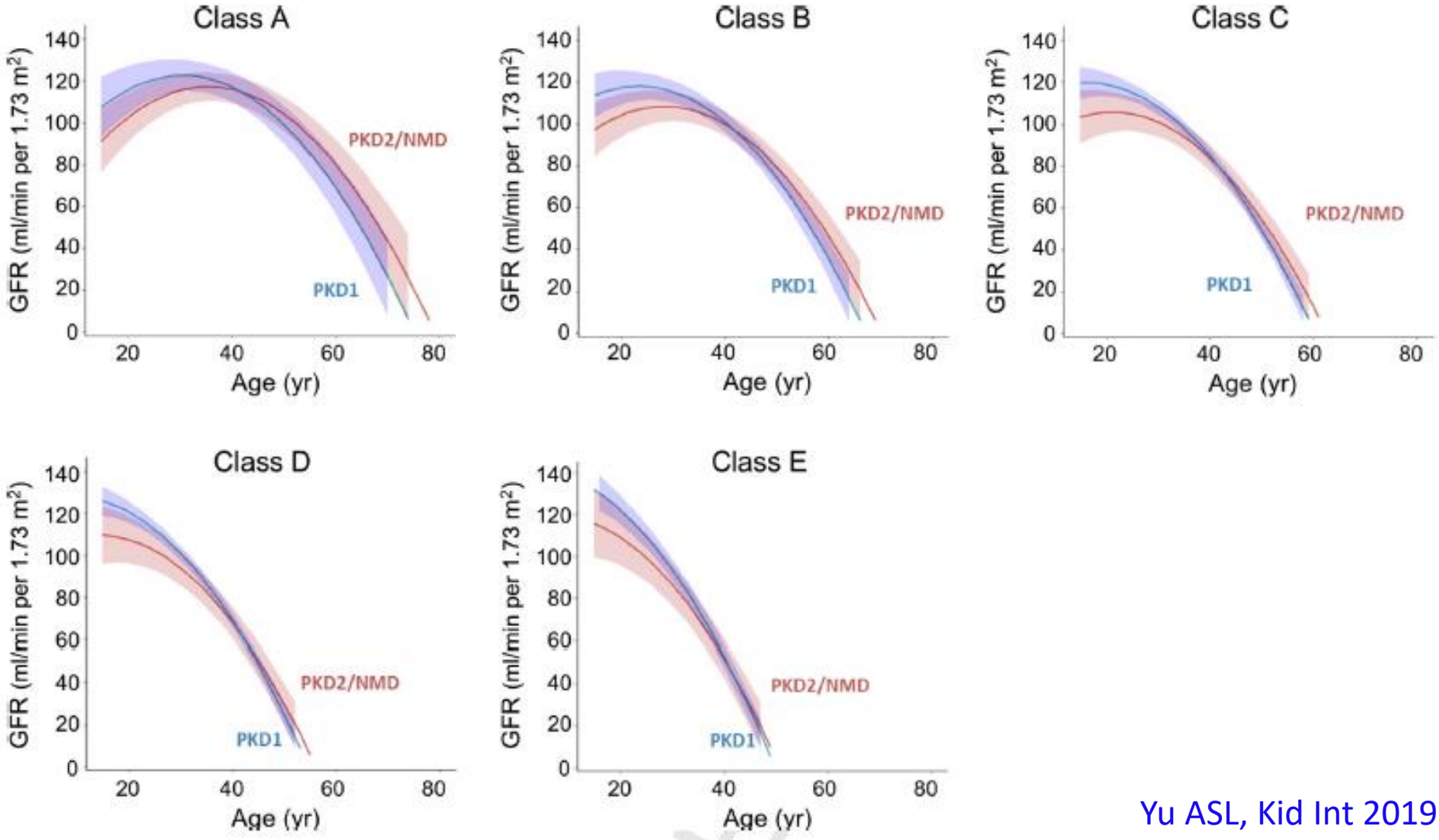

Yu ASL, Kid Int 2019

PROPKD Score

Predict renal survival in Autosomal Dominant Polycystic Kidney Disease (ADPKD) using genetics

Gender?

Male

Female

Does the Patient Meet These Criteria?

The PROPKD score can only be used in individuals over 35 years of age
or
in patients younger than 35, if they have both a urologic event before 35 years and onset of hypertension before age 35

Yes

No

Hypertension Onset Before Age 35?

Yes

No

First Urologic Event Before Age 35?

Urologic events defined as gross hematuria, cyst hemorrhage, cyst infection or flank pain related to cysts

Yes

No

Genetic abnormality leading to PKD?

PKD2 Mutation

Non-Truncating PKD1 Mutation

Truncating PKD1 Mutation

Valutare la severità di progressione dell'ADPKD

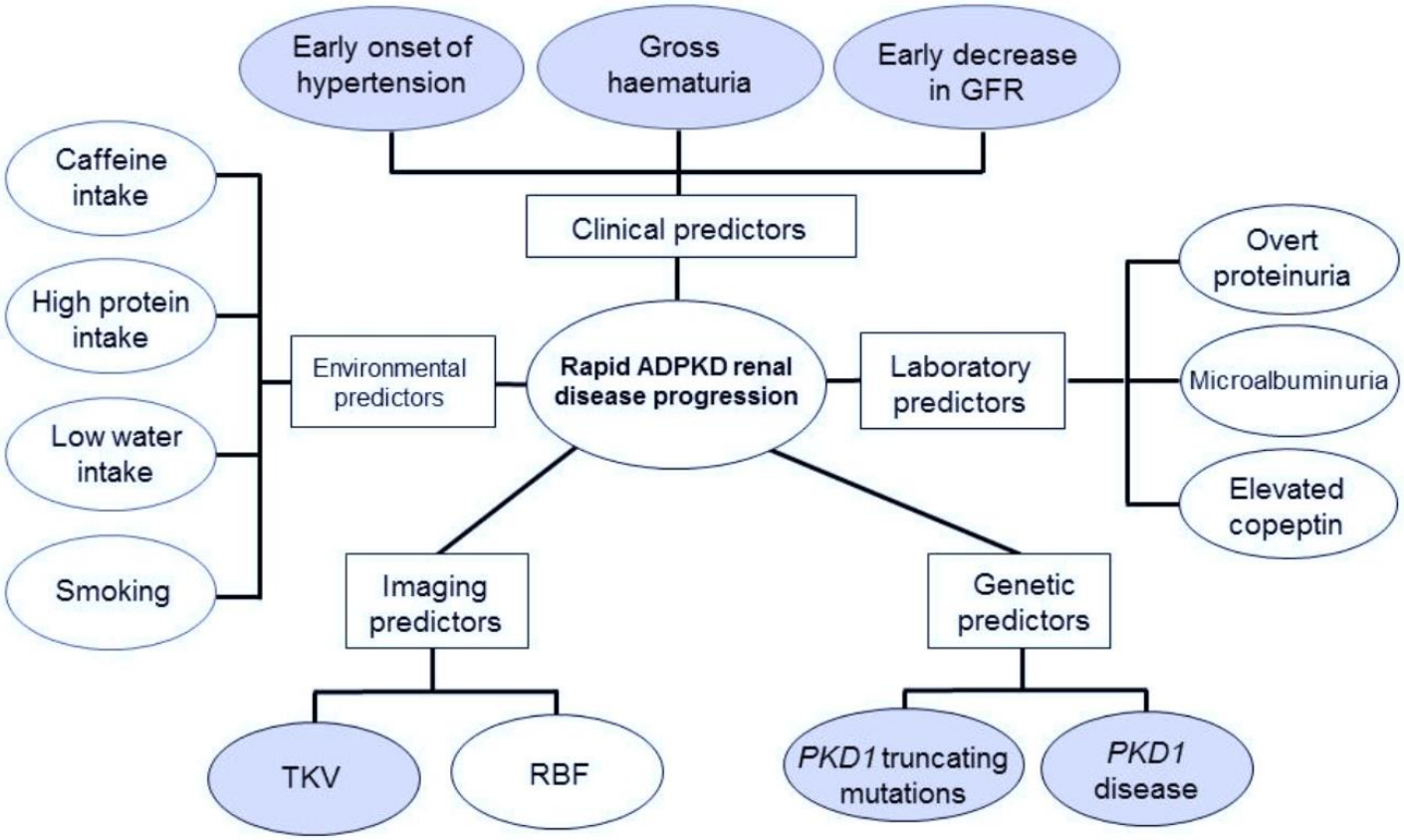

Schrier RW JASN 2014

PKD-1 troncante senza coinvolgimento epatico

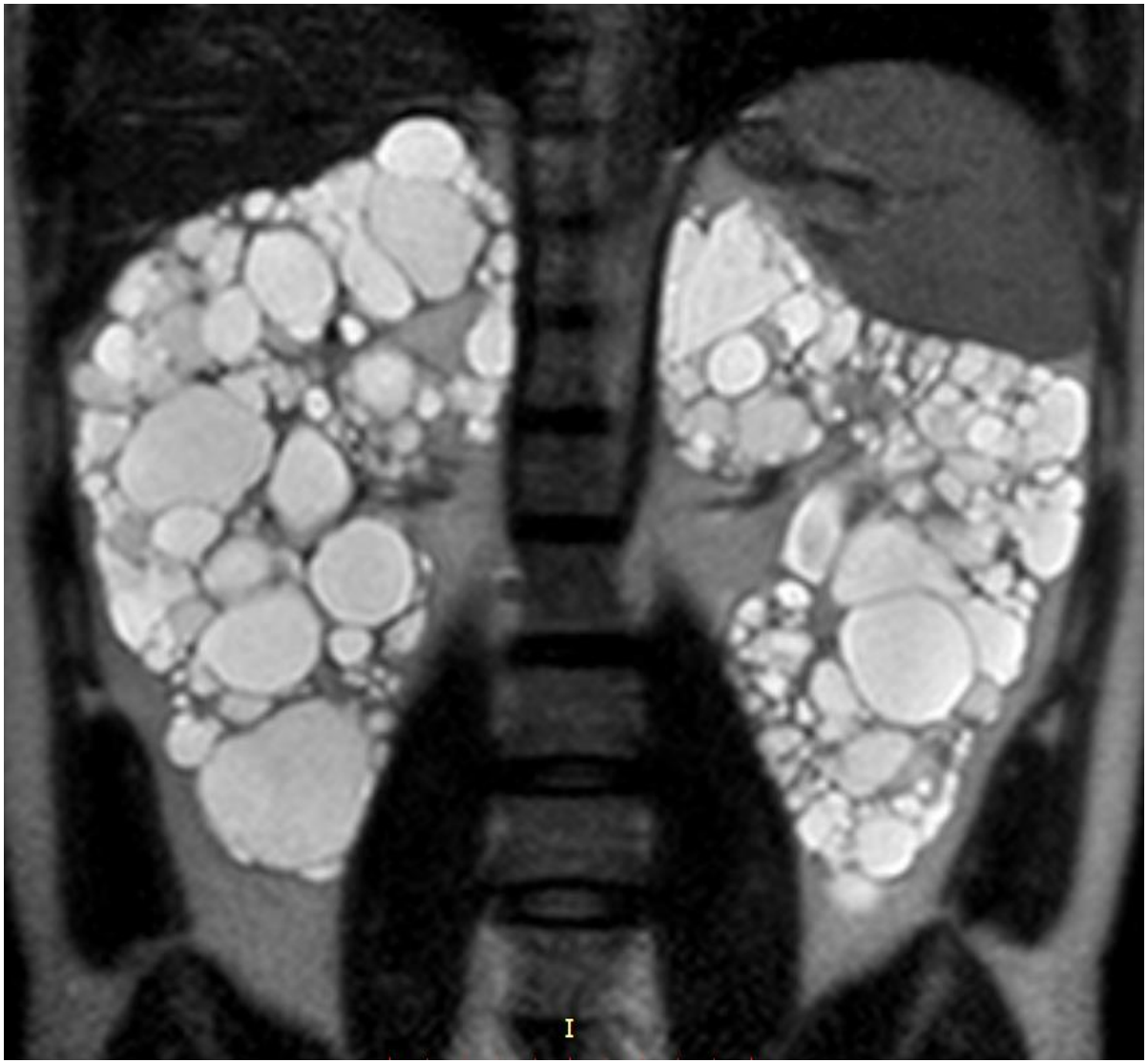

- Maschio di 28 anni
- + Familiarità
- Ipertenso
- Dolore Cronico
- Classe Mayo 1E

PKD-1 troncante con coinvolgimento epatico

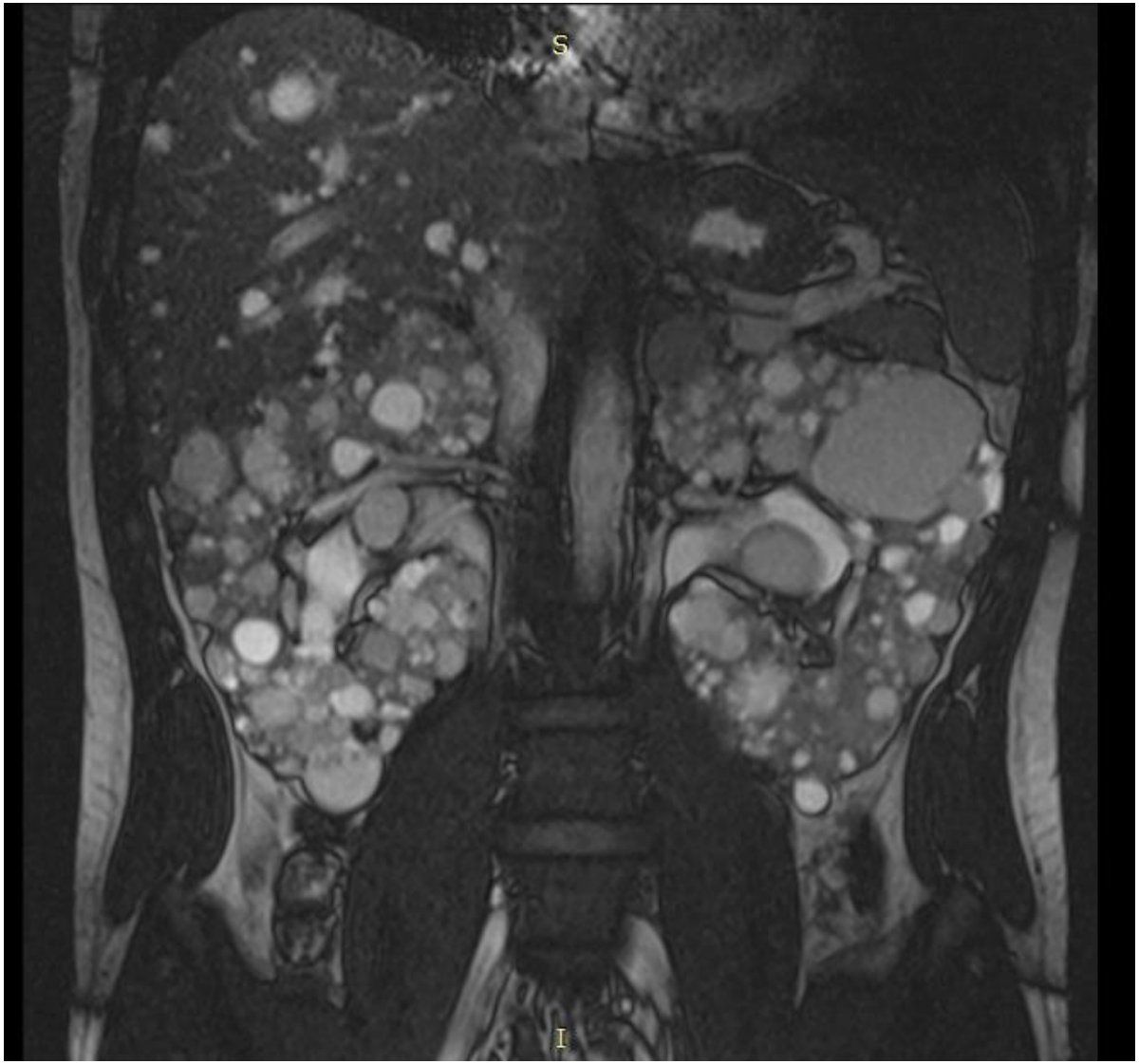

- Maschio 35 anni
- + Familiarità
- Ipertenso
- Classe Mayo 1D

PKD-1 troncante di classe IB

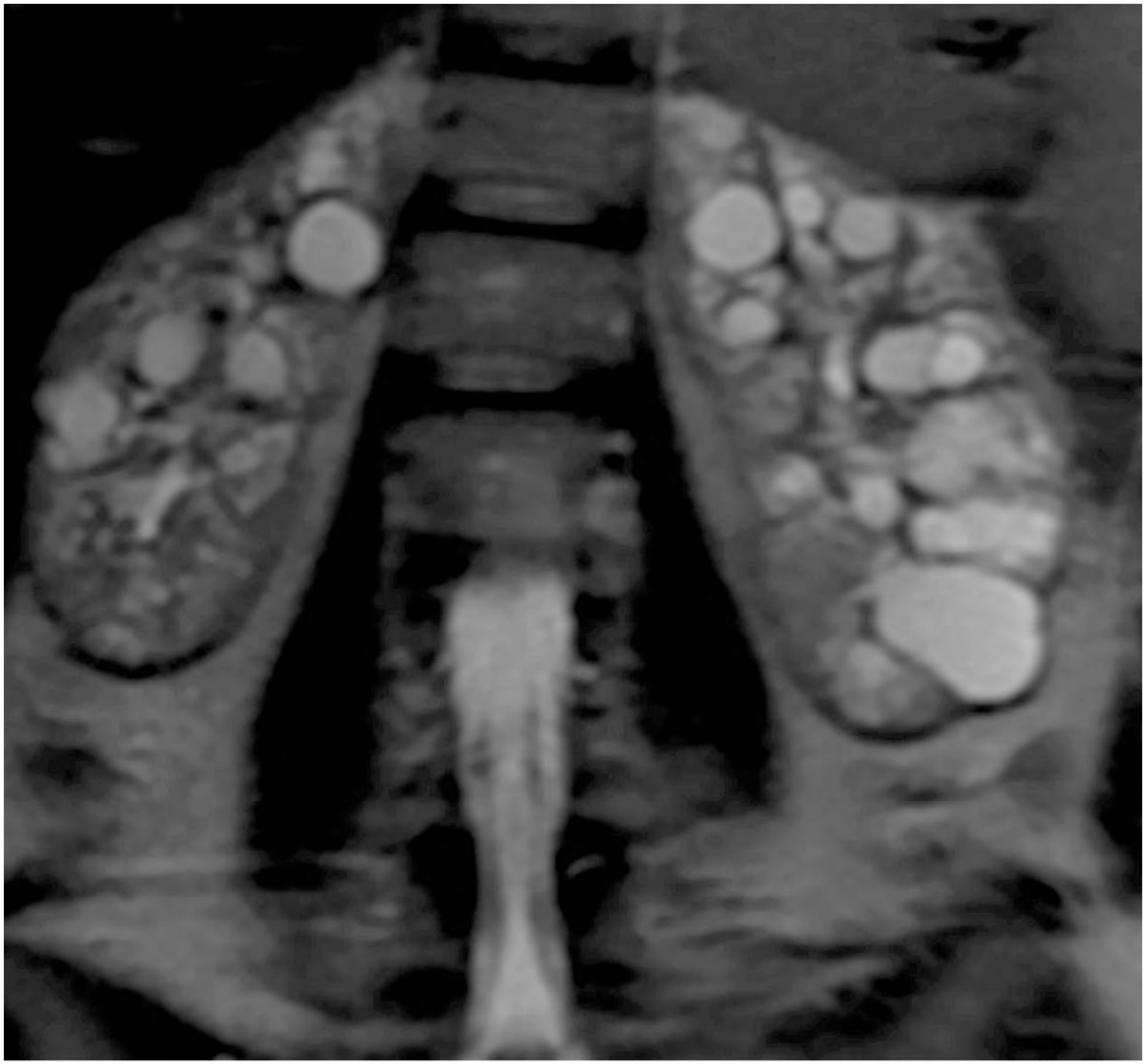

- Donna 42 anni
- NO Familiarità
- Ipertensa
- Classe Mayo 1B

Highly Variable Disease

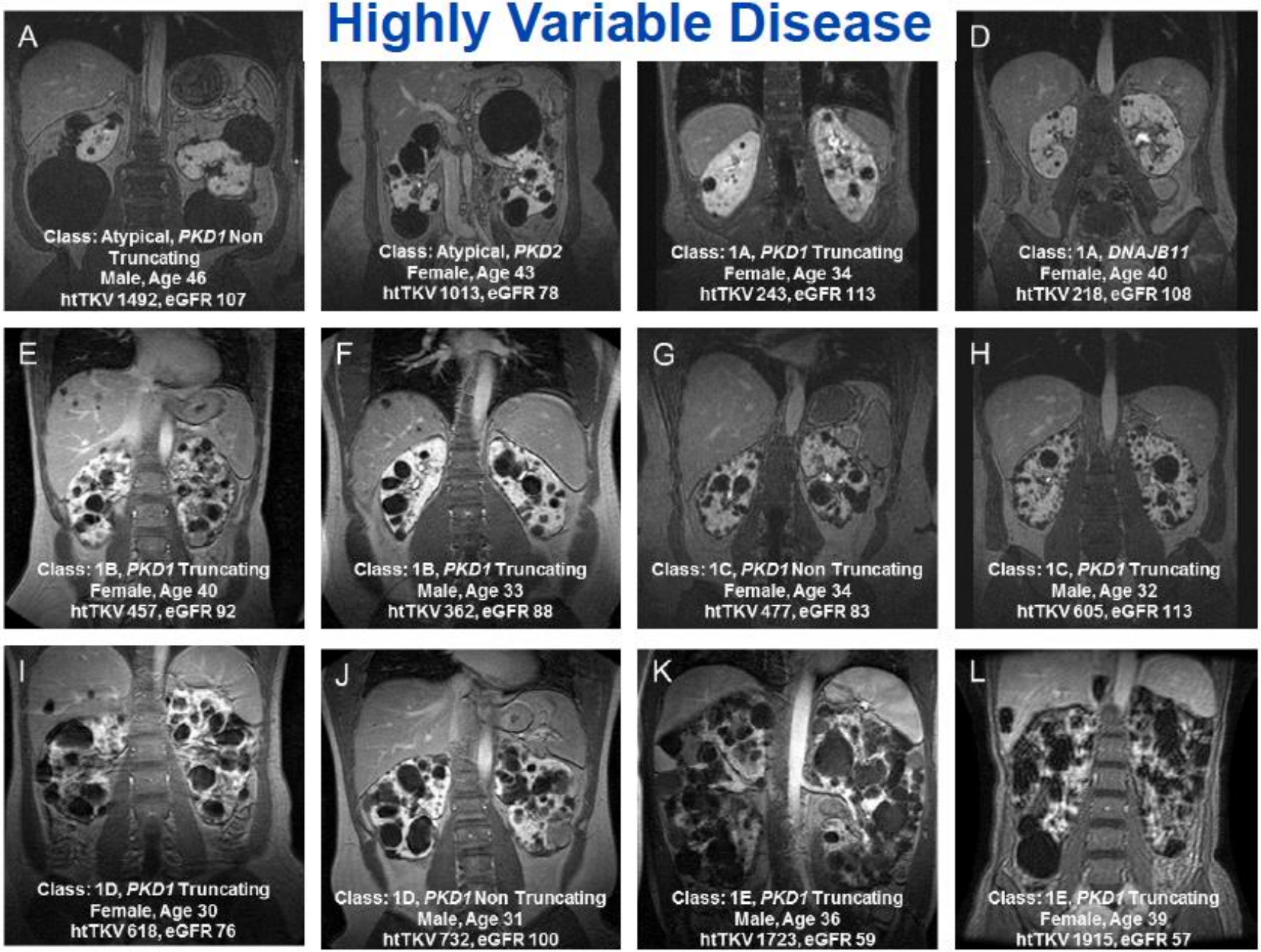

Chebib F *et al.* cJASN 2018

Policistosi Monolaterale

- Donna di 32 anni
- NO Familiarità
- NO Ipertensione
- No proteinuria

Basi molecolari alla base del mosaicismo

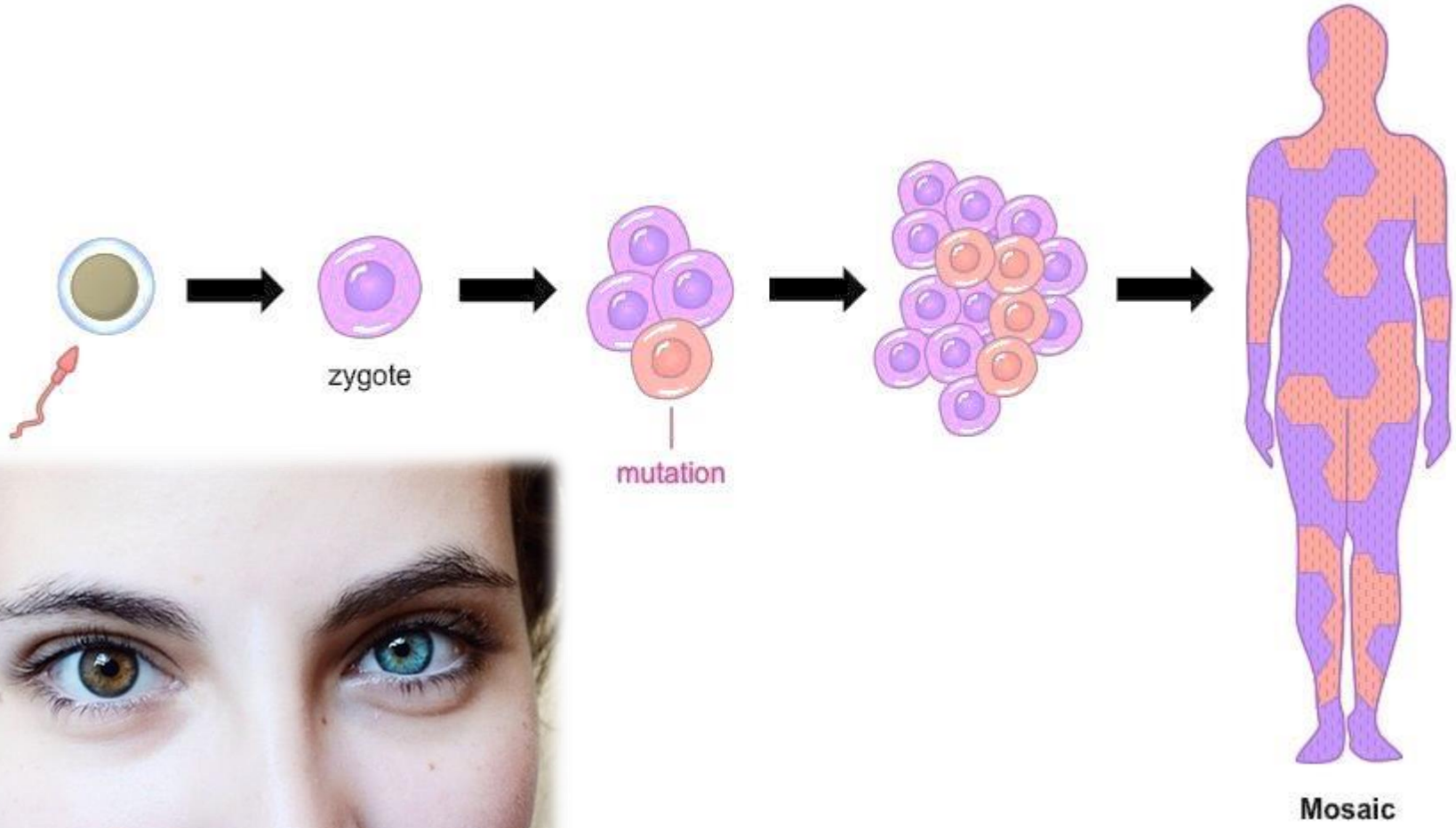

Policistosi tipo ADPKD monolaterale

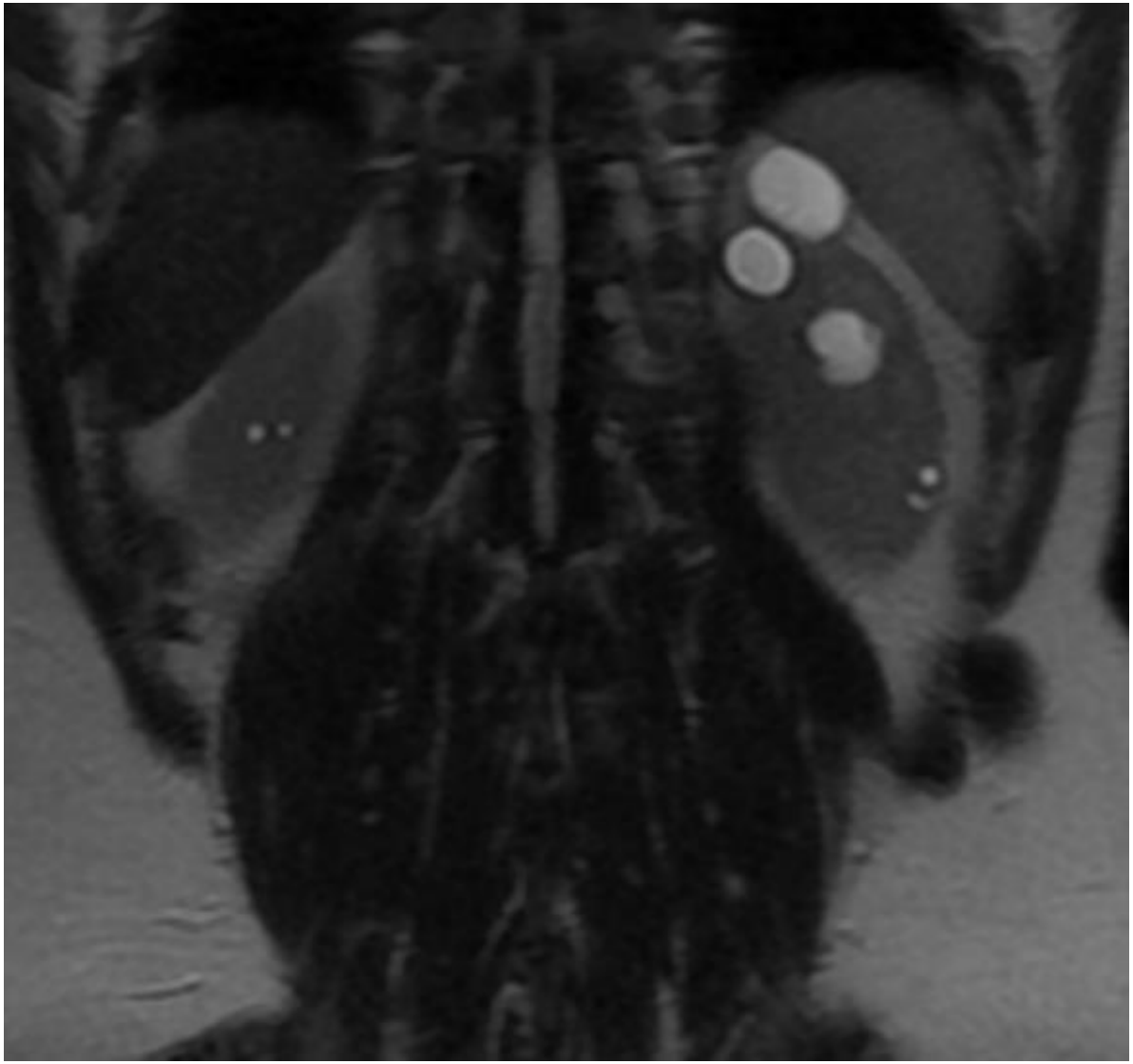

- Maschio di 42 anni
- + Familiarità
- NO Ipertensione
- NO proteinuria
- Gene test ongoing

Piccole Multiple Cisti non deformanti il profilo renale

- Donna di 32 anni
- NO Familiarità
- Ipertesa
- No proteinuria
- Angiomiofibromi perinasali
- Tuberi Subcorticali
- Mut TSC-2

Microcisti bilaterali diffuse e ESRD

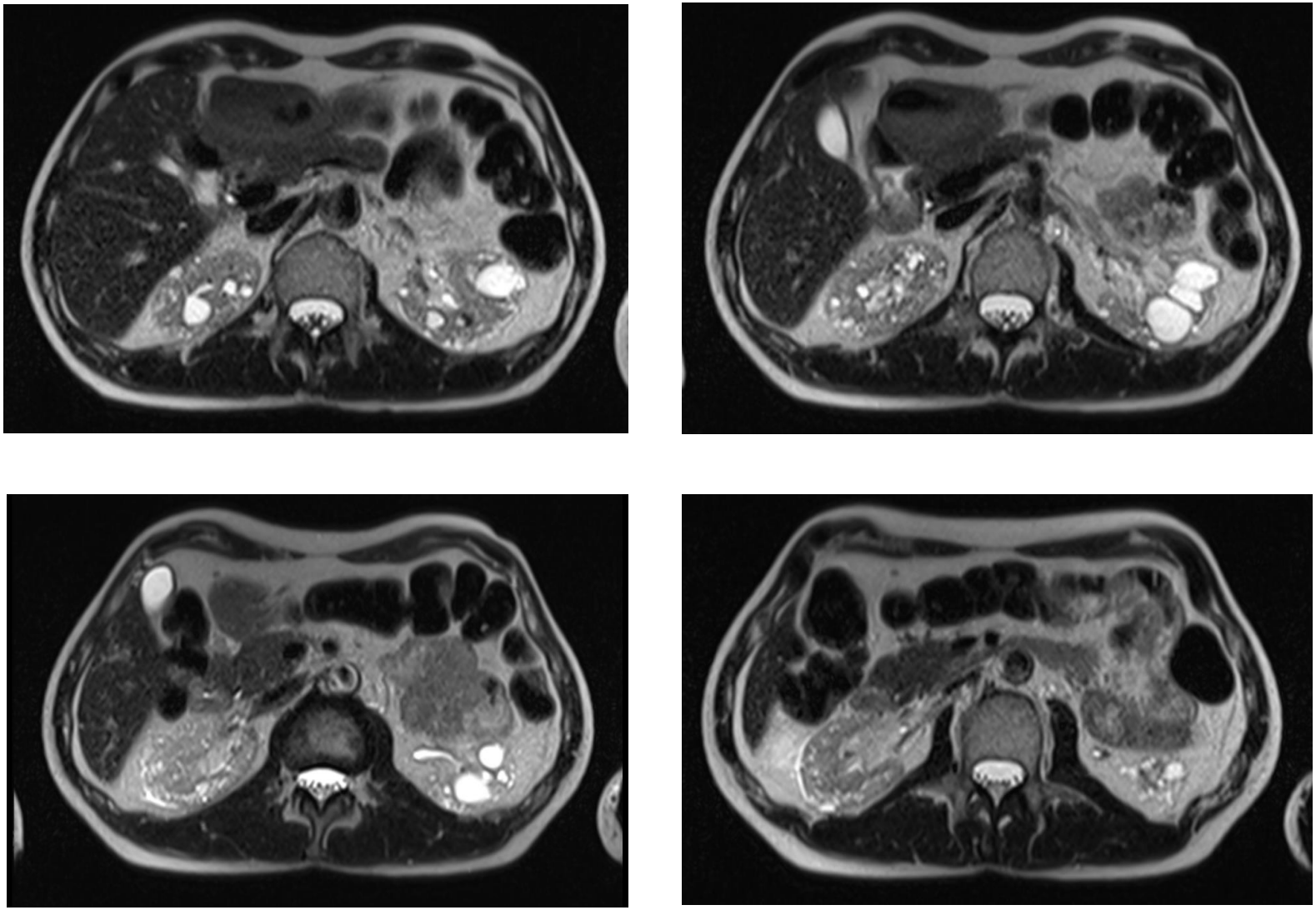

Conclusione

- Le recenti acquisizioni nell'ambito dell'ADPKD stanno cambiando l'approccio diagnostico/prognostico e terapeutico.

- L'integrazione tra imaging e genetica è al momento l'avanguardia per la classificazione della malattia.

Grazie per l'attenzione